



Pelvic post-traumatic asymmetry: assessment and sequenced treatment

Pedro Cano-Luís
Miguel Ángel Giráldez-Sánchez
Pablo Andrés-Cano

- The most common cause of post-traumatic pelvic asymmetry is, by far, initial nonoperative treatment.
- Open reduction and internal fixation of unstable pelvic fractures are recommended to avoid pelvic nonunion or subsequent structural deformities.
- The most common symptom is pelvic pain. Pelvic instability is another symptom, as well as persistent urogenital problems and neurological sequelae.
- Preoperative evaluation of these patients requires careful clinical and functional assessment, in addition to a complete radiological study.
- Surgical treatment of pelvic fracture nonunions is technically demanding and has potentially serious complications.
- We have developed a new classification that modifies and completes Mears and Velyvis's classification in which we highlight two types of post-traumatic sequelae with different clinical conditions and whose basic differentiating element is whether pelvic deformity is present or not. Based on this classification, we have established our strategy of surgical treatment.

Keywords: pelvic fracture sequelae; pelvic instability; pelvic nonunion; pelvic malunion

Cite this article: *EFORT Open Rev* 2018;3
DOI: 10.1302/2058-5241.3.170069.

Introduction

Complications of pelvic trauma are usually the result of an unstable fracture that is managed nonoperatively, or is treated inadequately.¹⁻³ Anatomical restoration of the pelvic ring has been correlated with better clinical results. Open reduction and internal fixation of unstable pelvic fractures are recommended to avoid nonunion or subsequent structural deformities.^{4,5}

The most frequent clinical manifestation in patients with pelvic fracture sequelae is pain in the posterior and anterior pelvic ring, although the latter is less frequent. There are other symptoms associated with pelvic deformity, such as leg-length discrepancy, aesthetic defects due to bony prominences, posture problems (sitting and standing imbalance) and sexual or urological disorders.^{1-3,6}

The surgical treatment of these complications presents a challenge for the orthopaedic surgeon due to the technical difficulty and high surgical risk involved.^{1-3,7-17} A thorough preoperative evaluation is necessary together with a complete radiological and tomographic study, which allows a therapeutic plan to be designed and then followed. The introduction of 3D printing systems can dramatically improve surgical planning. The patient must be informed of the surgical risks involved as well as the possibility of obtaining unsatisfactory results.

Aetio-pathogenesis

The most common cause of post-traumatic pelvic asymmetry is, by far, initial nonoperative treatment (bed rest, traction or pelvic slings).¹⁻³ Suitable surgical treatment is essential to prevent complications such as nonunion or secondary structural deformities.^{4,5} These are most often seen in inadequately treated Tile type C injuries,¹⁸ often a result of external fixation which is insufficient to stabilize the posterior lesion.¹⁹ Inadequately treated sacral fractures involving the articular pedicles of L5-S1 (Isler 2)²⁰ may lead to residual rotational instability of the spinal column.²¹ In Tile type B2 injuries caused by a lateral compression mechanism, internal rotation deformities may result if not treated properly.^{1,2,9,12} In type B1 injuries caused by an anteroposterior compression mechanism, residual anterior instability may occur if the initial injury is not adequately assessed or treated.²² Additionally, poor collaboration or lack of follow-up of these patients with pelvic injuries may contribute to the appearance of these complications. However, a small

percentage of patients will evolve towards nonunion despite correct initial treatment.^{1,2,11,16}

Clinical aspects

Sometimes the lumbosacral spine and hips compensate for pelvic deformities, allowing them to be well tolerated. Only patients who present with a full-blown clinical condition request corrective surgery for the sequelae.

The most commonly associated symptom is pelvic pain, mainly of the posterior pelvic ring,^{1,2,8,9,12} although pain in the anterior region of the pelvis is typical in patients with residual pelvic instability after a pelvic fracture due to anteroposterior compression.²² This pain may be due to the instability of the injured hemipelvis during load transfer, and in evolved cases posterior pain may appear due to osteoarthritic changes in the sacro-iliac joint.²³ It is important to differentiate true pelvic pain from mechanical low back pain secondary to a compensatory scoliotic curve of the lumbosacral spine, and from neuropathic pain that will not improve with surgical treatment.^{1,2,14}

Pelvic instability is another common symptom.^{1,2,9,12,14} The cranial displacement of the hemipelvis causes leg-length discrepancy and problems when sitting (sitting imbalance) due to asymmetry of the ischial tuberosities, as well as while standing (standing imbalance). Other functional disorders are secondary to diminished abductor muscle strength or to disorders in the orientation of the coxo-femoral joint. Additionally, symptoms derived from femoroacetabular impingement caused by an increase in femoral anteversion may appear.⁹

Severe pelvic trauma can result in persistent urogenital problems due to damage to the pelvic floor, prolapse or neurological injury.^{3,6} The existence of structural alterations in rotation can cause symptoms due to space constraints. Urinary disorders may appear due to bladder irritation by displacement of the superior pubic ramus. Medial displacement of the ischial tuberosity can compress the vaginal wall and produce dyspareunia. Deformities of the true pelvis can lead to obstetric problems.²⁴ Injuries to the abdominal organs are less frequent.

Late neurological sequelae are due to lumbosacral plexus traction lesions in unstable fractures in the vertical plane or in transforaminal fractures of the sacral ala. The most frequent neurological injuries are to L4 and L5 roots, followed by the superior gluteal nerve.^{1,2}

Pelvic deformity causes important aesthetic defects such as bony prominence of the sacrum or coccyx due to cranial displacement of the injured hemipelvis. Sacrum deformity can be particularly severe in patients with bilateral displacement of both hemipelves, and this is more relevant in female patients and those with low BMI.^{1,2,9,12,14,16}

Preoperative evaluation

Preoperative evaluation of these patients requires careful clinical and functional study, in addition to a complete radiological study.^{7,17} In the clinical evaluation, pelvic pain should be assessed according to its severity and location, as well as its correlation with pelvic instability or neurological injuries. Sacro-iliac pain is the most common symptom and does not usually respond to standard pain killers. It can be assessed by an intra-articular injection of lidocaine under fluoroscopy or CT scan control.¹² Static postural studies, spine studies and complete neurological studies must also be included. It is essential to request five radiological projections for the static radiological study, i.e. anteroposterior, alar, obturator, inlet and outlet views.

The completion of the instability analysis is helped considerably by taking anteroposterior views of the pelvis with the patient standing on both legs in neutral and in external rotation and single leg stance on the left and right leg. In the operating theatre, a manual stress test (traction and rotational compression) must be performed under image intensifier control (Fig. 1).¹²

The CT scan helps to better define the lesions and to detect fracture nonunion. The 3D CT scan is very useful to completely define the deformity and to develop a therapeutic plan.^{3,15-17} The radiological study allows the deformity to be classified and to compare it with a normal anatomical pattern. It allows the linear, rotational and vertical displacements of the deformity to be recorded. In unilateral cases, it allows the normal anatomical landmarks of the healthy hemipelvis to be compared with the contralateral pathological one. In the case of a bilateral pelvic deformity, a comparison should be made with normal anatomy. Leg-length discrepancy is determined by measuring the cranial displacement of the acetabular roof in the anteroposterior pelvic projection. Comparative measurement of the two sides is made along a perpendicular line to the midline of the sacrum.⁹

Recently we have been using real-size 3D printing to accurately define the lesion, to plan the release and osteotomy areas and to define the implant including its length, plate pre-shaping and placement areas. This also allows us to calculate the rotational corrections and the size of the autografts required for the same and for the nonunion zones (Fig. 2). To complete the diagnosis, urological and pelvic floor studies are essential.^{3,6}

Classification

To our knowledge, there is no published paper that establishes a classification which stratifies pelvis sequelae and aids in the treatment plan at the same time. Based on experience accumulated after treating more than 63 cases, we have developed a classification (Table 1) that modifies

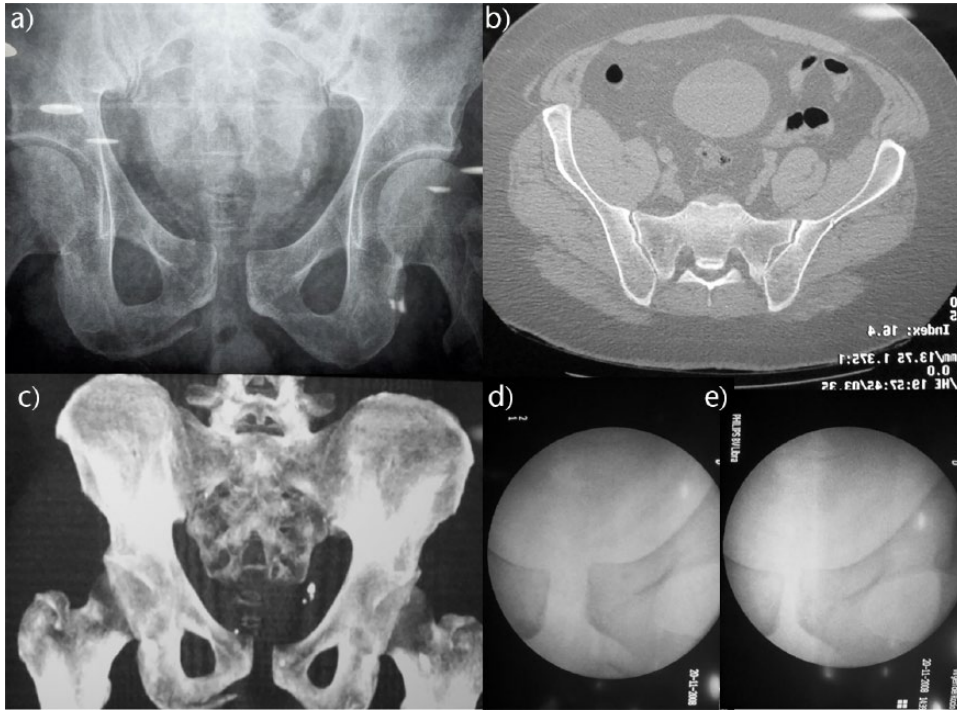


Fig. 1 Type I residual instability of anterior rotational predominance: a) preoperative pelvic anteroposterior radiograph; b) axial CT scan; c) 3D reconstruction; d) and e) dynamic stability test under fluoroscopy showing pelvic instability.

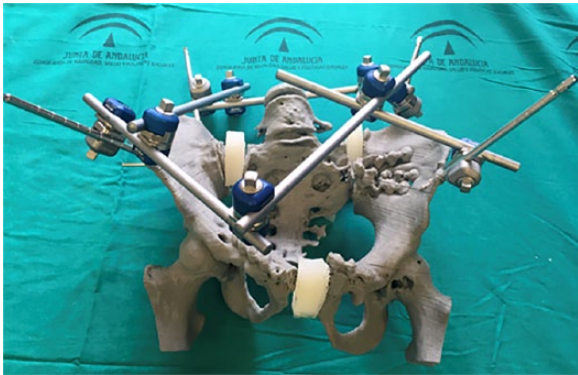


Fig. 2 3D printing model of a post-traumatic pelvic asymmetry used for preoperative planning. Note: size of the autografts required has been also planned.

and widens that of Mears and Velyvis,¹² in which we distinguish two types of post-traumatic sequelae with different clinical conditions and whose basic differentiating element is whether pelvic deformity is present or not.

Residual instabilities

Residual instabilities have no pelvic ring deformities. Among the causes are an inadequate initial assessment of the injury and failure to restore pelvic circumferential stability due to inadequate synthesis of the anterior frame. Apart from being post-traumatic, this type of instability can also be

observed after childbirth with a large foetus which produces true external rotation injuries with symphyseal disruption and ruptures of the pelvic floor ligaments.²²

We differentiate between three types according to whether the predominance of the injury is anterior (Type I), posterior (Type II) or anterior and posterior combined (Type III).

In Type I, the injury is anterior. It is due to injury from external rotation that was not correctly assessed. It is characterized by the presence of predominant anterior pain, with no leg-length discrepancy or postural alterations. To complete the diagnosis, we must perform an anteroposterior pelvis radiograph in monopodal stance and external rotation, as well as a dynamic stability test under fluoroscopy (Fig. 1).

In Type II, the injury is posterior. It is due to rotatory instabilities with degenerative changes in the sacro-iliac joint or vertical instabilities with nonunion of the sacrum and healing of the anterior component. A special type, not described in the literature, is the rotational instability of L5/S1 that occurs due to the nonunion of the articular pedicle L5/S1 in Isler 2 sacral fractures that are not properly treated (Fig. 3). It is characterized by the presence of posterior predominant pelvic and lumbar pain without leg-length discrepancy or postural alterations. To complete the diagnosis, we must perform dynamic lumbar spine radiographs and a CT scan with 3D reconstruction.

Table 1. Pelvic sequelae classification

Type	Deformity	Pain	Leg-length Discrepancy	Sitting	Stability test	Treatment
Residual instability	No					
Type I		Anterior	No	No	Yes	Anterior arthrodesis
Type II		Posterior	No	No	Yes	Posterior osteosynthesis/arthrodesis
Type III		Anterior and posterior	No	No	Yes	Sequential 2/3-stage 1 operation
Complex instability	Yes					
Type IA		Anterior and posterior	Yes < 3cm	Yes/No	No	Sequential 2-stage 2 operations
Type IB		Anterior and posterior	Yes > 3cm	Yes	No	Sequential 2-stage 2 operations
Type IIA		Anterior and posterior	Yes < 3cm	Yes	Yes	Sequential 2-stage 1 operation
Type IIB		Anterior and posterior	Yes > 3cm	Yes	Yes	Sequential 2-stage 2 operations

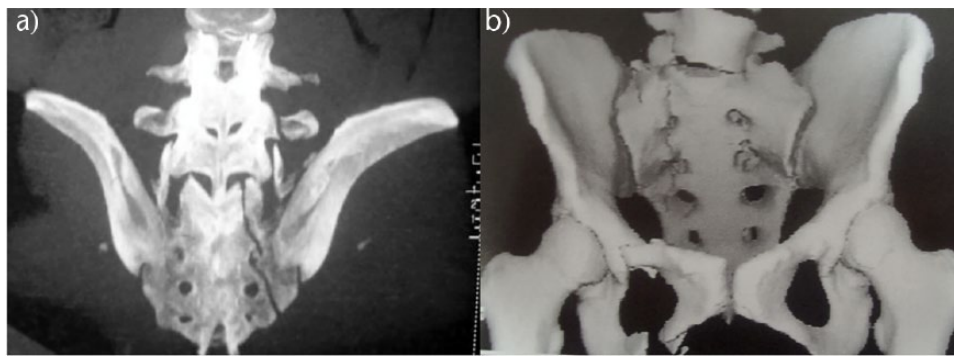

Fig. 3 Type II residual instability of vertical predominance: a) and b) rotational instability of the spine through a unilateral injury of the L5-S1 pedicle.

In Type III, the anterior and posterior injuries are associated. It is due to old rotatory instabilities with anterior instability of the symphysis and post-traumatic degenerative changes of the sacro-iliac joint or vertical instability with nonunion of the sacrum without anterior healing. It is characterized by anterior and posterior pain, instability during walking and no leg-length discrepancy or postural alterations. For diagnosis, we need dynamic radiographs in monopodal stance and a CT scan with 3D reconstruction.

Complex instabilities

Complex instabilities are always associated with pelvic ring deformities. They are due to rotational or vertical instabilities that were not initially treated, treated improperly or had an unsatisfactory course.

We distinguish between two varieties depending on whether the pelvic deformity is stabilized (Type I malunion) or if the deformity is unstable (Type II nonunion). Each type is subdivided into A or B depending on whether the leg-length discrepancy is greater or less than 3 cm (Fig. 4).

Patients present clinically with anterior and posterior pelvic pain, low back pain, claudication and gait instability, leg-length discrepancy, sitting-imbalance and

neurological and genito-urinary alterations. The correct diagnosis requires a complete clinical-neurological examination and imaging studies with dynamic radiographs, CT scan with 3D reconstruction, MRI and electrophysiological tests.

Surgical treatment

Indications and objectives

The main surgical indication for these patients is pain associated with pelvic instability.^{1,2} Other indications are the symptomatic deformities that jeopardize walking (i.e. leg-length discrepancy), sitting-imbalance and urogenital or obstetric problems due to compression of the bladder or vaginal wall.⁷⁻¹⁷

The main goal of surgery is restoration of the normal symmetrical anatomy of the pelvic ring. The aim is to improve the quality of life of these patients by relieving pain, correcting leg-length discrepancy and sitting-imbalance and resolving uro-sexual problems directly related to pelvic deformity.^{3,7-16} It is aggressive and invasive surgery that has a high rate of complications, including neurovascular risks.^{1-3,7-17}

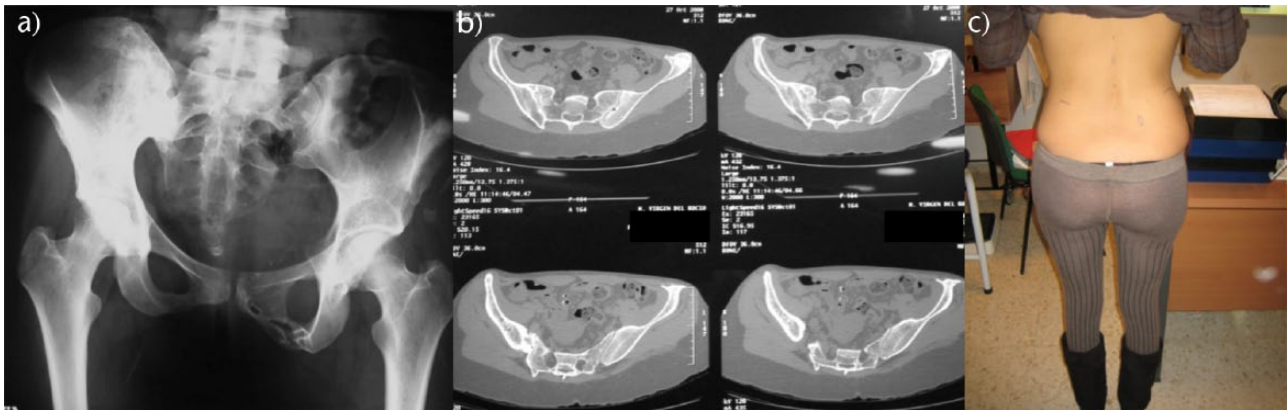


Fig. 4 Type IB complex instability: a) preoperative radiograph; b) preoperative CT scan (axial views); c) leg-length discrepancy > 3 cm.

It is of great importance that the final decision is taken by the patient in accordance with realistic objectives and a knowledge of the risk of complications. In cases of nonunion, patients should expect their symptoms to be resolved or to improve with surgical intervention.^{9,12,13} In cases where deformity prevails, the patient will expect the correction of leg-length discrepancy, problems when sitting, dyspareunia or aesthetic problems.⁷⁻¹⁷ The patient should be informed that major deformities can be corrected, but that the final result may not be completely perfect. Also, we must inform the patient that pelvic pain not associated with nonunion or instability is not corrected with this type of surgery.

These patients must be treated surgically in tertiary referral centres that have the correct infrastructure and technical equipment, and by qualified and well-trained professionals who are well-versed in the different routes, approaches and techniques of osteosynthesis of the pelvic ring.

Surgical techniques

Residual instabilities

In Type I residual instability of anterior rotational predominance (Fig. 1), ideal treatment is arthrodesis of the pubic symphysis, in a single procedure, using a Pfannenstiel approach. We use reconstruction plates and 3.5 mm screws and an autologous bone graft obtained from the anterior or posterior iliac crest. Sometimes it is necessary to place, temporarily, an iliosacral screw to support the anterior arthrodesis.

In Type II residual instability with posterior rotational predominance when the sacro-iliac joint is affected, we perform an anterior arthrodesis of the joint through the superior window of the ilio-inguinal approach, and fixation with two methods of osteosynthesis: usually two 3.5 mm plates and ilio-sacral screws.

In Type II residual instability of vertical predominance with associated rotational instability of the spine through

a unilateral injury of the L5-S1 pedicle (Fig. 3), the treatment of choice is the L5-S1 posterolateral arthrodesis using a posterior approach, by means of spinopelvic instrumentation and a cancellous cortical autograft.

In Type II residual instability of vertical predominance which is associated with a nonunion of the sacrum, with the patient in a prone position using a posterior approach, we perform curettage of the nonunion and osteosynthesis with ilio-sacral screws plus tension band and autograft support.

In Type III combined residual instability with rotational predominance and anterior and posterior component pain (posterior pain and degenerative disorders in the sacro-iliac joint), it is necessary to perform the anterior arthrodesis at the symphysis level first and at the sacro-iliac joint level after that. If possible, they are both performed in a single surgery, using a Pfannenstiel approach, and the superior window of the ilio-inguinal approach. It is recommended to use plates and 3.5 mm screws in the symphysis, and for the posterior ring we always combine two different types of osteosynthesis: two 3.5 mm plates on the anterior sacro-iliac joint and one or two ilio-sacral screws.

Type III combined residual instability of vertical predominance due to nonunion of the sacrum without deformity or with minimal deformity is treated with a single surgical procedure but in a sequential way. In cases with no displacement and which are relatively recent, and in cases which have had previous surgery and where easy removal of implants is presumed, we prefer the two-stage sequence.¹³ First, in the prone position, opening and curettage of the nonunion and application of the autograft and fixation is performed, always with two methods of osteosynthesis. Then, in the supine position, liberation and curettage of the anterior injury plus osteosynthesis/arthrodesis and application of an autograft is performed. In our opinion, the fixation of the anterior component is essential.

In extremely old cases with broken osteosynthesis hardware, we prefer a three-stage liberation sequence.^{9,12,14}

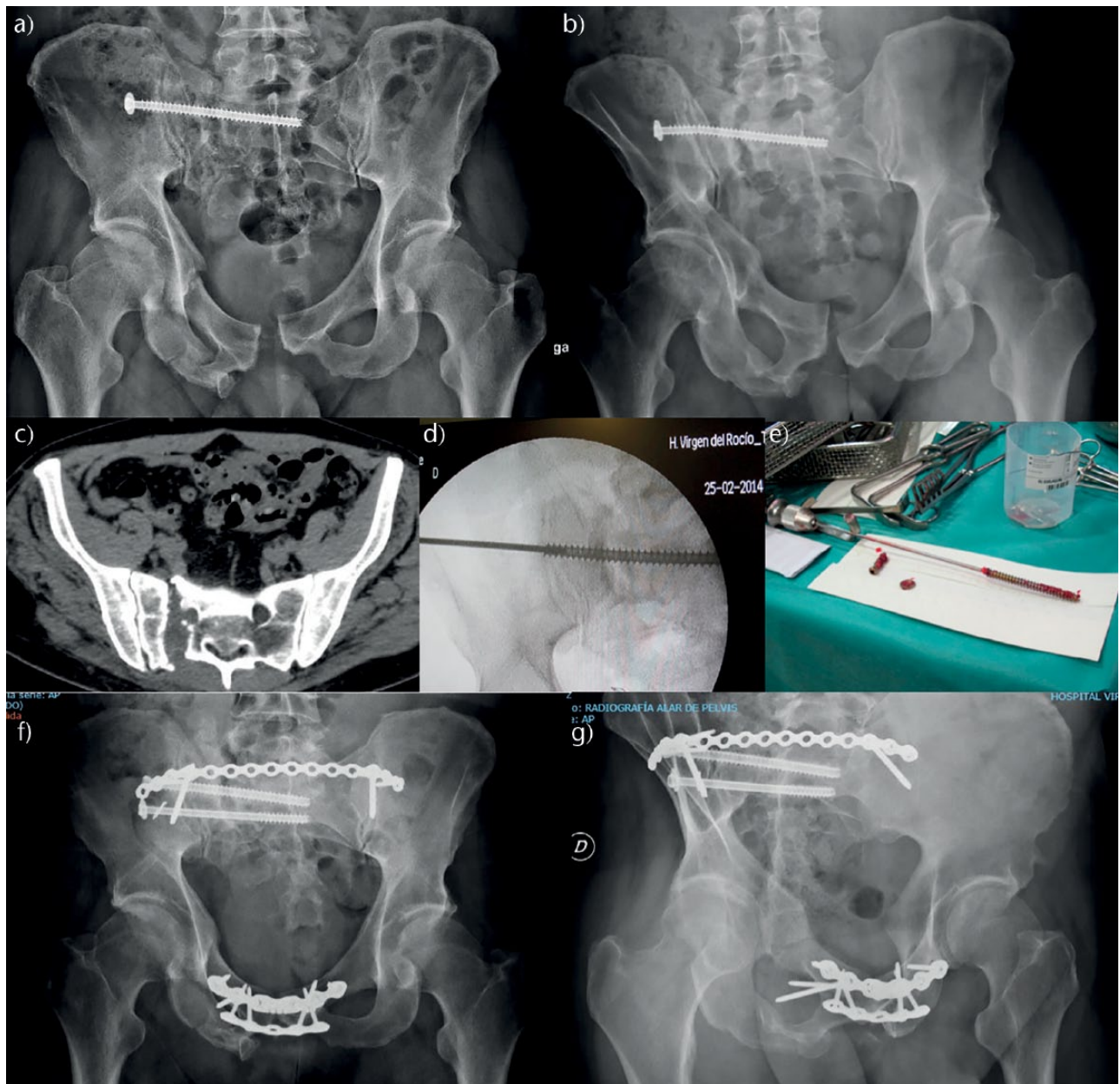


Fig. 5 Type III combined residual instability of vertical predominance: a) and b) preoperative radiograph; c) preoperative CT scan (axial view) showing sacral fracture nonunion; d) and e) technique to retrieve the broken sacro-iliac screw; f) and g) radiograph control after nine years of follow-up.

First is anterior liberation in the supine position. Second is posterior liberation in the prone position with mobilization of the nonunion, application of the autologous graft and posterior osteosynthesis (combined ilio-sacral screws and a tension band or, in rare instances, spinopelvic instrumentation), always combining the two systems. Third, again in the supine position, osteosynthesis or anterior arthrodesis are performed (Fig. 5).

Clinical results are similar with both procedures. The advantage of the two-stage sequence is less blood loss and lower infection rates (Table 2).^{1,2,9,12,14}

Complex instabilities

Complex deformities always require staged surgery. In cases with < 3 cm of leg-length discrepancy, we perform a sequential treatment in two or three stages, applying the

Table 2. Surgical techniques

Type	Anterior osteosynthesis/arthrodesis	Posterior osteosynthesis/arthrodesis	Sequential 2-stage 1 operation	Sequential 3-stage 1 operation	Sequential 2-stage 2 operations
Residual instability					
Type I	X				
Type II		X			
Type III	X	X	X	X	
Complex instability					
Type IA	X	X		X	
Type IB					X
Type IIA	X	X		X	
Type IIB					X

same principles as in Type III residual instability. We recommend performing this sequence in separate operations if the leg-length discrepancy is > 3 cm.

Type IA complex instability with leg-length discrepancy < 3 cm requires sequential treatment, usually in three stages in a single operation:

1. Stage 1. In the supine position, anterior liberation through the symphysis or by osteotomies of the ilio-pubic or ischio-pubic branch is carried out, depending on the type of injury. The liberation of the posterior component always requires osteotomies through the ilium or sacro-iliac joint, depending on the type of posterior injury. Our advice is that the osteotomy is performed with the Gigli saw and introduced through the sciatic notch using the superior window of the ilio-inguinal pathway. We rarely perform osteotomies through the sacrum.
2. Stage 2. In the prone position, a posterior approach is made sectioning the sacrospinous, sacrotuberous and iliolumbar ligaments. It is extremely important to remove all bony callus and fibrous tissue to achieve a correct reduction. Occasionally, osteophytes are observed that run from the transverse processes of the fourth and fifth lumbar vertebrae to the iliac crest with rigid scoliotic deviation of the lumbar spine.⁸ The control of the leg-length discrepancy can be performed with a system of spinopelvic fixation and progressive distraction, bearing in mind that we must control any displacements in internal rotation and flexion of the hemipelvis controlled by intraoperative fluoroscopy.¹⁴ Schanz screws can also be used in the ilium to handle and mobilize the hemipelvis. It is imperative that the healthy hemipelvis is fixed to the operating table by means of equipment that allows the correction of cranial and rotational displacements. One 6 mm pin is placed in the subtrochanteric region and another in the posterosuperior iliac spine of the healthy hemipelvis; these are then attached to the table. This can be applied with the patient in the

supine or prone position.²⁵ Once the deformity is reduced, osteosynthesis of the posterior ring is performed, combining two different systems according to the injury pattern: spinopelvic instrumentation, tension band, iliosacral screws or 3.5 mm reconstruction plates.

3. Stage 3. Once again in the supine position, osteosynthesis of the anterior component is performed with 3.5 mm reconstruction plates. The use of a cancellous-cortical autograft is needed for the anterior and posterior ring. In cases where there is a very important rotational component of the anterior frame, consideration should be given to possible urogenital extrophies that must be corrected during surgery.³ Intraoperative monitoring of somatosensory evoked potentials is paramount to avoid iatrogenic injury to the lumbosacral plexus during the reduction manoeuvres.^{8,11}

In the case of Type IA complex instability in internal rotation with leg-length discrepancy < 3 cm, the trans-iliac osteotomy associated with the application of the autograft may partially correct deformity and leg-length discrepancy.¹⁷ In the case of Type IB complex instability with leg length discrepancy > 3 cm (Fig. 6), we perform a three-stage sequential treatment with two different surgeries:

1. Stage 1. Sequential liberation surgery: anterior and posterior liberation, in the same manner as the cases with leg-length discrepancy < 3 cm.
2. Stage 2. Correction of the deformity: for reduction of the deformity we suggest doing it progressively, using transcondylar skeletal traction with progressive increase of weight over 7–10 days until descent of the hemipelvis is obtained. It should be applied with the knee in extension and with daily neurological and vascular clinical examinations.¹⁴ The progressive increase of weight can achieve important pelvic lowering in a slow manner, avoiding aggressive manoeuvres that could cause neurovascular injuries. Serial radiological controls should be

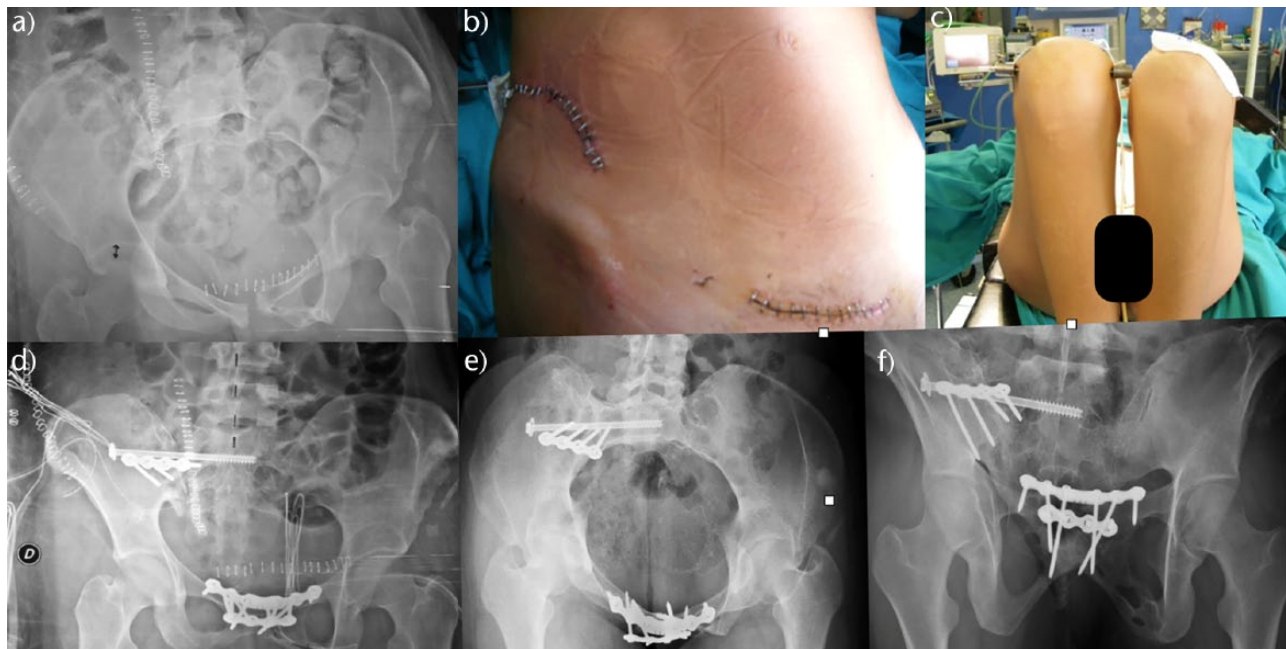


Fig. 6 Type IB complex instability with leg-length discrepancy > 3 cm postoperative (case of Fig. 3): a) radiograph after first and second stage (sequential liberation surgery and correction of the deformity); b) clinical photograph showing pelvic descent; c) leg-length discrepancy restoration; d) postoperative radiograph; e) and f) inlet and outlet radiograph views after nine years of follow-up.

performed to verify the degree of mobilization obtained. When a widening of the coxo-femoral joint is observed, traction should be applied to the supra-acetabular region of the iliac bone.

3. Stage 3. Osteosynthesis/arthrodesis surgery: once the descent of the hemipelvis has been achieved, fixation should be applied. From our point of view the key problem in achieving a perfect reduction is the control of the rotation, flexion and extension of the hemipelvis. In order to do this, we currently use real-size, 3D-printed models to calculate these displacements and to accurately restore the bone defect areas with measured-to-fit autografts (Fig. 2). It is imperative that the healthy hemipelvis is secured to the operating table.²⁵ We always perform the fixation of the posterior component with two fixation systems and the insertion of the autograft which is measured to fit using 3D printing. Next, the fixation of the anterior component is performed. When significant destruction of the previous frame exists, a long bridge-plate from the iliac fossa on one side to the other, bridging the defects, is useful. After that the autograft is added. It is also important to perform the surgery with intraoperative monitoring.^{8,11}

For Type II complex instability with associated deformity and nonunion, the treatment is the same as in Type I complex instability except that osteotomies are not

needed. In cases with leg-length discrepancy of < 3 cm (Type IIA) we usually perform one surgery, in three sequential stages: liberation of the posterior and anterior dislocation/nonunion and definitive osteosynthesis.

If the leg-length discrepancy is > 3 cm (Type IIB) the first operation is sequential posterior and anterior liberation. Skeletal traction is applied until pelvic balance is reached on the ward. The second operation is posterior and anterior osteosynthesis with the same principles as in Type I (Figs 7 and 8).

In patients with persistent sitting-imbalance despite corrective surgery, palliative resection of the sciatic tuberosity on the healthy side is indicated to correct this deformity.^{9,12} Patients with high comorbidity may undergo palliative procedures such as resection of bony prominences or femoral shortening/lengthening to eliminate the high risk of complications from pelvic reconstructive surgery.¹²

Follow-up

Post-surgical imaging controls should include anteroposterior, inlet and outlet radiograph views, and a CT scan to assess the degree of correction of the pelvic deformity. An anatomical correction is considered to be present if it appears in the three radiological projections. A correction is considered satisfactory when there is a residual deformity of < 1 cm vertical or posterior, or < 15° rotational deformity in any plane. The reduction will not be considered

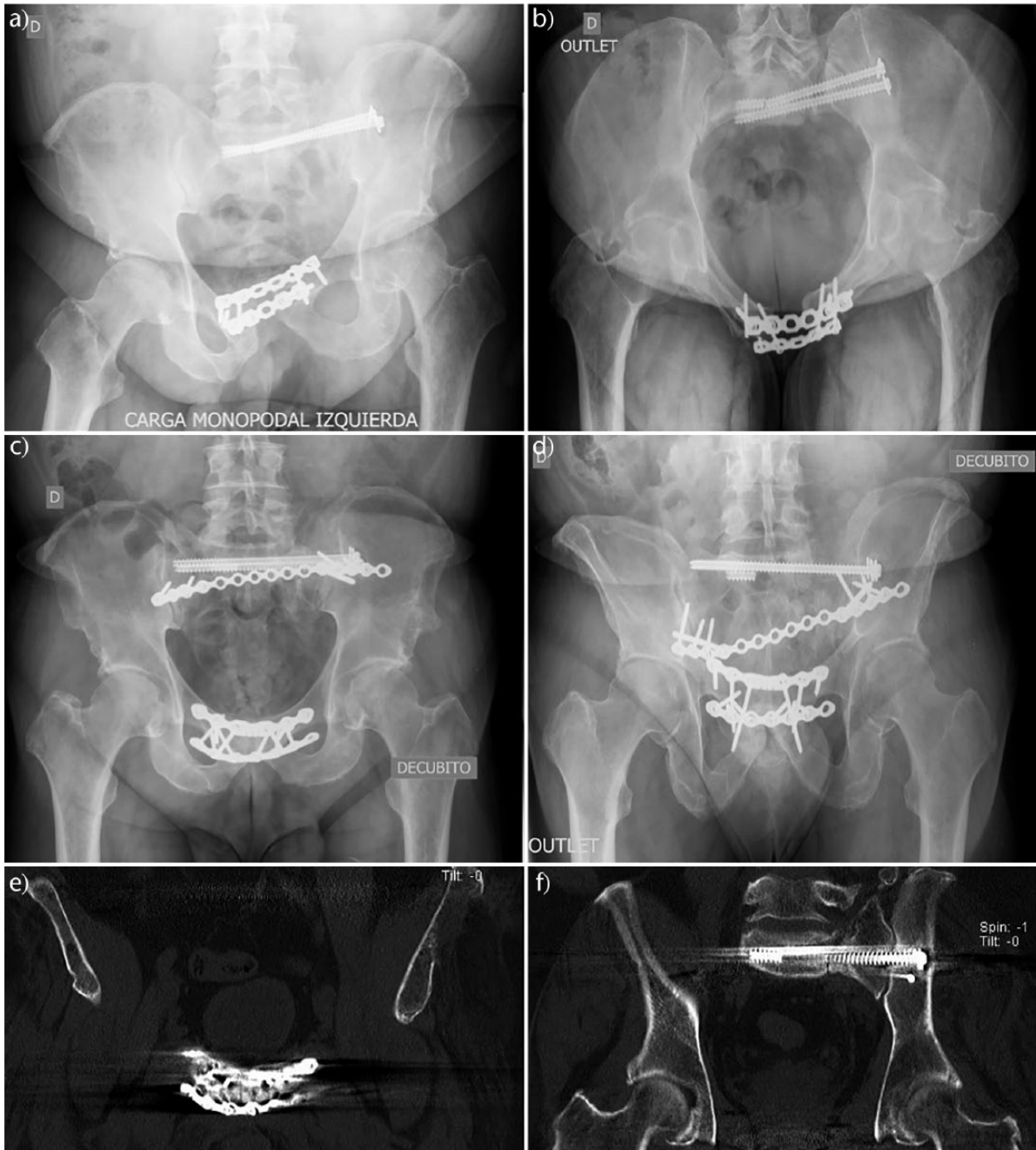


Fig. 7 Type II complex instability with associated deformity and nonunion: a) and b) preoperative radiograph; c) and d) postoperative radiograph (sequential liberation surgery, correction of the deformity, posterior arthrodesis and anterior arthrodesis); e) and f) coronal CT scan.

satisfactory if the resulting deformity is > 1 cm or the rotational deformity is $> 15^\circ$.^{1,2,9,12,14}

Patient collaboration is essential in the postoperative period. It is important to achieve adequate stability for immediate mobilization, with no weight-bearing on the limb for three months.^{9,11,12}

Although most patients benefit from these procedures, the results are not usually as good as the results of

acutely-treated pelvic ring fractures with reduction and internal fixation.^{1,2}

Post-surgical assessment must address three fundamental factors: pain, physical function and social reintegration. Pain should be assessed according to its intensity, duration and analgesic requirements after surgery. The physical assessment must include the distance that can be travelled without the need to stop or the requirement of

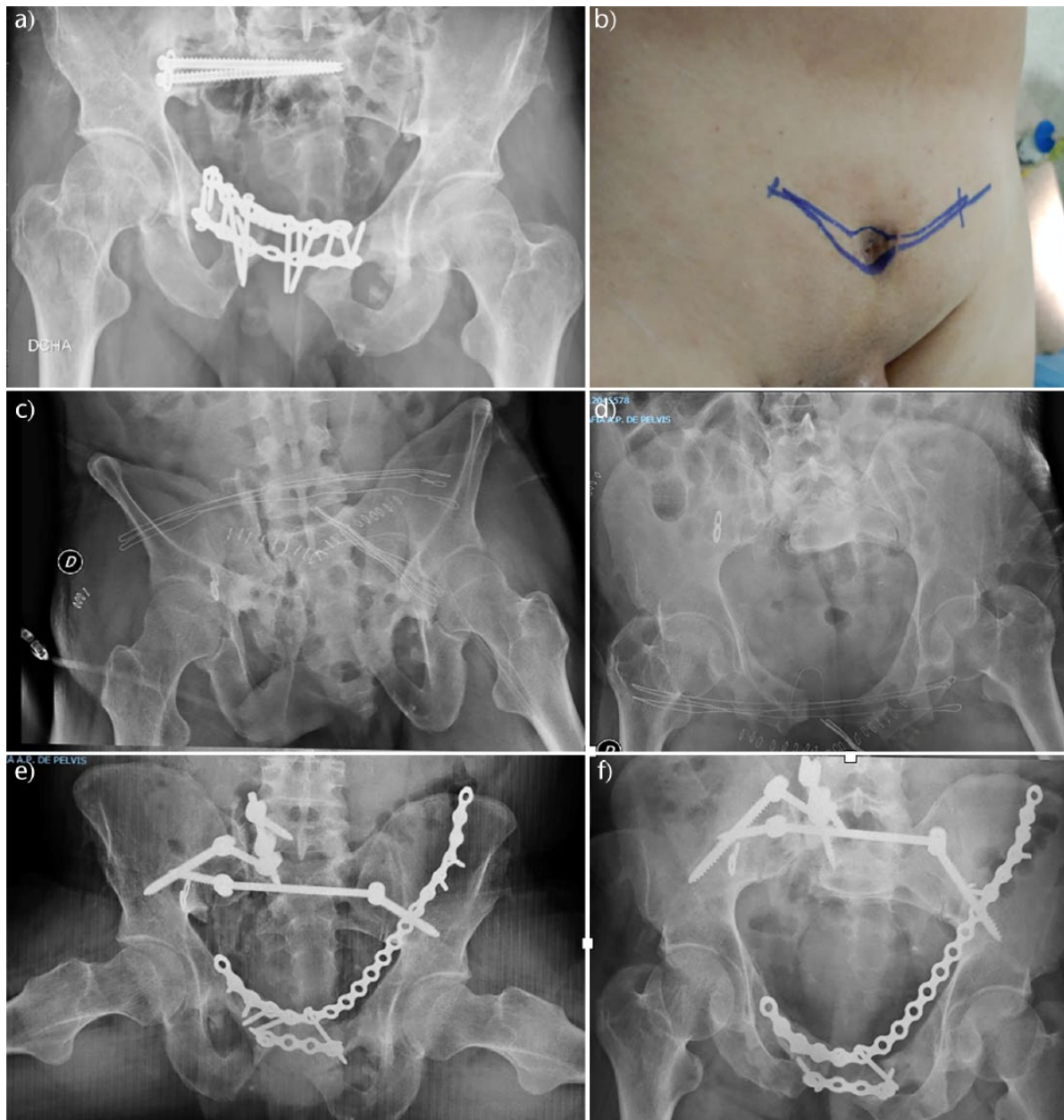


Fig. 8 Type II complex instability with associated deformity and septic nonunion: a) preoperative radiograph; b) clinical photography showing fistula over previous Pfannenstiel approach; c) and d) postoperative radiograph after sequential liberation surgery and correction of the deformity; e) and f) radiograph control after four years of follow-up.

support. Social reintegration must value the accomplishment of daily tasks, return to the workplace and the development of activities within the patient's own community. Thus, a very satisfied patient is one who has no pain, or intermittent pain, one who does not use painkillers, who walks independently and who has reintroduced normal tasks into his/her daily life. A dissatisfied patient is one who requires daily analgesics for pain control, who requires assistance to walk and who faces important limitations in normal everyday activities.^{1,2,12}

Complications

Reconstruction of pelvic fracture sequelae is complex, it requires long surgical time and it presents a higher rate of complications than acute surgical treatment.^{1,2}

There is a risk of injury to vascular and nerve structures, especially the superior gluteal vessels and the L5 and S1 nerve roots.^{9,12,14} Intra-pelvic organs, usually the bladder, can be injured. There is an increased risk of infection of surgical wounds, especially posterior ones due to their

proximity to the anal sphincter. Failure of the osteosynthesis material is more frequent. In cases where iliac spine distraction is used, an axial deviation of the spine may occur.¹⁴

Conclusions

The main cause of nonunion and pelvic deformity following pelvic fracture is the inadequate initial treatment of the fracture. The anatomical reconstruction of a pelvic injury prevents this. To reduce the number of complications, pelvic fractures and their sequelae should be treated by expert surgeons, and patients should be referred to reference centres for treatment.

Pain is the main symptom of nonunion and pelvic deformities. This is the main indication for surgery, but it is essential to define it as authentic pelvic pain for the surgical treatment to be effective. Associated deformities can seriously interrupt a patient's everyday life, and they are another frequent cause of surgical demand.

A thorough clinical and radiological study of the patient is essential in order to develop an effective therapeutic plan.

Despite the complexity of the pelvic sequelae, it is possible to perform a simple classification that allows the surgeon to standardize treatments.

The surgical approaches, reduction manoeuvres and fixing techniques that we intend to use must be planned in advance. This is where the use of 3D printing at real size is very helpful.

It is our duty to inform the patient of the importance of the surgery to which he/she is going to submit, as well as the possible risks and complications. In turn, we must inform the patient that the results may not always be totally satisfactory.

AUTHOR INFORMATION

Orthopaedic Surgery and Traumatology Department, Hospital Universitario Virgen del Rocío, Spain.

Correspondence should be sent to: P. Cano-Luís, Orthopaedic Surgery and Traumatology Department, Hospital Universitario Virgen del Rocío, Av. Manuel Siurot s/n, 41013 Sevilla, Spain.
Email: pedrocanoluis@yahoo.es

ICMJE CONFLICT OF INTEREST STATEMENT

None declared.

FUNDING STATEMENT

No benefits in any form have been received or will be received from a commercial party related directly or indirectly to the subject of this article.

LICENCE

© 2018 The author(s)

This article is distributed under the terms of the Creative Commons Attribution-Non Commercial 4.0 International (CC BY-NC 4.0) licence (<https://creativecommons.org/licenses/by-nc/4.0/>) which permits non-commercial use, reproduction and distribution of the work without further permission provided the original work is attributed.

REFERENCES

- Kanakaris NK, Angoules AG, Nikolaou VS, Kontakis G, Giannoudis PV.** Treatment and outcomes of pelvic malunions and nonunions: a systematic review. *Clin Orthop Relat Res* 2009;467:2112-2124.
- Tripathy SK, Goyal T, Sen RK.** Nonunions and malunions of the pelvis. *Eur J Trauma Emerg Surg* 2015;41:335-342.
- Fang C, Alabdulrahman H, Pfeifer R, Tarkin IS, Pape HC.** Late reconstruction of severe open-book deformities of the pelvis - tips and tricks. *Int Orthop* 2017;41:1777-1784.
- Papakostidis C, Kanakaris NK, Kontakis G, Giannoudis PV.** Pelvic ring disruptions: treatment modalities and analysis of outcomes. *Int Orthop* 2009;33:329-338.
- Dienstknecht T, Pfeifer R, Horst K, et al.** The long-term clinical outcome after pelvic ring injuries. *Bone Joint J* 2013;95-B:548-553.
- Ter-Grigorian AA, Kasyan GR, Pushkar DY.** Urogenital disorders after pelvic ring injuries. *Cent European J Urol* 2013;66:352-356.
- De Boeck H, Yde P, Opdecam P.** Non-union of a sacral fracture treated by bone graft and internal fixation. *Injury* 1995;26:65-66.
- Gautier E, Rommens PM, Matta JM.** Late reconstruction after pelvic ring injuries. *Injury* 1996;27(suppl 2):B39-B46.
- Matta JM, Dickson KF, Markovich GD.** Surgical treatment of pelvic nonunions and malunions. *Clin Orthop Relat Res* 1996;329:199-206.
- Frigon VA, Dickson KF.** Open reduction internal fixation of a pelvic malunion through an anterior approach. *J Orthop Trauma* 2001;15:519-524.
- Van den Bosch E, Van der Kleyn R, Van Zwiene M, et al.** Nonunion of unstable fractures of the pelvis. *Eur J Trauma* 2002;28:100-103.
- Mears DC, Velyvis J.** Surgical reconstruction of late pelvic post-traumatic nonunion and malalignment. *J Bone Joint Surg [Br]* 2003;85-B:21-30.
- Rousseau MA, Laude F, Lazennec JY, Saillant G, Catonné Y.** Two-stage surgical procedure for treating pelvic malunions. *Int Orthop* 2006;30:338-341.
- Oransky M, Tortora M.** Nonunions and malunions after pelvic fractures: why they occur and what can be done? *Injury* 2007;38:489-496.
- Lee SY, Niikura T, Sakai Y, et al.** Sacral fracture nonunion treated by bone grafting through a posterior approach. *Case Rep Orthop* 2013;2013:932521.
- Lee KJ, Min BW, Oh GM, Lee SW.** Surgical correction of pelvic malunion and nonunion. *Clin Orthop Surg* 2015;7:396-401.
- Lu S, Wu J, Fu B, et al.** Transiliac osteotomy in surgical management of pelvic post-traumatic malunions: a retrospective study. *Medicine (Baltimore)* 2016;95:e3144.
- Tile M.** Acute pelvic fractures: I. causation and classification. *J Am Acad Orthop Surg* 1996;4:143-151.
- Matta JM, Saucedo T.** Internal fixation of pelvic ring fractures. *Clin Orthop Relat Res* 1989;242:83-97.
- Isler B.** Lumbosacral lesions associated with pelvic ring injuries. *J Orthop Trauma* 1990;4:1-6.
- Isler B, Ganz R.** Classification of pelvic ring injuries. *Injury* 1996;27(suppl 1):S-A3-12.

22. Herren C, Dienstknecht T, Siewe J, et al. Chronic instability of the pubic symphysis: Etiology, diagnostics and treatment management. *Unfallchirurg* 2016;119:433-446.

23. Avilucea FR, Whiting PS, Mir H. Posterior fixation of APC-2 pelvic ring injuries decreases rates of anterior plate failure and malunion. *J Bone Joint Surg [Am]* 2016;98:944-951.

24. Pape HC, Pohlemann T, Gänsslen A, et al. Pelvic fractures in pregnant multiple trauma patients. *J Orthop Trauma* 2000;14:238-244.

25. Matta JM, Yerasimides JG. Table-skeletal fixation as an adjunct to pelvic ring reduction. *J Orthop Trauma* 2007;21:647-656.