

Migration of titanium cable into spinal cord and spontaneous C2 and C3 fusion

Case report of possible causes of fatigue failure after posterior atlantoaxial fixation

Huibo Li, MD, Jigang Lou, MD, Hao Liu, MD, PhD*

Abstract

Introduction: Atlantoaxial instability is a common and serious injury of the upper cervical spine. Brooks' procedure is widely used to reconstruct the unstable atlantoaxial joint. The migration into spinal cord of titanium cable and spontaneous fusion between C2 and C3 has been little reported and the management of such a patient is difficult. We describe an unusual case of fatigue failure of posterior titanium atlantoaxial cable fixation with migration into the spinal cord and spontaneous fusion between C2 and C3.

Case report: A 16-year-old girl complained of cervico-occipital pain with numbness and weakness of extremities 3 months ago. The girl underwent posterior C1–C2 arthrodesis with titanium cables and autogenous iliac crest bone grafting when she was 6 years old. When presented to our emergency department, imaging revealed the cracked titanium atlantoaxial cable and the spontaneous fusion between C2 and C3. Computed tomography demonstrated a broken wire with anterior migration of the cable into the spinal cord. The patient underwent posterior approach cervical spinal surgery to remove the broken cables. She remains neurologically intact a year following the posterior approach cervical spine surgery.

Conclusions: Brooks' posterior stabilization could not effectively control rotation at the atlantoaxial articulation, so surgeons must be aware of the potential of fatigue failure of cables as well as the possibility of its migration into the spinal cord when using Brooks' posterior stabilization. Bilateral C1 lateral mass and C2 pedicle screw fixation or transarticular screw fixation are recommended by the authors in the event of rotatory instability.

Abbreviations: CT = computed tomography, MRI = magnetic resonance imaging.

Keywords: atlantoaxial dislocation, Brooks, case report, posterior, titanium cables

1. Introduction

Atlantoaxial instability is a common and serious injury of the upper cervical spine induced by many causes including trauma, rheumatoid arthritis, and congenital dens dysplasia or absence. Many structures can maintain the stability of the atlantoaxial joint such as transverse ligament, dens, binding ligaments of C1–C2, and lateral joints. The atlantoaxial joint will become unstable if any of these structures are damaged or defective. Atlantoaxial instability may result in serious complications including pain, paralysis, and even death if it is not treated properly. Although there are several methods used to achieve

posterior stabilization, Brooks' posterior stabilization remains a commonly used method of fixation.^[1] Because of successful fusion resulted from meticulous surgery with the use of strong thick wire for fixation and proper autogenous iliac bone graft, Brooks' procedure for the stabilization of the unstable atlantoaxial joint is biomechanically sound and safe.^[2] Meanwhile, the titanium offers significantly improved postoperative imaging, but the hardness and strength decreases, which may result in fatigue failure. As far as we know, there are few reports about the failure of posterior titanium atlantoaxial cable fixation with migration into the spinal cord. We report an unusual case of migration of titanium cable into the spinal cord and spontaneous C2 and C3 fusion.

2. Case report

The patient provided informed consent for the publication of her clinical and radiological data. This case report was approved by Medical Ethical Committee of West China Hospital, Sichuan University. A 16-year-old girl was referred to our department who presented with occipitocervical pain occasionally for 3 months with numbness and weakness of extremities. Other symptoms included headache, dyspnea, nausea, and vomiting, but the sphincter function was normal. The first symptom was occipitocervical pain, and then numbness began to appear in her right arm as well as muscle weakness and convulsions. The girl with painful traumatic atlantoaxial dislocation (Fig. 1) that resulted from a severe neck injury from a fall from a window on

Editor: Perbinder Grewal.

The authors have no funding and conflicts of interest to disclose.

Department of Orthopedics, West China Hospital, Sichuan University, Chengdu, Sichuan Province, China.

* Correspondence: Hao Liu, Department of Orthopedics, West China Hospital, Sichuan University, Chengdu, Sichuan Province, China (e-mail: liuhao6304@163.com).

Copyright © 2016 the Author(s). Published by Wolters Kluwer Health, Inc. This is an open access article distributed under the Creative Commons Attribution-NoDerivatives License 4.0, which allows for redistribution, commercial and non-commercial, as long as it is passed along unchanged and in whole, with credit to the author.

Medicine (2016) 95:52(e5744)

Received: 31 August 2016 / Received in final form: 1 December 2016 /

Accepted: 5 December 2016

<http://dx.doi.org/10.1097/MD.0000000000005744>

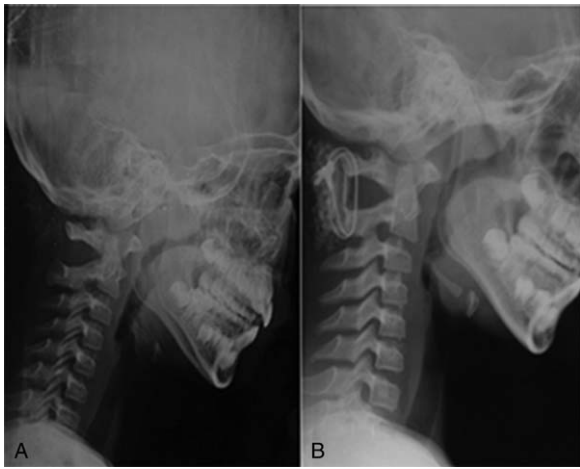


Figure 1. (A and B) X-ray showed traumatic atlantoaxial dislocation and posterior titanium atlantoaxial cable fixation 1 month after the operation.

the second floor underwent posterior C1–C2 arthrodesis with titanium cables and autogenous iliac crest bone grafting (Brooks' posterior stabilization) 10 years ago. Three months ago, the patient complained of a feeling of something “cracking” in her neck and cervico-occipital pain with numbness and weakness of extremities. Hence, she was referred to our hospital for treatment. When presented to our emergency department, imaging was taken, revealing the cracked titanium atlantoaxial cable and the spontaneous fusion between C2 and C3 as well as the absorption of the autogenous iliac crest bone (Fig. 2). The magnetic resonance imaging and computed tomography showed a broken wire with anterior migration of the cable into the spinal cord (Fig. 2).

In light of flexion and extension x-rays revealing persistent biomechanical stability between C1 and C2, the operation was performed to remove the cables. After routine disinfection and draping, the posterior approach was used to expose the posterior

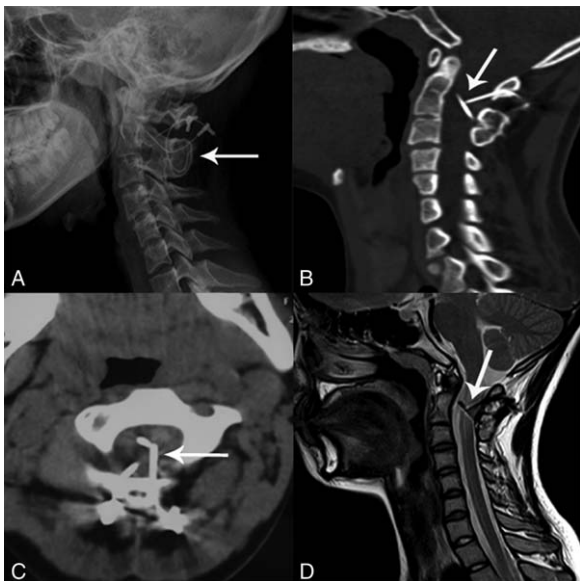


Figure 2. (A–D) The spontaneous fusion between C2 and C3 and a broken wire with anterior migration into the spinal cord (arrow).

arch of atlas, axis, and the cables. During the operation, we found that the bilateral cables were broken. The cables were cut at the invagination of axis laminae. Then, we performed dressing of the section in order to minimize the risk of injury of the spinal cord. The broken cables were abstracted from the spinal canal carefully. C-arm x-ray machine was used to make sure that there were no remaining cables. The wound was washed, drainage tube placed, and the incision sutured step by step.

Postoperatively, the patient was kept in a rigid collar for 2 weeks and she was able to walk unassisted 1 month after surgery. Flexion and extension x-rays were taken at 3 months, which revealed persistent biomechanical stability between C1 and C2 (Fig. 3). Magnetic resonance imaging of the cervical spine was performed, which revealed good stability of the atlantoaxial joint without evidence of cerebrospinal fluid leak (Fig. 3). During 1 year of follow-up, all clinical symptoms disappeared and the flexion and extension x-rays revealed persistent biomechanical stability between C1 and C2 (Fig. 3). And now the patient is neurologically intact with no obvious discomfort.

3. Discussion

The atlantoaxial joint is one of the most complicated joints of the human body. Many causes can affect the stability of this joint such as trauma, dysplastic dens, infection, and arthritis.^[3] Measures should be taken to reconstruct the stabilization of the atlantoaxial joint if the atlantoaxial joint becomes unstable, or the joint becomes permanently unstable. Posterior cervical fusion of C1–C2 or C1–C3 is recommended by many authors, because surgical management is the definitive method of obtaining permanent stability.^[2,4] However, the loss of axial rotation is the main disadvantage of C1–C2 fusion.

The concept of posterior spinal fixation with interspinous process wiring was introduced by Hadra in 1891.^[5,6] Since the introduction of the new technology, many modifications have been reported.^[7] Currently, there are several methods used to achieve posterior stabilization including Gallie procedure, Brooks' procedure, and the Halifax interlaminar clamp.^[8] In a biomechanical study of atlantoaxial fixation, Naderi et al reported that posterior wiring with simulated interspinous bone graft and an oak block significantly enhanced biomechanical stability of the atlantoaxial joint against flexion and extension forces.^[9] Brooks' construct for the stabilization of the unstable atlantoaxial joint leads to a high fusion rate, because it is biomechanically sound and safe as a result of double-stranded strong wire fixation, bone grafting, and subsequent cervical bracing.^[2] However, the main disadvantage is the loss of axial rotation. In addition, although Brooks' procedure provides good control of sagittal and coronal motion, it is not as effective in controlling rotation at the atlantoaxial articulation.^[10]

C1–C2 transarticular fixation has been an effective and appealing method for inducing fusion of the atlantoaxial joint. The use of this technique was first applied to absence of the lamina resulting from laminectomy, congenital anomalies, or trauma.^[6] However, some biomechanical testing revealed that it had higher mechanical advantage over posterior interlaminar techniques.^[6,11] Although transarticular screw fixation has some advantages, highly demanding surgical technique is indispensable. One of the most common complications associated with this technique is screw malposition. In a study by Grob et al, the incidence of screw malposition is 15%. This study showed that 3.4% of the screws were too short, causing them not to cross the joint line, and 1.8% were too long, thus protruding through the

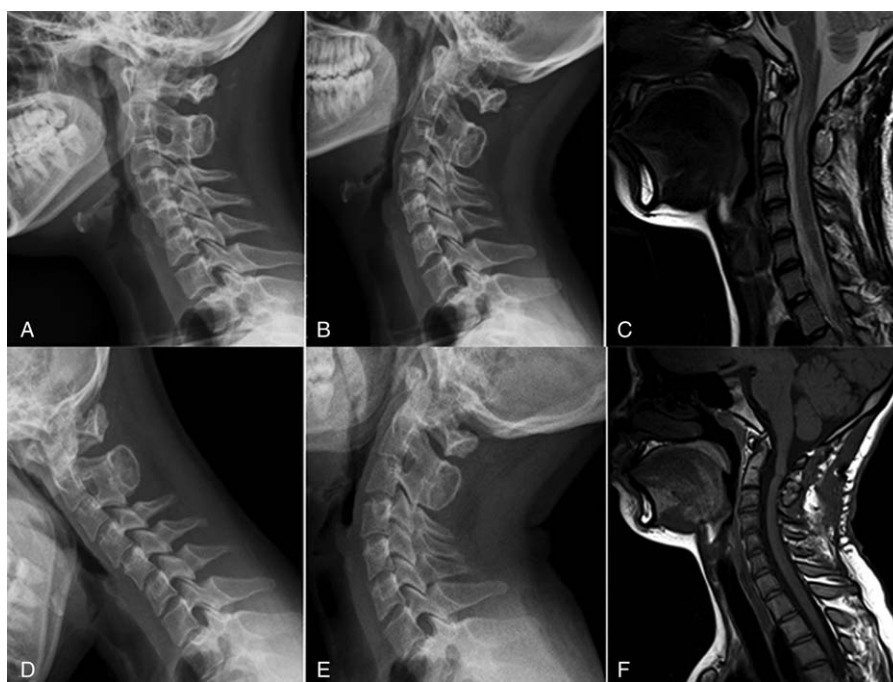


Figure 3. (A–F) Flexion–extension x-rays showed good stability of the atlantoaxial joint 3 and 12 months after the operation.

lateral mass of C0–C1.^[4,6] Screw malposition may result in vertebral artery injury, even implant failure.

To overcome the major complication of vascular and neural injuries, bilateral C1 lateral mass and C2 pedicle screw fixation was introduced by Goel and Laheri in 1994 and modified by Harms and Melcher in 2001.^[12] The superiority of bilateral C1 lateral mass and C2 pedicle screw fixation compared to bilateral transarticular screw fixation is a lower risk of vertebral artery injury due to the use of individual screw systems. However, some problems have been encountered in screw placement including severe anomalous artery injury pathways and restricted pathway for the 3.5-mm screw.

In our case, failure of the cables appears to be mainly the result of the nonunion and persistent loading of the cables resulting in fatigue failure. We hypothesize that spontaneous fusion of C2–C3 might be caused by debris from C1–C2, where the cables could cut the autogenous iliac crest bone. We also suspect that a spontaneous fusion of C2–C3 may result in the biomechanical change of cervical vertebrae and persistent loading of the cables leading to fatigue failure. Meanwhile, the absorption of the iliac bone graft further aggravates the stress concentration at the atlantoaxial articulation. Therefore, all of the above-mentioned factors caused the nonunion of C1–C2. Therefore, we supposed that micromotion caused by nonunion of C1–C2 would affect fusion and result in fatigue failure. Many studies have found that “spring phenomenon” could result in the bow of metal wires or cables, which leads to encroachment upon the spinal cord.^[13,14] Further, because of the implant inside the spinal canal, Brooks’ procedure carries the potential risk of complications associated with wire loosening. Therefore, surgeons must be aware of the potential for failure of arthrodesis and subsequent fatigue failure of cables as well as the possibility of its migration into the spinal cord. In our case, the operation was performed to remove the broken cables to minimize the risk of injury of the spinal cord. Flexion and extension x-rays were taken at 1 and 3 months, respectively, which revealed persistent biomechanical stability

between C1 and C2. We hypothesize that the transverse ligament might heal and maintain the atlantoaxial stability during the process, so the patient underwent posterior approach cervical spinal surgery without fixation because of the good stability of the atlantoaxial joint showed in flexion and extension x-ray image.

4. Conclusion

In conclusion, Brooks’ posterior stabilization could not effectively control rotation at the atlantoaxial articulation, so surgeons must be aware of the potential of fatigue failure of cables as well as the possibility of its migration into the spinal cord when using Brooks’ posterior stabilization. Bilateral C1 lateral mass and C2 pedicle screw fixation or transarticular screw fixation are recommended by the authors in the event of rotatory instability.

Acknowledgments

The authors thank the following spinal surgeons in their department for their participation in the discussion before the revision surgery: Yueming Song, Jiancheng Zeng, Liming Liu, Qingquan Kong, Zhou, Beiyu Wang, and Yuxiao Deng.

References

- [1] Mimatsu K, Katoh F, Kawakami N, et al. Atlantoaxial fusion with posterior double wire fixation. *Spine* 1992;17:1409–13.
- [2] Moon MS, Choi WT, Moon YW, et al. Brooks’ posterior stabilisation surgery for atlantoaxial instability: review of 54 cases. *J Orthop Surg* 2002;10:160–4.
- [3] Anderson LD, D’Alonzo RT. Fractures of the odontoid process of the axis. *J Bone Joint Surg* 1974;65A:1663–79.
- [4] Grob D, Jeanneret B, Aebi M, et al. Atlanto-axial fusion with transarticular screw fixation. *J Bone Joint Surg* 1991;73B:972–6.
- [5] Hadra BE. Wiring the vertebrae as a means of immobilization in fractures and Pott’s disease. *Clin Orthop Relat Res* 1975;112:4–8.
- [6] Garcia R Jr, Gorin S. Failure of posterior titanium atlantoaxial cable fixation. *Spine J*. 2003;3:166–170.

- [7] Brooks AL, Jenkins EW. Atlanto-axial arthrodesis by the wedge compression method. *J Bone Joint Surg Am* 1978;60A:279–84.
- [8] Sherk HH, Snyder B. Posterior fusions of the upper cervical spine: indications, techniques, and prognosis. *Orthop Clin North Am* 1978; 9:1091–9.
- [9] Naderi S, Crawford NR, Song GS, et al. Biomechanical comparison of C1–2 posterior fixations. Cable, graft, and screw combinations. *Spine* 1998;23:1946–56.
- [10] Grob D, Crisco JJ, Panjabi MM, et al. Biomechanical evaluation of four different posterior atlantoaxial fixation techniques. *Spine* 1992;17: 480–9.
- [11] Hanson PB, Montesano PX, Sharkey NA, et al. Anatomic and biomechanical assessment of transarticular screw fixation for atlantoaxial instability. *Spine* 1991;16:1141–5.
- [12] Harms J, Melcher RP. Posterior C1–C2 fusion with polyaxial screw and rod fixation. *Spine* 2001;26:2467–71.
- [13] Ito T, Hayashi M, Takei H. Loosening of supplemental cable in transarticular screw fixation and bone grafting. *J Orthop Surg* 1998; 6:71–4.
- [14] Bahadur R, Goyal T, Dhatt SS, et al. Transarticular screw fixation for atlantoaxial instability—modified Magerl’s technique in 38 patients. *J Orthop Surg Res* 2010;5:87.