

—NOTE—

## Survey of the Occurrence of Equine Deep Digital Flexor Tendon Contraction (Clubfoot) in the Main Thoroughbred Breeding Area in Japan

Kosuke TANAKA<sup>1,3</sup>, Yo ASAI<sup>1</sup> and Atsutoshi KUWANO<sup>2\*</sup>

<sup>1</sup>Equine Science Division, Hidaka Yearling Training Farm, Japan Racing Association, 535-13 Nishicha, Urakawa-cho, Urakawa-gun, Hokkaido 057-0171, <sup>2</sup>Clinical Science & Pathobiology Division, Equine Research Institute, Japan Racing Association, 321-4 Tokami-cho, Utsunomiya-shi, Tochigi 320-0856, <sup>3</sup>The Japan Bloodhorse Breeders' Association, Shizunai Stallion Station, 517 Shizunaitahara, Shin-hidaka, Hidaka, Hokkaido 056-0144, Japan

---

*At 114 ranches in the Hidaka District of Hokkaido, a total of 1,118 Thoroughbred foals that were born from January to June 2003 were examined at different times from May to September of the same year to ascertain the occurrence of clubfoot. Clubfoot was seen in a total of 179 foals (16%) at 89 ranches (78%). Also, 124 of the 179 foals (69.3%) had clubfoot of grade II or higher, and it was found that grade I was likely to be overlooked or rapidly advance. In the present study, the occurrence of clubfoot was higher than expected in the investigated region. Hence, it is necessary to establish accurate diagnostic techniques and clubfoot guidelines to minimize the impact.*

**Key words:** clubfoot, foals, Japan, Thoroughbred

**J. Equine Sci.**  
**Vol. 20, No. 2**  
**pp. 15-17, 2009**

---

Flexural deformities in foals, such as an abnormal gait, broken forward of the digital axis, and hoof deformity, can be congenital or acquired [2, 5], and multiple factors are involved in a complicated manner in the onset of clubfoot [1, 5]. Deep digital flexor tendon contraction (DDFTC) and superficial digital flexor tendon contraction (SDFTC) are common factors. In chronic DDFTC, the hoof angle exceeds 80° [6], and the appearance from the pastern and foot resembles the head and shaft of a wood golf club. This condition is referred to as clubfoot [2]. Clubfoot is a progressive disease in which symptoms advance in stages [6], and even when the foot does not yet resemble a golf club, the end stage is the same when left untreated. The, early-stage of DDFTC is characterized by flexural deformity of the interphalangeal joint without a club-shaped appearance and is also diagnosed as clubfoot [2]. In the USA, it has been reported that clubfoot affects foals that are 1.5 to 8

months of age [1]. DDFTC is often acquired, but it is rarely congenital [1, 9]. While lameness related with foot pain, nutritional problems and other factors have been listed as factors for acquired DDFTC [1, 2, 4, 7], it has not been determined whether musculotendinous shortening results from muscular contraction, tendinous tissue contraction, or a combination of both [9]. It has been proposed that, because the mesenchymal cells that make up the deep digital flexor tendon and its supportive ligament in foals are myofibroblastic cells having alpha-smooth muscle actin, the contractive force of smooth muscle fibers may be closely related to deep flexor tendon contracture [3]. Regardless of the cause, deformities of the hoof conformation are secondary [2]. When left untreated, deformities of the hoof conformation and standing posture can become too severe to be corrected by adjusting the digital axis using only hoof trimming or shoeing, and the foals may become worthless as racehorses. Hence, it is important to determine the occurrence of hoof deformities to ensure a large pool of foals become racehorses. To the best of our

---

This article was accepted March 30, 2009

\*Corresponding author. e-mail: hoofvet@center.equinst.go.jp

knowledge, there has no prior report of the occurrence of clubfoot in Japanese Thoroughbred breeding areas, so we determined to survey this. At 114 ranches in the Hidaka district of Hokkaido, a total of 1,118 Thoroughbred foals that were born from January to June 2003 were examined (Table 1). Farriers visited the participating ranches at different times, and the occurrence of clubfoot was determined by examining the digital axis and hoof conformation of foals (each foal with clubfoot was counted as one). The study was conducted over a five-month period from May to September 2003, and each ranch was visited once a month. At the time of hoof trimming, digital axis and hoof conformation were examined to determine the presence or absence of flexural deformity of the digits,

the gap between the flat ground surface and the weight-bearing surface of the heel, coronet swelling, hoof wall curvature (dish), and change of the dorsal hoof wall angle in relation to the opposite normal foot. Also, using Redden's method [6], the degree of disease progression was classified into four grades (Table 2), and the age in months and grade of clubfoot at the initial diagnosis were recorded. X-ray examinations were not performed.

The survey results showed that 179 of the 1,118 foals (16%) were diagnosed with clubfoot, and the most frequently encountered grade at the initial diagnosis was G II (Table 3). The reason for detecting many cases of clubfoot at G II or higher was that G I was likely to be overlooked or rapidly advance in those cases. Also, at the initial diagnosis, clubfoot syndrome developed most frequently at the age of 3 months, and episodes in the 2–4 months age range accounted for 93.8% of the total (Table 3). The results suggest that we need to be careful for axial changes of digits in foals older than three months of age. Clubfoot was unilateral in all foals. It was seen in 93 left forelimbs and 86 right forelimbs, but did not occur in hindlimbs. Because the center of gravity of the body is towards the forelimbs in horses [8], some mechanical factors may be involved since onset of clubfoot was only seen in forelimbs. Furthermore, this disease was seen at 89

**Table 1.** The total number of foals examined at all farms

Month of birth	Number
Jan.	18
Feb.	119
Mar.	396
Apr.	400
May	168
Jun.	17
Total	1,118

\*No foals were born after July.

**Table 2.** The definition of disease grade according to Redden's method

Grade I (G I)	when compared to the normal foot (opposite site), the hoof angle of the affected one is 3–5 degrees greater.
Grade II (G II)	when compared to the normal foot (opposite site), the hoof angle of the affected one is 5–8 degrees greater, and the hoof ring interval is wider at the heel than at the toe.
Grade III (G III)	the features for GII are more notable, and broken forward of the interphalangeal joint is more progressing than GII.
Grade IV (G IV)	the hoof angle of the affected foot is $\geq 80^\circ$ , and the altitude of the coronet is equal between the toe and the heel.

**Table 3.** The number of affected foals in each Grade

Age in months	Grade on the initial examination				Total	Population (%)
	G I	G II	G III	G IV		
1	4	4	0	0	8	4.5
2	16	23	4	0	43	24.0
3	29	62	3	0	94	52.5
4	6	17	8	0	31	17.3
5<	0	3	0	0	3	1.7
Total	55	109	15	0	179	
Population (%)	30.7	60.9	8.4	0		100.0

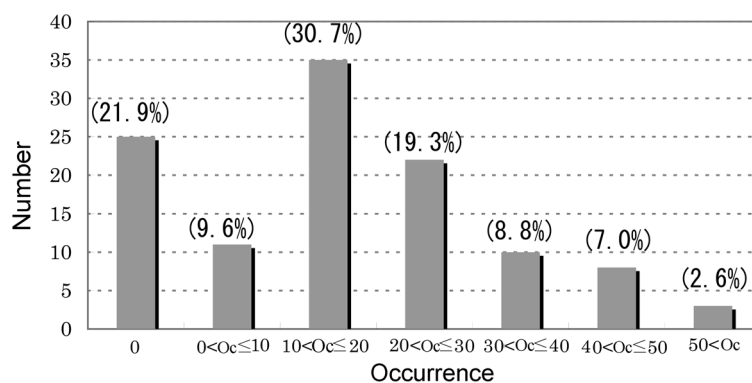


Fig. 1. Number (percent) of breeding farms with clubfoot.

ranches (78.1% of the total), but was not seen at 25 ranches (21.9% of the total). Physical features and breeding conditions varied greatly among the ranches, but clubfoot was seen at most ranches, thus suggesting there is no ranch that does not need to be vigilant. Furthermore, the ranches with occurrences of 10–30% were the overwhelming majority of breeding farms (Fig. 1). Since these numbers were higher than expected in the investigated region, it will be necessary to develop countermeasures in this area. At one ranch, a clubfoot occurrence of 66.7% was seen. Unlike the other ranches, this ranch was situated on a riverbed. The grazing land at this ranch was very hard, as it was covered with relatively hard clay as additional soil. This suggested that hard soil was likely to damage the developing limbs of foals and might cause clubfoot through some unknown mechanism.

The present study identified the tendencies for clubfoot in the main Thoroughbred breeding area of Japan. In the future, it will be necessary for ranchers, farriers, and veterinarians to collaborate investigating onset factors, environmental factors, nutritional factors and treatment methods.

### Acknowledgement

The authors would like to thank the members of the Hidaka Farriers Association and the Hidaka Veterinarians Association for their assistance, and Dr. Osamu Aoki from the Japan Farriers Association for his help in preparing the present manuscript.

### References

- 1) Adams, S.B., and Santschi, E.M. 2000. Management of congenital and acquired flexural limb deformities. *Proc. Am. Assoc. Equine Pract.* **46**: 117–125.
- 2) Curtis, S. 2006. Farriery in the treatment of acquired flexural deformities. pp. 557–567. *In: Corrective farriery Vol.II* (Curtis, S. ed.) Newmarket Farrier Consultancy. R & W Publications (Newmarket) Ltd, Newmarket.
- 3) Hartzel, D.K., Arnoczky, S.P., Kilfoyle, S.J., and Stick, J.A. 2001. Myofibroblasts in the accessory ligament (distal check ligament) and the deep digital flexor tendon of foals. *Am. J. Vet. Res.* **62**: 823–827.
- 4) Hunt, R.J., Kobluk, C.N., and Steckel, R.R. 1995. Clubfoot. pp. 692–693. *In: The Horse I* (Kobluk, C.N., Ames, T.R., and Geor, R.J. eds.) W.B. Saunders Company, Philadelphia.
- 5) McIlwraith, C.W. 2002. Diseases of joints, tendons, ligaments, and related structures. pp.459–479. *In: Adams' Lameness in Horses*. 5th ed. (Stashak, T.S. ed.) Lippincott Williams & Wilkins, Philadelphia.
- 6) Redden, R.F. 1988. A method of treating club feet. *Proc. Am. Assoc. Equine Pract.* **34**: 321.
- 7) Savage, C.J., and Lewis, L.D. 2002. The role of nutrition in musculoskeletal development and disease. pp.377–399. *In: Adams' Lameness in Horses*. 5th ed. (Stashak, T.S. ed.) Lippincott Williams & Wilkins, Philadelphia.
- 8) Springings, E., and Leach, D. 1986. Standardised technique for determining the centre of gravity of body and limb segments of horses. *Eqine Vet. J.* **18**: 43–49.
- 9) Stashak, T.S., Hill, C., Klimesh, R., and Ovnicek, G. 2002. Trimming and shoeing for balance and soundness. pp. 1081–1144. *In: Adams' Lameness in Horses*. 5th ed. (Stashak, T.S. ed.) Lippincott Williams & Wilkins, Philadelphia.