

Modified Conventional Root Canal Shaping Technique in Primary Teeth: An *In Vivo* Study

Rajendra Reddy E¹, Srikanth S Raju², Thabitha Sandipamu³, Kiranmayi M⁴, Srujana Palicarp Mudusu⁵, Sai Divya Saraswati⁶

ABSTRACT

Aim and objective: The purpose of the study was to compare the efficiency of modified conventional root canal shaping technique versus conventional shaping technique in primary teeth.

Materials and methods: A total of 184 primary root canals (2 groups of 92 canals each) with two-thirds of root length were selected and randomly allocated into two different shaping techniques, i.e., Group I: conventional root canal shaping technique, Group II: modified root canal shaping technique. The quality of obturation (Coll and Sadrain, 1996) and presence or absences of voids were assessed by using radiographs. The recorded data was statistically analyzed.

Results: Significant difference was seen between conventional and modified conventional techniques in underfilled and optimally filled canals.

Conclusion: This modified cleaning and shaping technique can be considered as alternative to conventional instrumentation technique, as it improves quality of obturation and decreases the number of voids.

Keywords: Modified root canal shaping technique, Primary teeth, Quality of obturation, Voids.

International Journal of Clinical Pediatric Dentistry (2022); 10.5005/jp-journals-10005-2121

INTRODUCTION

The clinical success of endodontic treatment depends on multiple factors such as root canal morphology, access cavity preparation, cleaning, and shaping of canals and obturation.^{1,2} The quality of obturation is greatly affected by proper cleaning and shaping of the root canal as well as the 3-dimensional (3D) hermetic sealing of the root canal.³ The removal of organic debris in primary root canals is the main purpose of instrumentation, which can be done either with conventional or rotary endodontic instruments. Although conventional instrumentation is widely used, there are limitations regarding the quality of obturation. The NiTi rotary systems transform the root canals into conical shape, which enhances the quality of obturation⁴ and as the time required for the preparation is less, they are more convenient to work faster in children with behavior management problems.⁵ But the disadvantages of rotary system were high cost and the need for adequate training to learn the technique.^{6,7} In order to overcome the limitations of both the conventional and rotary techniques, a modified conventional root canal shaping technique was developed where hand Protaper Sx was used as last instrumentation file after conventional cleaning and shaping of canals. The aim of the present study was to evaluate the quality of obturation using the two techniques, i.e., conventional and modified conventional root canal shaping technique.

MATERIALS AND METHODS

Study design: This is a randomized, clinical trial study approved by the Ethical Committee of the Kamineni Institute of Dental Sciences, Narketpally (Ethical committee number-KIDS/IEC/PEDO/18/7)

Patient selection: The participants were recruited from the walk-in patients of Department of Pedodontics and Preventive Dentistry, Kamineni Institute of Dental Sciences, Narketpally. After conducting a pilot study, a sample of 92 canals in each group was finalized. Within the duration of 6 months, a total of 76 teeth (32 maxillary

¹⁻⁵Department of Pedodontics and Preventive Dentistry, Kamineni Institute of Dental Sciences, Nalgonda, Telangana, India

⁶Private Practitioner, Srikanth Multi Speciality Dental Hospital, Suryapet, suryapet, Telangana, India

Corresponding Author: Srikanth S, Department of Pedodontics and Preventive Dentistry, Kamineni Institute of Dental Sciences, Nalgonda, Telangana, India, Phone:+91 9030912230, e-mail: srikanth1090@gmail.com

How to cite this article: Reddy ER, Raju SS, Sandipamu T, *et al.* Modified Conventional Root Canal Shaping Technique In Primary Teeth: An *In Vivo* Study. *Int J Clin Pediatr Dent* 2022;15(S-1):S8-S11.

Source of support: Nil

Conflict of interest: None

and 44 mandibular) from 50 healthy and cooperative children were included in the study. Parental informed consent was obtained prior to the study.

Inclusive Criteria

- Teeth with at least two-third of root length and with adequate bone support
- Teeth with intact enamel but show all signs of irreversible pulpitis or with a necrotic pulp

A total of 76 teeth with 32 maxillary (96 canals) and 44 mandibular (88 canals) were randomly divided into two groups:

Group I: Conventional root canal shaping technique with k files

Group II: Modified conventional root canal shaping technique

Group I: To standardize the study, pulpectomy procedures were carried out by single operator in both the groups. Preoperative intraoral periapical radiograph was taken for each tooth. The tooth was anesthetized and isolated with rubber dam. The access openings of pulp chamber in primary teeth were done

with great care to avoid perforation of pulpal floor. The entire carious tooth structure was removed and access was gained by using #2 round bur. Endo Z bur (Dentsply, Switzerland) was used to remove the entire roof of the pulp chamber to provide straight line access to the canals. The canals were negotiated using endodontic files and radicular pulp tissue was removed with barbed broaches and H files. The working length was established 1–2 mm short of radiographic apex length to avoid overextension. The root canals were instrumented till 30 size k file. The root canals were thoroughly irrigated with 2.5% sodium hypochlorite and saline solution was used as the last irrigating medium. The root canals were thoroughly dried using absorbent paper points by inserting them 1 mm short of radiographic apex and later a homogenous mixture of Zinc Oxide Eugenol (ZOE) was used for filling the root canals.

Group II: The same pulpectomy procedure was carried out except the difference was final coronal shaping was done with hand protaper Sx file after conventional instrumentation with 30 size k file followed by ZOE obturation.

Specifications of Sx File

- Shorter length: 19 mm
- D0 diameter: 0.19 mm; D14 diameter: 1.20 mm
- There is increase in taper up to D9 and then taper drops up to D14, which increases its flexibility
- Used for shaping canal orifice

Direction for use

- The file should be used in a clockwise motion and gently rotate the handle until it is just snug. When the handle is snug, the flutes of the file are lightly engaging dentin.
- The dentin should be cut by rotating the handle in a clockwise motion while simultaneously withdrawing the file
- If overengaged, disengage the file by rotating the handle counterclockwise 45–90° while concomitantly withdrawing the instrument
- Repeat the handle motions until desired length is achieved
- In more difficult canals, one, two, or three recapitulations may be necessary to enlarge the coronal two-thirds of the canal.

Postoperative radiographs were obtained for each tooth using same radiographic settings described for the preoperative radiographs.

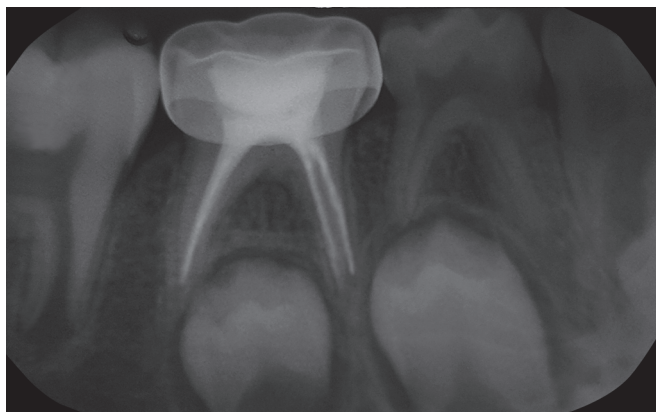

Fig. 1: Optimally filled canal obtained with modified conventional shaping technique

Two blinded, calibrated observers assessed the quality of the filled canals by measuring the distance of the ZOE filling from the apex (mm) by using a special ruler. The quality of root canal filling was evaluated as: underfilling, if the canal was filled >2 mm short of apex; optimal filling, if the canal was filled at the radiographic apex or up to 2 mm short of radiographic apex, and overfilling, presence of material beyond the root apex.⁸

The teeth were examined radiographically by both evaluators independently and then reviewed together if there was any disagreement. The treatment was judged to be successful when the teeth showed optimal filling with no voids.

RESULTS

Group I (conventional shaping technique) showed 32% of underfilled canals, 55% of optimally filled canals, and 13% of overfilled canals (Fig. 1)

Group II modified conventional shaping technique) showed 8% of underfilled canals, 83% of optimally filled canals and 9% of overfilled canals (Fig. 2)

Significant difference was seen between conventional and modified conventional techniques in underfilled and optimally filled canals (Table 1).

In terms of presence of voids, only 18% of canals obturated with modified conventional technique showed presence of voids; whereas, 45% of canals obturated with conventional technique showed presence of voids (Table 2)

DISCUSSION

Primary root canals are more ribbon-like and have tortuous configurations making pulp extirpation difficult.^{9,10} The primary objectives of cleaning and shaping the root canal system were to remove soft and hard tissue containing bacteria, providing a path for irrigants to the apical third, supplying space for medicaments and subsequent obturation, retaining the integrity of radicular structure.¹¹ Obturation of the root canal must be hermetic to ensure eradication of microorganisms and prevent their regrowth to avoid subsequent periapical diseases.² Root canal instrumentation is performed with files, reamers, sonic instruments, and recently with rotary instruments.¹² The use of Nickel Titanium (NiTi) rotary files in primary teeth root canals was first described by Barr et al.⁶ These NiTi alloy instruments inherent flexibility that allows the files to preserve the original anatomy of curved canals, especially in

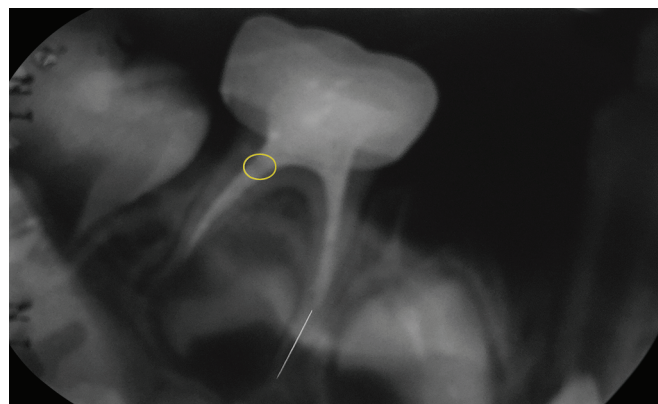


Fig. 2: Underfilled canal and void obtained with conventional shaping technique

Table 1: Descriptive statistics of percentage, mean value, and *p* value of underfilled, optimally filled canals, and overfilled canals obtained with conventional and modified conventional shaping techniques

Obturing technique	Quality of obturation					
	Optimally filled canals		Overfilled canals		Underfilled canal	
	Percentage	Mean value	Percentage	Mean value	Percentage	Mean value
Group I	54.3	1.31	13	0.31	32.60	0.78
Group II	83	2.02	9	0.21	8	0.18
<i>p</i> value	0.00		0.102		0.00	

Table 2: Descriptive statistics of percentage of presence and absence of voids and *p* value obtained with conventional and modified conventional shaping techniques

Groups	Presence of voids (%)	Absence of voids (%)
Group I	44.7	55.3
Group II	18.4	81.6

primary teeth and reduce the chances of procedural errors.¹³ Even though the use of the rotary instrumentation technique enhances the quality of obturation, the disadvantages of NiTi rotary files are high cost, the need for training to learn the technique, cyclic fatigue, tendency to fracture,¹⁴ and inefficiency in cleaning the isthmus and fins of primary teeth due to the centering of rotary instruments in the root canal.¹⁵

According to Barbizam JV,¹⁶ the conventional technique was more efficient in cleaning mesial-distal flattened root canals than the rotary technique. Mokhtari et al.¹⁷ in their study concluded that there was no significant difference in quality of obturation when compared between conventional and rotary instrumentation in primary teeth. In contrary, there are studies which proposed that rotary technique is more efficient in providing good quality of obturation than manual instrumentation technique.^{5,15}

In this study, root canals obturated with conventional technique showed more number of underfilled canals and presence of voids because it was difficult to acquire conical shape of root canal preparation with the standard conventional k file technique.

In modified conventional root canal shaping technique, when Sx is used as last instrumenting file, the conical shape of root canal is achieved facilitating better obturation. The gradual tapering of Sx file can selectively remove dentin in a safe way and can reach the entire length of the root canal, causing little or no displacement, particularly in the apical region. Sx file eliminates the constriction of initial part of canal, thus making the easier penetration of instruments and irrigation solutions till the apex.¹⁸ This in turn helps the obturating material to flow easily till the apical part of canal thereby improves the quality of obturation and reduces the number of voids. This might be the reason in this study, modified root canal shaping technique showed least number of underfilled canals and less number of presence of voids compared to conventional technique.

The successful outcome of an obturated primary tooth is predicted by the quality of obturation of canals. This can be achieved by many rotary systems specifically tailored for primary teeth. But, not every practicing dentist or pediatric dentist will have access to these rotary systems all the time and they may not be economical for certain patients. This modified conventional shaping technique was economical and easy to practice, as it does not require any training in learning the technique. With this simple moderation, the quality of obturation will be significantly enhanced

compared to conventional technique. In current postgraduate curriculum in various parts of world, rotary instrumentation was not followed during examination. So, this modified protocol will help postgraduates to acquire a good conical shape and improves the density of obturation especially in curved and difficult canals.

CONCLUSION

This modified cleaning and shaping technique can be considered as substitute over conventional instrumentation technique, as it gives a good conical shape to root canals. This technique improves density of obturation especially in curved and difficult canals, is easy to practice, and is cost effective.

ORCID

Srikanth S  <https://orcid.org/0000-0001-7442-3821>

REFERENCES

- Ureyen Kaya B, Keçeci AD, Guldaz HE, et al. A retrospective radiographic study of coronal-periapical status and root canal filling quality in a selected adult Turkish population. *Med Princ Pract* 22(4): 334–339. DOI: 10.1159/000346940
- Kalender A, Orhan K, Aksoy U, et al. Influence of the quality of endodontic treatment and coronal restorations on the prevalence of apical periodontitis in a Turkish Cypriot population. *Med Princ Pract* 22(2): 555–560. DOI: 10.1159/000341753
- Kierklo A, Tabor Z, Pawińska M, et al. A Microcomputed Tomography-Based Comparison of Root Canal Filling Quality following Different Instrumentation and Obturation Techniques. *Med Princ Pract* 2015;24(1):84–91. DOI: 10.1159/000368307
- Kummer TR, Calvo MC, Cordeiro MM, et al. Ex vivo study of manual and rotary instrumentation techniques in human primary teeth. *Oral Surg Oral Med Oral Pathol Oral Radiol Endod* 2008;105(4):e84–e92. DOI: 10.1016/j.tripleo.2007.12.008
- Mehlawat R, Kapoor R, Gandhi K, et al. Comparative evaluation of instrumentation timing and cleaning efficacy in extracted primary molars using manual and NiTi rotary technique – In vitro study. *J Oral Biol Craniofac Res* 2019;9(2):151–155. DOI: 10.1016/j.jobcr.2019.03.003
- Barr ES, Kleier DJ, Barr NV. Use of nickel-titanium rotary files for root canal preparation in primary teeth. *Pediatr Dent* 2000;22(1):77–78.
- Azar MR, Safi L, Nikaein A. Comparison of the cleaning capacity of Mtwo and ProTaper rotary systems and manual instruments in primary teeth. *Dent Res J* 2012;9(2):146–151. DOI: 10.4103/1735-3327.95227
- Coll JA, Sandrian R. Predicting pulpectomy success and its relationship to exfoliation and its succedaneous dentition. *Pediatr Dent* 1996;18:57–63.
- Frankl SN. Pulp therapy in pedodontics. *Oral Surg Oral Med Oral Pathol* 1972;34(2):293–309. DOI:10.1016/0030-4220(72)90422-7
- Curzon MEJ, Roberts JF, Kennedy DB. *Paediatric operative dentistry*, 4th edition. Bothell, WA: Wright 1996. pp. 143–144.
- Cohen S, Hargreaves KM. *Pathways of the Pulp*, 9th edition. St. Louis: Mosby; 2006. pp. 301–311.

12. Farhin K, Devendra P, Jitesh P, et al. Application of Rotary Instrumentation in Paediatric Endodontics - A Review. *I J Pre Clin Dent Res* 2014;1(3):48–52.
13. Crespo S, Cortes O, Garcia C, et al. Comparison between rotary and manual instrumentation in primary teeth. *J Clin Pediatr Dent* 2008;32(4):295–298. DOI: 10.17796/jcpd.32.4.157136355u606576
14. Morankar R, Goyal A, Gauba K, et al. Manual versus rotary instrumentation for primary molar pulpectomies- A 24 months randomized clinical trial. *Pediatric Dent J* 2018;28(2):96–102. DOI: 10.1016/j.pdj.2018.02.002
15. Panchal V, Jeevanandan G, Subramanian EM. Comparison of instrumentation time and obturation quality between hand K-file, H-files, and rotary Kedo-S in root canal treatment of primary teeth: A randomized controlled trial. *J Indian Soc Pedod Prev Dent* 2019;37(1):75–79. DOI: 10.4103/JISPPD.JISPPD_72_18
16. Barbizam JVB, Fariniuk LF, Marchesan MA, et al. Effectiveness of manual and rotary instrumentation techniques for cleaning flattened root canals. *J Endod* 2002;28(5):365–366. DOI: 10.1097/00004770-200205000-00004
17. Mokhtari N, Sarraf-Shirazi A, Ebrahimi MA. Smart rotary technique versus conventional pulpectomy for primary teeth: A randomized controlled clinical study. *J Clin Exp Dent* 2017;9(11):e1292-e1296. DOI: 10.4317/jced.53968
18. Diaconu O, Batăiosu M, Ţuculina M, et al. The Mechanic Canal Treatment Using the Protaper Manual System. *Curr Health Sci J* 2009;35(2):140–142. DOI 10.12865/CHSJ.35.02.12