

## Multimodal imaging characteristics of acute macular neuroretinopathy

Kumar Saurabh, Rupak Roy<sup>1</sup>, Dhairat Shah<sup>2</sup>,  
Sugandha Goel<sup>2</sup>, Samarth Mishra<sup>2</sup>, Deepak Senger<sup>1</sup>

**Key words:** Acute macular neuroretinopathy, autofluorescence, multicolor imaging, multimodal imaging, near infrared autofluorescence

Acute macular neuroretinopathy (AMN) usually presents as brown-red lesion near fovea.<sup>[1,2]</sup> Spectral domain optical coherence tomography (SDOCT) shows initial thickening of the outer plexiform layer (OPL), eventual thinning of outer nuclear layer (ONL) and focal disruptions of external limiting membrane (ELM) and ellipsoid zone (EZ).<sup>[1]</sup> We herein report the multicolor, reflectance, and autofluorescence imaging characteristics of AMN.

### Case Report

A 19-year-old healthy female presented with complaint of seeing black spot in front of her left eye for 1 week. The left eye showed a faint yellowish brown-wedge-shaped depigmentation inferonasal to fovea [Fig. 1a]. Multicolor image showed a zone of pale-pink discoloration with loss of perifoveal greenish hue [Fig. 1b]. SDOCT line scan through the lesion showed focal thickening of OPL with thinning of underlying

ONL and focal disruption of ELM [Fig. 1c]. Infrared channel of multicolor imaging aimed at picking the outer retinal lesions showed zone of hyperreflectance [Fig. 1d]. The pseudocolor encoding for this channel is red which explains the pinkish discoloration of lesion amidst the greenish perifoveal hue on multicolor image.<sup>[3]</sup> Based on these findings, a diagnosis of AMN was made. Blue autofluorescence (BAF) image showed wedge-shaped hyperautofluorescence interspersed with hypoautofluorescent zones [Fig. 2a].

### Discussion

AMN leads to variable disruption of photoreceptors seen as disruption of ELM and EZ. The resulting stress of retinal pigment epithelium (RPE) may present as hyperautofluorescence while interspersed hypoautofluorescent regions suggest damaged RPE. Near-infrared autofluorescence (NIR-AF) image revealed area of hypoautofluorescence over the AMN lesion [Fig. 2b]. Both BAF and NIR-AF depict RPE damage in this case which is a feature of AMN.<sup>[4]</sup>

Our report depicts the imaging signatures of AMN using newer imaging modalities like multicolor, BAF, and NIR-AF. Studies with larger number of AMN cases will further validate our findings.

### Declaration of patient consent

The authors certify that they have obtained all appropriate patient consent forms. In the form the patient(s) has/have given his/her/their consent for his/her/their images and other clinical information to be reported in the journal. The patients understand that their names and initials will not be published and due efforts will be made to conceal their identity, but anonymity cannot be guaranteed.

### Financial support and sponsorship

Nil.

### Conflicts of interest

There are no conflicts of interest.

Access this article online	
Quick Response Code:	Website: www.ijjo.in
	DOI: 10.4103/ijjo.IJO_969_18

Retina Services, Kamalnayan Bajaj Sankara Nethralaya, <sup>1</sup>Retina Services, Aditya Birla Sankara Nethralaya, Kolkata, West Bengal, <sup>2</sup>Sri Bhagwan Mahavir Vitreoretina Services, Sankara Nethralaya, Chennai, Tamil Nadu, India

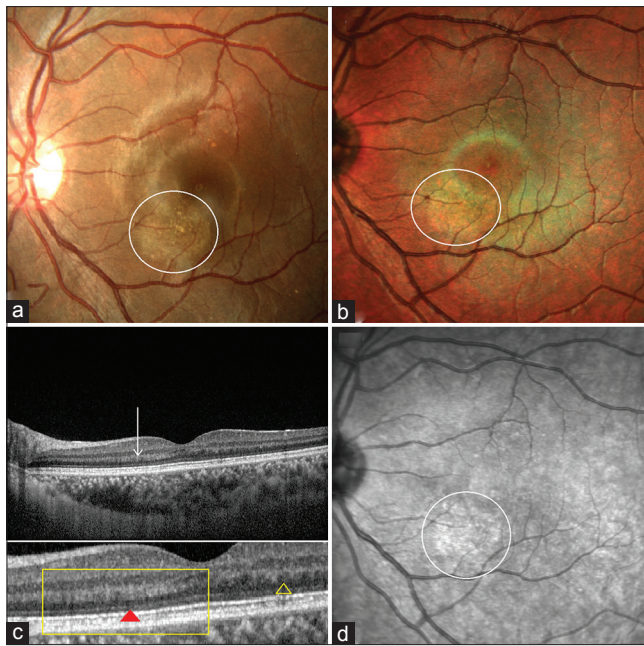
**Correspondence to:** Dr. Kumar Saurabh, Kamalnayan Bajaj Sankara Nethralaya, DJ16, Action Area 1D, New Town, Kolkata - 700 156, West Bengal, India. E-mail: vrfellow@gmail.com

Manuscript received: 19.07.18; Revision accepted: 25.10.18

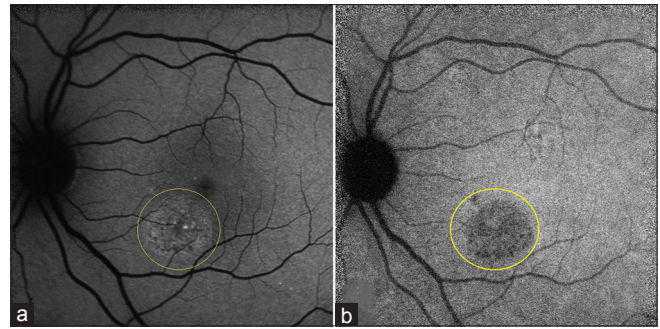
This is an open access journal, and articles are distributed under the terms of the Creative Commons Attribution-NonCommercial-ShareAlike 4.0 License, which allows others to remix, tweak, and build upon the work non-commercially, as long as appropriate credit is given and the new creations are licensed under the identical terms.

**For reprints contact:** reprints@medknow.com

**Cite this article as:** Saurabh K, Roy R, Shah D, Goel S, Mishra S, Senger D. Multimodal imaging characteristics of acute macular neuroretinopathy. Indian J Ophthalmol 2019;67:403-4.



**Figure 1:** (a) Color fundus photograph of left eye showing an area of yellowish brown depigmentation inferonasal to fovea (white circle); (b) multicolor composite showing loss of perifoveal greenish hue over the area of acute macular neuroretinopathy lesion along with pinkish discoloration (white circle); (c) line scan SDOCT image through the lesion showing thickening of outer plexiform layer (OPL) on the nasal side of fovea compared with the temporal side (white arrow). The difference in the OPL thickness can be clearly made out in blown up image in the lower panel (yellow rectangle) comparing with the temporal OPL (yellow triangle). Note the subtle zone of discontinuity of external limiting membrane beneath the thickened OPL (red triangle) and thinning of outer nuclear layer; (d) infrared reflectance image showing hyperreflectance corresponding to the AMN lesion (white circle)



**Figure 2:** (a) Blue autofluorescence image of AMN lesion (yellow circle) showing an area of hyperautofluorescence interspersed with darker zones of hypoautofluorescence; (b) near-infrared autofluorescence image of AMN (yellow circle) showing hypoautofluorescence over the AMN lesion which is darker than the adjacent foveal and macular hyperautofluorescence

## References

1. Lee SY, Cheng JL, Gehrs KM, Folk JC, Sohn EH, Russell SR, *et al.* Choroidal features of acute macular neuroretinopathy via optical coherence tomography angiography and correlation with serial multimodal imaging. *JAMA Ophthalmol* 2017;135:1177-83.
2. Bhavsar KV, Lin S, Rahimy E, Joseph A, Freund KB, Sarraf D, *et al.* Acute macular neuroretinopathy: A comprehensive review of the literature. *Surv Ophthalmol* 2016;61:538-65.
3. Tan AC, Fleckenstein M, Schmitz-Valckenberg S, Holz FG. Clinical application of multicolor imaging technology. *Ophthalmologica* 2016;236:8-18.
4. Greenstein VC, Schuman AD, Lee W, Duncker T, Zernant J, Allikmets R. Near-infrared autofluorescence: Its relationship to short-wavelength autofluorescence and optical coherence tomography in recessive stargardt disease. *Invest Ophthalmol Vis Sci* 2015;56:3226-34.