

## Endodermal sinus tumor of vagina in infants

Smita Chauhan, Jitendra Singh Nigam,  
Pallavi Singh, Vatsala Misra,  
Brijesh Thakur

Department of Pathology M.L.N. Medical  
College Allahabad, Uttar Pradesh, India

### Abstract

Endodermal sinus tumor (or Yolk Sac tumor) of the vagina is a rare malignant germ-cell tumor which is seen exclusively in children younger than 3 years of age. We report two cases of endodermal sinus tumor of the vagina. In both cases no radiological investigation was done and serum alpha-fetoprotein was elevated. The histopathological examination of both the tumor masses revealed vaginal endodermal sinus tumor. Periodic-acid-Schiff stain with diastase showed diastase resistant hyaline globules. These findings confirmed the diagnosis of endodermal sinus tumor in both cases. Vaginal endodermal sinus tumor is both locally aggressive and capable of metastasis. The serum alpha-fetoprotein level is a useful marker for diagnosis and monitoring the recurrence of vaginal endodermal sinus tumor in infants. Early detection and therapy is important because of its aggressive nature and good response to chemotherapy.

### Introduction

Germ cell tumors (GCT) are relatively uncommon childhood tumors. Endodermal sinus tumor (EST) or Yolk Sac tumor (YST) forms the most common histological subtype of GCT in children. Affected individuals are almost exclusively infants, and all are younger than 3 years of age at presentation.<sup>1</sup> Extragonadal ESTs are very rare. The vagina is an extremely rare site for primary GCTs.<sup>2</sup> Aberrant migration of germ cells during early embryonic life has been implicated as a possibility of origin. Clinical presentation is with a polypoid vaginal mass, bloody discharge or sometimes even urinary retention if the bladder is compressed.<sup>3</sup> We report two cases of endodermal sinus tumor in infants, located in the vagina, which is a very rare site and serum alpha-fetoprotein level is elevated in both the cases.

### Case Report

The first patient is a three and half month old female child presented with a protruding mass through introitus and vaginal bleeding.

The second one is an eleven months old female infant presented with blood mixed vaginal discharge. On examination a fragile mass was found protruding through the posterior vaginal wall.

In both the cases no radiological investigation was done and serum alpha-fetoprotein (AFP) was elevated, 1582 IU/mL and 2200 IU/mL respectively.

Complete resection was not done and small pieces of tissue measuring 1.5×1.5 cm and 1.6×1.2 cm in size from Case-1 and Case-2 respectively were received. The histopathological examination of both the tumor masses showed tumor cells arranged in reticular and trabecular pattern in a loose meshwork of the spaces or channels (Figure 1A). The spaces were lined by primitive cells having clear cytoplasm, large hyperchromatic irregular nuclei and prominent nucleoli (Figure 1B). Characteristic Schiller-Duval bodies (rounded papillae containing a single central vessel and lined by columnar tumor cells) are also seen (Figure 1C). Periodic-acid-Schiff (PAS) stain with diastase showed diastase resistant hyaline globules (Figure 1D). These findings confirmed the diagnosis of Endodermal sinus tumor in both cases.

No other elements of germ cell tumors such as seminoma, choriocarcinoma, clear cell carcinoma, immature teratoma are seen in either of two cases. Immunohistochemical examination of AFP on tissue sections of both cases was not done because of lack of this facility. Both patients were referred to Oncologist but one patient (case 2) lost follow up. The patient (case 1) was taken up for surgery; there was no infiltration into posterior wall of the bladder and anterior wall of the rectum. A computed tomography scan could not be done but postoperative ultrasound did not reveal any residual mass. Patient received four courses of PEB (cisplatin, etoposide and bleomycin) regimen. Reduction of serum AFP to 43 ng/mL was detected after the third course of therapy. There is no evidence of recurrence at one year of follow-up.

### Discussion

Endodermal sinus tumor of the vagina is a rare, highly malignant GCT that exclusively involves children less than 3 years of age. Various histopathological subtypes of EST include reticular (microcystic), macrocystic, endodermal sinus type, papillary, solid, glandu-

Correspondence: Smita Chauhan, Department of Pathology M.L.N. Medical College Allahabad, Uttar Pradesh, India. Tel. +91.955.9597686. E-mail: drsmita01@gmail.com

Key words: yolk sac tumor, endodermal sinus tumor, vagina, germ cell tumor, alpha-fetoprotein.

Conflict of interests: the authors declare no potential conflicts of interests.

Received for publication: 30 May 2012.  
Revision received: 21 April 2013.  
Accepted for publication: 30 April 2013.

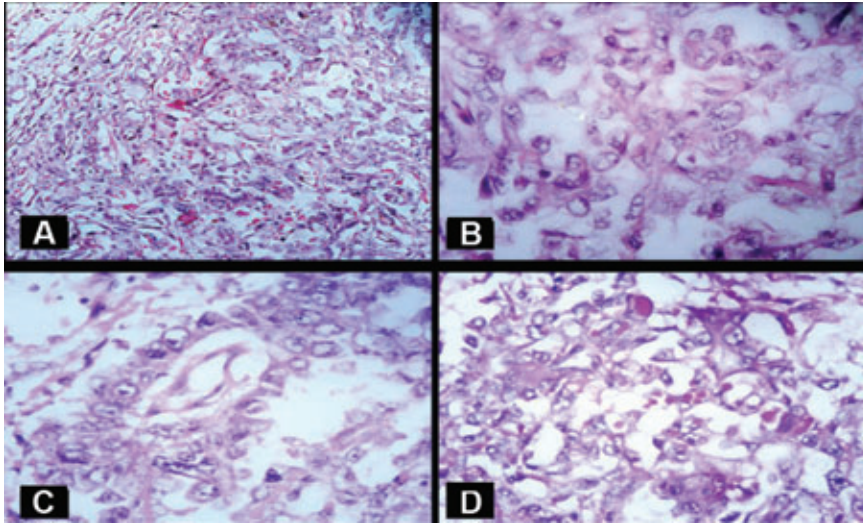
This work is licensed under a Creative Commons Attribution NonCommercial 3.0 License (CC BY-NC 3.0).

©Copyright S. Chauhan et al., 2013  
Licensee PAGEPress, Italy  
Rare Tumors 2013; 5:e22  
doi:10.4081/rt.2013.e22

lar, myxomatous, sarcomatoid, polyvesicular, hepatoid and parietal types. PAS stain can be used to stain the hyaline material and shows positivity which is resistant to digestion by diastase.<sup>4</sup>

The diagnosis is based on histological pattern, characteristic Schiller-Duval bodies, PAS stain positive diastase resistant hyaline globules and raised serum alpha-fetoprotein (AFP). The main entities in the differential diagnosis include embryonal rhabdomyosarcoma (sarcoma botryoides) on gross examination and clear cell carcinoma on microscopic examination. Embryonal rhabdomyosarcoma (sarcoma botryoides) is a common tumor of infancy however grossly it shows soft, polypoid growth with a grape-like configuration and on microscopy it shows subepithelial cambium layer with alternating edematous and cellular areas formed of cells ranging from small and primitive to those with definitive evidence of rhabdomyoblastic differentiation (cross-striations), which can be further confirmed by Phosphotungstic acid Haematoxylin (PTAH) stain. Clear cell carcinomas occurs in older women (>20 years), shows characteristic architectural patterns, and may be associated with adenosis.<sup>5</sup> Although immunostaining for AFP has traditionally been considered to support a diagnosis of EST, it is relatively nonspecific.<sup>6</sup> In most of the earlier case reports also, the diagnosis of EST was confirmed on the basis of histological features, presence of diastase resistant PAS stain positive hyaline globules and raised serum AFP.<sup>3,7</sup> ESTs are CK7, Leu-M1, and EMA negative, in contrast to clear cell carcinomas.<sup>6,8</sup>

The presence of serum tumor markers allows making a diagnosis by non-invasive means. It has



**Figure 1.** A) Tumor cells arranged in reticular pattern in loose meshwork of spaces or channels (Haematoxylin & Eosin x100); B) lining cells were polygonal to oval having hyperchromatic, vesicular nuclei with prominent nucleoli and clear cytoplasm (Haematoxylin & Eosin x100); C) section shows a Schiller-Duval body (Haematoxylin & Eosin x100); D) numerous intracellular as well as extracellular Periodic-acid-Schiff positive diastase resistant Hyaline globules. (Periodic-acid-Schiff x400).

been reported that AFP levels in patients with GCTs increase when the tumors contain EST elements, and that tumor volume is correlated with the AFP level in serum.<sup>9</sup> The serum AFP level is a useful marker for diagnosis and monitoring the recurrence of vaginal EST in infants. Vaginal EST is both locally aggressive and capable of metastasis. Because of the rarity of vaginal EST, its natural history is poorly understood and ideal management is not obvious. It is both locally aggressive and capable of metastasis via hematogenous and lymphatic pathways. Untreated patients have died within 2 to 4 months of presentation. Radical surgery leads to a loss of sexual and reproductive function. Long-term irradiation has secondary effects of sterility, aseptic necrosis of the femoral head, and abnormal growth of the pelvic bones.<sup>7</sup> Treatment consists of conservative surgery in combination with chemotherapy, with excellent prospects for long-term survival.<sup>10</sup> One patient reported here underwent partial vaginectomy and received four cycles of combination

chemotherapy with PEB. To allow preservation of sexual and reproductive function, chemotherapy as a sole modality of treatment for EST should be considered.<sup>11</sup>

## Conclusions

Endodermal sinus tumor is a highly malignant tumor. In the vagina it is very rare and thus may not be recognized early or may be inadvertently subjected to radical surgery. Early detection and therapy is important because of its aggressive nature and good response to chemotherapy. In our case, patient received four courses of PEB (cisplatin, etoposide and bleomycin) regimen after surgery. Reduction of serum AFP to 43 ng/mL was detected after the third course of therapy. There is no evidence of recurrence at one year of follow-up. Follow up of one patient was lost.

## References

1. Kumar V, Kini P, Vepakomma D, Basant M. Vaginal endodermal sinus tumor. *Indian J Pediatr* 2005;72:797-8.
2. Davidoff AM, Hebra A, Bunin N, et al. Endodermal sinus tumor in children. *J Pediatr Surg* 1996;31:1075-8.
3. Deshmukh C, Bakshi A, Bhagwat R, Kurkure P. Yolk Sac tumor of vagina. *Indian J Pediatr* 2005;72:367.
4. Nogales F, Talerman A, Kubik-Huch RA, et al. Germ cell tumors. In: Tavassoli FA, Devilee P, eds. *WHO classification of tumors: pathology and genetics of the breast and female genital organs*. Lyon: IARC Press; 2003. pp 165-166.
5. Malpica A. Vaginal neoplasia. In: Nucci MR, Oliva E, eds. *Gynaecologic pathology*. 1st edition. Philadelphia: Elsevier Churchill Livingstone; 2009. pp 134-135.
6. Zirker TA, Silva EG, Morris M, Ordóñez NG. Immunohistochemical differentiation of clear-cell carcinoma of the female genital tract and endodermal sinus tumor with the use of alpha-fetoprotein and Leu-M1. *Am J Clin Pathol* 1989;91:511-4.
7. Arora M, Shrivastav R, Jaiprakash M. A rare germ-cell tumor site: vaginal endodermal sinus tumor. *Pediatr Surg Int* 2002;18: 521-3.
8. Ramalingam P, Malpica A, Silva EG, et al. The use of cytokeratin 7 and EMA in differentiating ovarian yolk sac tumors from endometrioid and clear cell carcinomas. *Am J Surg Pathol* 2004;28:1499-505.
9. Arita N, Bitoh S, Ushio Y, et al. Primary pineal endodermal sinus tumor with elevated serum and CSF alpha-fetoprotein levels. *J Neurosurg* 1980;53:244-8.
10. Shinkoda Y, Tanaka S, Ijichi O, et al. Successful treatment of an endodermal sinus tumor of the vagina by chemotherapy alone: a rare case of an infant diagnosed by pathological examination of discharged tumor fragment. *Pediatr Hematol Oncol* 2006;23:563-9.
11. Lacy J, Capra M, Allen L. Endodermal sinus tumor of the infant vagina treated exclusively with chemotherapy. *J Pediatr Hematol Oncol* 2006;28:768-71.