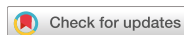

Research Article
Periodontal Science



Supraeruption as a consideration for implant restoration

OPEN ACCESS

Received: Dec 23, 2019

Revised: May 13, 2020

Accepted: Jun 5, 2020

*Correspondence:

Young-Taek Kim

Department of Periodontology, National Health Insurance Service Ilsan Hospital, 100 Ilsan-ro, Ilsandong-gu, Goyang 10444, Korea.

E-mail: youngtaek@nhimc.or.kr

Tel: +82-31-900-0625

Fax: +82-0303-3448-7138

Copyright © 2020. Korean Academy of Periodontology

This is an Open Access article distributed under the terms of the Creative Commons Attribution Non-Commercial License (<https://creativecommons.org/licenses/by-nc/4.0/>).

ORCID iDs

Bo-Ah Lee

<https://orcid.org/0000-0003-3586-4928>

Byoungheon Kim

<https://orcid.org/0000-0001-7808-6092>

Young-Taek Kim

<https://orcid.org/0000-0002-5132-5783>

Funding

This work was supported by the National Health Insurance Service (NHIS) of Korea.

Author Contributions

Conceptualization: Young-Taek Kim;

Formal analysis: Bo-Ah Lee; Investigation:

Byoungheon Kim; Methodology: Young-Taek

Kim; Project administration: Bo-Ah Lee;

Writing - original draft: Bo-Ah Lee; Writing -

review & editing: Young-Taek Kim.

Bo-Ah Lee , Byoungheon Kim , Young-Taek Kim

Department of Periodontology, National Health Insurance Service Ilsan Hospital, Goyang, Korea

ABSTRACT

Purpose: The aim of this study was to compare the prevalence, amount, and rate of supraeruption of the maxillary second molar according to sex, age, and history of periodontitis.

Methods: Data were collected retrospectively from the charts and panoramic radiographs of 65 patients who were scheduled to undergo implant placement at the site of the mandibular second molar. The amount of supraeruption of the maxillary second molar and the alveolar bone level of the neighboring teeth were measured on digital panoramic radiographs. The prevalence was evaluated in each group, and univariate and multivariate logistic regression analyses were used to identify factors influencing the prevalence of supraeruption. The amount and the rate of supraeruption were compared between pairs of groups using the Mann-Whitney *U* test. For all tests, *P* values <0.05 were considered to indicate statistical significance.

Results: Supraeruption occurred in 78% of the patients. The prevalence of supraeruption was affected by sex, age, and history of periodontitis. The mean amount of supraeruption was 0.91 mm and the mean rate of supraeruption was 0.14 mm/month. The amount and the rate of supraeruption showed no significant differences according to sex, age, or the distance from the cemento-enamel junction to the alveolar bone crest (*P*>0.05).

Conclusions: These results show that the amount of supraeruption on the maxillary second molar was similar to the thickness of the enamel on the occlusal surface. When a single implant is scheduled to be placed on the mandibular second molar, supraeruption of the antagonist should be considered.

Keywords: Clinical study; Dental implant; Tooth eruption; Tooth extraction

INTRODUCTION

Supraeruption of the opposing tooth is a challenge when restoring a missing tooth. Teeth continue to erupt slowly throughout life even after the occlusal plane has been approached [1], and the eruption rate can increase if the contact with opposing teeth is lost [2]. The loss of a posterior tooth can result in 3-dimensional changes in the position of the opposing tooth, such as supraeruption, rotation, and tipping [3,4]. Not all molars without opposing teeth overerupt, and the reported prevalence of supraeruption ranges from 70% to 85% [3,5].

Conflict of Interest

No potential conflict of interest relevant to this article was reported.

Excessive supraeruption of opposing teeth reduces the height available for a crown restoration. Implant restorations require an interocclusal space of at least 8 mm from the alveolar bone crest (ABC) [6]. An insufficient interocclusal space can reduce the retention of the implant crown, and even make prosthetic treatment impossible. It was reported that a low prosthetic abutment height was associated with marginal bone loss in dental implants [7]. Moreover, a previous study reported that the premolars adjacent to dental implants sometimes exhibit the symptoms of traumatic occlusion due to implant overloading [8]. In addition, some overerupted teeth may cause occlusal interference [9]. Occlusal interference may cause occlusal overload [10], which is considered to be a major cause of biomechanical complications [10-12].

These undesired outcomes can be avoided by applying additional treatments such as occlusal reduction with or without root canal therapy [13], orthodontic intrusion [14], or segmental osteotomy [15]. These treatments increase the cost and time needed for restoring a missing tooth, but it is possible to minimize those disadvantages by using a retainer after extraction in patients with a high risk of supraeruption.

There are reports in the literature on the prevalence and amount of supraeruption, but no study has investigated how rapidly supraeruption occurs, especially in patients requiring placement of a dental implant. Therefore, the aim of this study was to compare the prevalence, amount, and rate of supraeruption of the maxillary second molar according to sex, age, and history of periodontitis.

MATERIALS AND METHODS

Study design

This study evaluated supraeruption of the maxillary second molar after extraction of the opposing teeth. Patients who underwent implant placement at the site of the mandibular second molar between September 2008 and September 2016 and had panoramic radiographs before the extraction of the mandibular second molar and at the time of implant prosthesis delivery on the mandibular second molar were included. Data were collected retrospectively from their charts and panoramic radiographs.

The study protocol was reviewed and approved by the Ethics Commission of National Health Insurance Service Ilsan Hospital, Korea (NHIMC IRB No. 2018-04-015).

Data collection

The amount of supraeruption of the maxillary second molar and the alveolar bone level of the teeth adjacent to the maxillary second molar were measured by a single calibrated examiner (BH) on panoramic radiographs using imaging software and a measurement tool that was equipped with the imaging software (Centricity Web PACS Viewer version 3.0, GE Healthcare, Chicago, IL, USA). Intraexaminer reproducibility was evaluated using intraclass correlation analysis of the measurements from 10 patients, which revealed an intraclass correlation coefficient of 0.97 ($P < 0.05$).

The amount of supraeruption was measured as follows (Figure 1). The reference plane was the plane connecting the cusp tips of the maxillary first and second premolars and the first molar. The vertical distance from the highest cusp tip of the maxillary second molar to

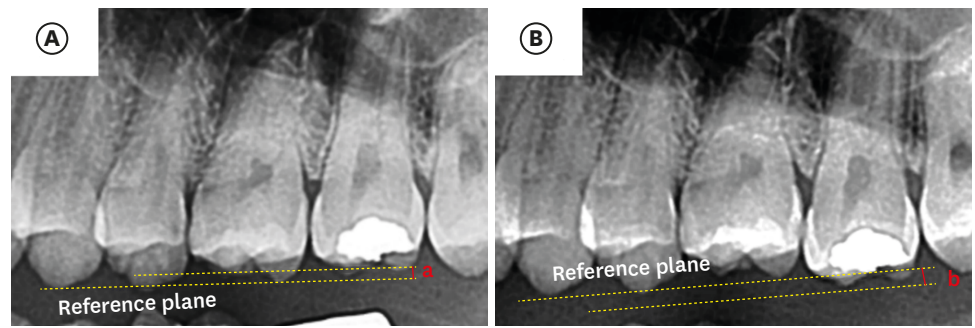


Figure 1. Radiographs with measurements obtained (A) before and (B) after extraction of the mandibular second molar. The vertical distance from the highest cusp tip of the maxillary second molar to the plane connecting the cusp tips of the maxillary first and second premolars and the first molar was measured on panoramic radiographs obtained before extraction and immediately after implant placement. The measured value was expressed as a negative value when the cusp tip of the maxillary second molar was positioned apical to the reference plane and as a positive value when it was positioned coronal to the reference plane.

the reference plane was measured. The measured value was expressed as a negative value when the cusp tip of the maxillary second molar was positioned apical to the reference plane and as a positive value when it was positioned coronal to the reference plane. The first measurement was made on panoramic radiographs obtained before tooth extraction (Figure 1A) and the second measurement was made on radiographs obtained at the time of implant prosthesis delivery (Figure 1B). The second measurement was adjusted considering the height of the maxillary second molar, which was measured from the mesiobuccal cusp tip to the mesiobuccal root apex. The amount of supraeruption was calculated by subtracting the first measurement (a in Figure 1A) from the second measurement (b in Figure 1B). The average rate of supraeruption was calculated by dividing the amount of supraeruption by the period between the first and second radiographs.

The alveolar bone level of the teeth adjacent to the maxillary second molar was evaluated and used as a reference to determine the history of periodontitis. The distances from the cemento-enamel junction (CEJ) to the ABC on the mesial and distal sides of the maxillary first and second premolars and the first molar were measured on panoramic radiographs obtained before extraction. The mean value of all 6 measurements was calculated.

Sex and age were also recorded. Patients' anonymity was protected by assigning a random number to each person. Chart reviews were performed by another examiner (BA).

Statistical analysis

Data were evaluated using SPSS version 23 (IBM Corp., Armonk, NY, USA). For the statistical analysis, participants were divided into pairs of groups according to sex (30 women and 35 men), age (48 subjects aged <60 years and 17 subjects aged ≥60 years), and the distance from the CEJ to the ABC (<2 mm in 32 subjects and ≥2 mm in 33 subjects).

The prevalence of supraeruption was evaluated in each group, and univariate and multivariate logistic regression analyses were used to identify factors influencing the prevalence of supraeruption ($P < 0.05$). The Kolmogorov-Smirnov test demonstrated that the data for the amount and the rate of supraeruption in pairs of groups did not show a normal distribution ($P < 0.05$). The amount and the rate of supraeruption were compared between pairs of groups using the Mann-Whitney *U* test ($P < 0.05$).

Table 1. Prevalence of supraeruption (n=65) and the results of logistic regression analysis

Variable	Prevalence (%)	Univariate		Multivariate	
		OR (95% CI)	P	OR (95% CI)	P
Sex		2.889 (1.354–6.165)	0.006 ^{a)}	2.084 (0.752–5.772)	0.158
Female (n=30)	80.00				
Male (n=35)	77.14				
Age (yr)		3.250 (1.060–9.967)	0.039 ^{a)}	2.649 (1.117–6.279)	0.027 ^{a)}
<60 (n=48)	79.17				
≥60 (n=17)	76.47				
CEJ-to-ABC distance		3.125 (1.410–6.928)	0.005 ^{a)}	1.245 (0.459–3.379)	0.667
<2 mm (n=32)	81.25				
≥2 mm (n=33)	75.76				

OR: odds ratio, CI: confidence interval, CEJ: cementoamel junction, ABC: alveolar bone crest.

^{a)}P<0.05.

RESULTS

This study evaluated supraeruption of the maxillary second molar after extraction of the opposing teeth in 65 patients (30 women and 35 men). The mean age of the patients was 53.88 years (range, 22–77 years). The mean period from the first radiograph to the final radiograph was 7.21 months (range, 1.5–45 months) and most patients (57 of 65 patients) received an implant restoration within 12 months.

Supraeruption occurred in 51 (78%) of the patients. Table 1 lists the prevalence of supraeruption in groups according to sex, age, and the distance from the CEJ to the ABC. The prevalence of supraeruption was higher in women, patients aged <60 years, and patients with a distance from the CEJ to the ABC of <2 mm. Univariate logistic regression analysis revealed that sex, age, and the distance from the CEJ to the ABC were significantly predictive of the prevalence of supraeruption ($P<0.05$), with odds ratios of 2.889, 3.250, and 3.125 for sex, age, and the CEJ-to-ABC distance, respectively. Since these variables all showed a P value <0.05, they were included in the multivariate logistic regression analysis, in which age was the only variable showing significance.

The mean amount and the mean rate of supraeruption were evaluated in subjects showing supraeruption (n=51). The mean amount was 0.91 mm (range, 0.5–1.95 mm) and the mean rate of supraeruption was 0.14 mm/month (range, 0.03–0.39 mm/month). No patients showed ≥2 mm of supraeruption.

As presented in Table 2, the amount and rate of supraeruption showed different tendencies. No significant between-group differences in the amount and rate of supraeruption according to sex, age, and the distance from the CEJ to the ABC ($P>0.05$). However, the amount of supraeruption tended to be higher in male patients, those aged <60 years, and those with a CEJ-to-ABC distance of <2 mm, and the rate tended to be higher in male patients, those aged ≥60 years, and those with a CEJ-to-ABC distance of ≥2 mm.

In addition to these results, the subjects with a period between the first and second measurement of less than 6 months (n=29) were analyzed separately. In this subgroup, the mean amount of supraeruption was 0.71 mm (range, 0.5–1.06 mm) and the mean rate of supraeruption was 0.22 mm/month (range, 0.13–0.39 mm/month).

Table 2. Amount and rate of supraeruption (n=51)

Variable	Amount (mm)	P	Rate (mm/mon)	P
Sex		0.357		0.987
Female (n=24)	0.78±0.20		0.11±0.07	
Male (n=27)	0.99±0.44		0.13±0.10	
Age (yr)		0.589		0.737
<60 (n=38)	0.92±0.43		0.11±0.08	
≥60 (n=13)	0.91±0.10		0.15±0.11	
CEJ-to-ABC distance		0.828		0.664
<2 mm (n=26)	0.94±0.33		0.12±0.08	
≥2 mm (n=25)	0.88±0.46		0.17±0.11	

Data are shown as mean±standard deviation. Statistical significance was determined using the Mann-Whitney *U* test. CEJ: cementoenamel junction, ABC: alveolar bone crest.

DISCUSSION

The loss of a posterior tooth can result in positional changes of the opposing tooth such as rotation, tipping, and supraeruption [3,4]. Some studies have investigated the prevalence or the degree of supraeruption [2-5], but no previous research has evaluated the rate of supraeruption. This study measured changes in the vertical location of the maxillary second molars before and after extracting the opposing teeth, and used the recorded time period between these measurements to calculate the rate of supraeruption.

This study investigated maxillary second molars. It has been reported that supraeruption occurs more frequently in the maxilla than the mandible [16]. Most patients included in the present study were scheduled to undergo implant restoration within a year, during which period the mandibular teeth would not exhibit measurable supraeruption. In addition, the maxillary first molars were not selected in this study because the teeth adjacent to the missing opposing teeth may act as an occlusal stop.

The prevalence of supraeruption was 78% in this study, which is consistent with other studies that have reported prevalence rates ranging from 70% to 85% [3,5]. However, none of our patients showed >2 mm of supraeruption, whereas previous reports have stated that 21%–24% of unopposed teeth showed >2 mm of supraeruption [3,16]. A possible reason for this discrepancy is the short period of the absence of the opposing teeth in the present study (mean, 7.21 months) because the patients were already scheduled to undergo implant restoration.

The mean amount and rate of supraeruption were 0.91 mm and 0.14 mm/month, respectively, and 0.71 mm and 0.22 mm/month within 6 months after extraction of the opposing teeth. These results suggest that supraeruption of unopposed teeth occurs mostly within 6 months after extraction of the opposing teeth and then slows down.

Age, attachment loss, and the arch have been reported to be associated with supraeruption [17]. This study revealed that the prevalence of supraeruption was affected by sex, age, and the distance from the CEJ to the ABC. Women had a higher prevalence of supraeruption than men. However, the amount and the rate of supraeruption tended to be higher in men, although those differences did not show statistical significance. The effect of sex on supraeruption is controversial. Although some studies have found no difference in the prevalence of supraeruption between male and female patients [18], others have reported a higher prevalence of supraeruption in males [5]. The mean age of the subjects in the present study was 55 years, meaning that most of the included women were menopausal. Considering

that supraeruption is based on the apposition of bone in the apical region of the teeth, it is possible that the hormonal changes associated with menopause can affect the amount and the rate of supraeruption in women.

The prevalence of supraeruption was higher in subjects younger than 60 years. Craddock *et al.* [5] also reported that supraeruption due to periodontal growth was more prevalent in younger patients. However, the amount and the rate did not show significant differences according to age.

The present subjects were divided into 2 groups according to the distance from the CEJ to the ABC. We set the reference point at 2 mm, because the normal CEJ-to-ABC distance is 1.08 mm [19], whereas patients with periodontitis or a history of periodontitis show alveolar bone loss [20]. The prevalence of supraeruption was lower in subjects with a CEJ-to-ABC distance of <2 mm than in subjects with a distance of ≥ 2 mm, but there was no statistically significant difference in the amount and the rate of supraeruption between the 2 groups. In contrast, Christou and Kiliaridis [4] reported that periodontally affected unopposed molars presented more prominent vertical displacement over 10 years than periodontally healthy teeth. Periodontitis is characterized by a breakdown of the balance between the activity of osteoclasts and osteoblasts [21], which could affect the bone remodeling around unopposed teeth. Similarly, the rate of supraeruption tended to be higher in subjects with a CEJ-to-ABC distance of ≥ 2 mm in this study. In patients with a history of periodontitis, supraeruption seems to initiate slowly then progress rapidly.

The mean rate of supraeruption was 0.14 mm/month in all subjects and 0.22 mm/month within 6 months after extraction. The thickness of the enamel on the occlusal surface of teeth is typically 1.0–1.5 mm. These findings suggest that the amount of supraeruption cannot be adjusted only by enameloplasty when the opposing teeth are missing for more than 1 year. Conventional implant placement requires a postextraction healing period of at least 6 months [22], although an early implant placement protocol has shown similar clinical outcomes to the conventional one [23]. In addition, the conventional guidelines also require a period of 3–6 months prior to prosthesis loading [22], although it has also been reported that immediate or early loading of dental implants can produce acceptable clinical outcomes [24,25]. In summary, it takes 9–12 months to complete an implant prosthesis after tooth extraction, and this period can increase when guided bone regeneration or sinus floor elevation needs to be performed. Therefore, when implant placement is expected after tooth extraction, additional pretreatment is needed to prevent supraeruption of the opposing teeth. A fixed retainer or a removable retainer can be recommended. Because the rate of supraeruption tended to be higher in men, patients aged ≥ 60 years, and those with a history of periodontitis, these patients require more attention.

The main limitation of this study is that the measurements were performed on panoramic radiographs due to the use of retrospectively collected data. Studies have reported distortion and magnification of radiographic images [26–28]. Fortunately, though, head positioning affects the magnification of vertical distances less than that of horizontal distances [26]. This error was minimized in this study by setting the reference point at a constant position as much as possible in the pre-extraction and postextraction radiographs, and the measurements were performed using imaging software and a software measurement tool. Another limitation is that only vertical displacement was measured. The extraction of opposing teeth can lead to drifting, tipping, and supraeruption [29]. However, since the

measurements were performed on panoramic radiographs in this study, 3-dimensional changes could not be measured. In addition, the number of subjects in each group was not sufficient to generalize the results of this study.

This study showed that the amount of supraeruption on the maxillary second molar was similar to the thickness of the enamel on the occlusal surface. When a single implant is scheduled to be placed on the mandibular second molar, supraeruption of the antagonist should be considered. Based on our findings, it can be suggested that an additional pretreatment procedure to prevent supraeruption of the antagonist, such as a retainer, can help reduce the difficulties that can occur when a missing tooth is replaced by an implant prosthesis. Further study is necessary to evaluate the supraeruption of teeth at other sites or multiple teeth.

REFERENCES

1. Carlson H. Studies on the rate and amount of eruption of certain human teeth. *Am J Orthod Oral Surg* 1944-1945;42:78-91.
[PUBMED](#) | [CROSSREF](#)
2. Compagnon D, Woda A. Supraeruption of the unopposed maxillary first molar. *J Prosthet Dent* 1991;66:29-34.
[PUBMED](#) | [CROSSREF](#)
3. Kiliaridis S, Lyka I, Friede H, Carlsson GE, Ahlqwist M. Vertical position, rotation, and tipping of molars without antagonists. *Int J Prosthodont* 2000;13:480-6.
[PUBMED](#)
4. Christou P, Kiliaridis S. Three-dimensional changes in the position of unopposed molars in adults. *Eur J Orthod* 2007;29:543-9.
[PUBMED](#) | [CROSSREF](#)
5. Craddock HL, Youngson CC, Manogue M, Blance A. Occlusal changes following posterior tooth loss in adults. Part 1: a study of clinical parameters associated with the extent and type of supraeruption in unopposed posterior teeth. *J Prosthodont* 2007;16:485-94.
[PUBMED](#) | [CROSSREF](#)
6. Misch CE, Goodacre CJ, Finley JM, Misch CM, Marinbach M, Dabrowsky T, et al. Consensus conference panel report: crown-height space guidelines for implant dentistry-part 1. *Implant Dent* 2005;14:312-8.
[PUBMED](#) | [CROSSREF](#)
7. Lee BA, Kim BH, Kweon HHI, Kim YT. The prosthetic abutment height can affect marginal bone loss around dental implants. *Clin Implant Dent Relat Res* 2018;20:799-805.
[PUBMED](#) | [CROSSREF](#)
8. Lee JH, Kweon HH, Choi SH, Kim YT. Association between dental implants in the posterior region and traumatic occlusion in the adjacent premolars: a long-term follow-up clinical and radiographic analysis. *J Periodontal Implant Sci* 2016;46:396-404.
[PUBMED](#) | [CROSSREF](#)
9. Craddock HL, Youngson CC. A study of the incidence of overeruption and occlusal interferences in unopposed posterior teeth. *Br Dent J* 2004;196:341-8.
[PUBMED](#) | [CROSSREF](#)
10. Kim Y, Oh TJ, Misch CE, Wang HL. Occlusal considerations in implant therapy: clinical guidelines with biomechanical rationale. *Clin Oral Implants Res* 2005;16:26-35.
[PUBMED](#) | [CROSSREF](#)
11. Fu JH, Hsu YT, Wang HL. Identifying occlusal overload and how to deal with it to avoid marginal bone loss around implants. *Eur J Oral Implantology* 2012;5 Suppl:S91-103.
[PUBMED](#)
12. Sheridan RA, Decker AM, Plonka AB, Wang HL. The role of occlusion in implant therapy: a comprehensive updated review. *Implant Dent* 2016;25:829-38.
[PUBMED](#) | [CROSSREF](#)
13. Zarb GA. *Prosthodontic treatment for partially edentulous patients*. St. Louis (MO): Mosby; 1978.

14. Baumgaertel S, Smuthkochorn S, Palomo JM. Intrusion method for a single overerupted maxillary molar using only palatal mini-implants and partial fixed appliances. *Am J Orthod Dentofacial Orthop* 2016;149:411-5.
[PUBMED](#) | [CROSSREF](#)
15. Mopsik ER, Buck RP, Connors JO, Watts LN. Surgical intervention to reestablish adequate intermaxillary space before fixed or removable prosthodontics. *J Am Dent Assoc* 1977;95:957-60.
[PUBMED](#) | [CROSSREF](#)
16. Lindskog-Stokland B, Hansen K, Tomasi C, Hakeberg M, Wennström JL. Changes in molar position associated with missing opposed and/or adjacent tooth: a 12-year study in women. *J Oral Rehabil* 2012;39:136-43.
[PUBMED](#) | [CROSSREF](#)
17. Craddock HL, Youngson CC, Manogue M, Blance A. Occlusal changes following posterior tooth loss in adults. Part 2. Clinical parameters associated with movement of teeth adjacent to the site of posterior tooth loss. *J Prosthodont* 2007;16:495-501.
[PUBMED](#) | [CROSSREF](#)
18. Petridis HP, Tsiggos N, Michail A, Kafantaris SN, Hatzikyriakos A, Kafantaris NM. Three-dimensional positional changes of teeth adjacent to posterior edentulous spaces in relation to age at time of tooth loss and elapsed time. *Eur J Prosthodont Restor Dent* 2010;18:78-83.
[PUBMED](#)
19. Gargiulo AW, Wentz FM, Orban B. Dimensions and relations of the dentogingival junction in humans. *J Periodontol* 1961;32:261-7.
[CROSSREF](#)
20. Papananou PN, Sanz M, Buduneli N, Dietrich T, Feres M, Fine DH, et al. Periodontitis: consensus report of workgroup 2 of the 2017 world workshop on the classification of periodontal and peri-implant diseases and conditions. *J Periodontol* 2018;89 Suppl 1:S173-82.
[PUBMED](#) | [CROSSREF](#)
21. Silva N, Abusleme L, Bravo D, Dutzan N, Garcia-Sesnich J, Vernal R, et al. Host response mechanisms in periodontal diseases. *J Appl Oral Sci* 2015;23:329-55.
[PUBMED](#) | [CROSSREF](#)
22. Adell R, Lekholm U, Rockler B, Brånemark PI. A 15-year study of osseointegrated implants in the treatment of the edentulous jaw. *Int J Oral Surg* 1981;10:387-416.
[PUBMED](#) | [CROSSREF](#)
23. Bassir SH, El Kholy K, Chen CY, Lee KH, Intini G. Outcome of early dental implant placement versus other dental implant placement protocols: a systematic review and meta-analysis. *J Periodontol* 2019;90:493-506.
[PUBMED](#) | [CROSSREF](#)
24. Gallucci GO, Hamilton A, Zhou W, Buser D, Chen S. Implant placement and loading protocols in partially edentulous patients: a systematic review. *Clin Oral Implants Res* 2018;29 Suppl 16:106-34.
[PUBMED](#) | [CROSSREF](#)
25. Huynh-Ba G, Oates TW, Williams MAH. Immediate loading vs. early/conventional loading of immediately placed implants in partially edentulous patients from the patients' perspective: a systematic review. *Clin Oral Implants Res* 2018;29 Suppl 16:255-69.
[PUBMED](#) | [CROSSREF](#)
26. Pfeiffer P, Bewersdorf S, Schmage P. The effect of changes in head position on enlargement of structures during panoramic radiography. *Int J Oral Maxillofac Implants* 2012;27:55-63.
[PUBMED](#)
27. Flores-Mir C, Rosenblatt MR, Major PW, Carey JP, Heo G. Measurement accuracy and reliability of tooth length on conventional and CBCT reconstructed panoramic radiographs. *Dental Press J Orthod* 2014;19:45-53.
[PUBMED](#) | [CROSSREF](#)
28. Yim JH, Ryu DM, Lee BS, Kwon YD. Analysis of digitalized panorama and cone beam computed tomographic image distortion for the diagnosis of dental implant surgery. *J Craniofac Surg* 2011;22:669-73.
[PUBMED](#) | [CROSSREF](#)
29. Kaplan P. Drifting, tipping, supraeruption, and segmental alveolar bone growth. *J Prosthet Dent* 1985;54:280-3.
[PUBMED](#) | [CROSSREF](#)