

Metastatic adenocarcinoma of the cervix presenting as a choroidal mass: A case report and review of literature of cervical metastases to the eye

Akshay Gopinathan Nair^{1,2,3}, Haresh T Asnani^{1,3},
Vinod C Mehta³, Siddharth V Mehta³,
Rima S Pathak⁴

Cervical cancer is the most common cancer among females in India. Cervical cancer usually spreads by local extension and through the lymphatic drainage to the lymph nodes. Hematogenous spread, the mechanism responsible for distant metastases, is rarely seen in cervical malignancies. In this

communication, we report a case of a 45-year-old woman who presented with unilateral decrease in vision of 3 months duration. She was found to have a serous retinal detachment with underlying diffuse, subretinal yellowish-cream colored infiltrates in the right eye, suspicious of choroidal metastases. Systemic evaluation showed disseminated systemic metastases arising from a primary adenocarcinoma of the cervix. In this communication, we review all the documented cases of metastases to the eye and adnexa arising from cervical cancer and their clinical characteristics. Unilateral choroidal metastasis arising from an adenocarcinoma of the cervix is extremely rare with only one previous documented case. Although uncommon, choroidal metastasis may be the presenting feature of primary cervical malignancy. Furthermore, cervical malignancy must be ruled out in women who present with orbital or choroidal metastases arising from unknown primary.

Key words: Adenocarcinoma, cervix cancer, choroidal metastasis, granuloma, metastases, metastatic cervical cancer, orbital metastasis

The most common malignancy in women worldwide is breast cancer, followed by cervical cancer.^[1] However, cervical cancer is the most common cancer in Indian women.^[2] Cervical cancer commonly spreads by local extension and also through the lymphatic drainage to the retroperitoneal lymph nodes.

This is an open access article distributed under the terms of the Creative Commons Attribution-NonCommercial-ShareAlike 3.0 License, which allows others to remix, tweak, and build upon the work non-commercially, as long as the author is credited and the new creations are licensed under the identical terms.

For reprints contact: reprints@medknow.com

Cite this article as: Nair AG, Asnani HT, Mehta VC, Mehta SV, Pathak RS. Metastatic adenocarcinoma of the cervix presenting as a choroidal mass: A case report and review of literature of cervical metastases to the eye. Indian J Ophthalmol 2015;63:674-8.

Access this article online	
Quick Response Code:	Website: www.ijo.in
	DOI: 10.4103/0301-4738.169792

¹Advanced Eye Hospital and Institute, Navi Mumbai, ²Aditya Jyot Eye Hospital, ³Mehta Eye Clinic Pvt. Ltd., ⁴Tata Memorial Cancer Hospital, Mumbai, Maharashtra, India

Correspondence to: Dr. Akshay Gopinathan Nair, Ophthalmic Plastic Surgery and Ocular Oncology Services, Advanced Eye Hospital and Institute, 30, The Affaires, Sector 17, Sanpada, Navi Mumbai - 400 705, Maharashtra, India. E-mail: akshaygn@gmail.com

Manuscript received: 19.03.15; Revision accepted: 10.06.15

Hematogenous spread, which is the mechanism responsible for distant metastases, is rare and is seen in only 12% of the cases of cervical malignancies with the typical sites being liver, lung, and bone.^[3] Eye metastases from cervical cancer are extremely rare but are known to occur; the orbit, extraocular muscles, choroid, iris and the subconjunctival tissue being the reported sites of metastatic lesions.^[1,4-14] Here, we describe the case of a 45-year-old female in whom a unilateral choroidal metastasis was the presenting feature of disseminated adenocarcinoma of the cervix. We also review the available literature on ocular and adnexal metastasis.

Case Report

A 45-year-old lady presented with complaints of diminished vision for distance and near in the right eye for the past 3 months. She had no other ocular complaints. On examination, the best-corrected visual acuity was counting fingers at 2 m in the right eye and 20/20 N6 in the left eye. Anterior segment evaluation, intraocular pressures, and ocular motility were normal in both eyes. No proptosis was noted. Right eye fundus showed a serous retinal detachment with underlying diffuse, subretinal yellowish-cream colored infiltrates whereas the left eye was normal [Fig. 1a]. The infiltrates were largely situated on and around the posterior pole with the periphery being uninvolved. The vitreous cavity was clear with no signs of inflammation. Fundus fluorescein angiography showed hypofluorescence during the arterial phase and progressive hyperfluorescence during the subsequent phase. Pin-point discrete leakages were seen from the multiple lesions in the late phase along with disc leakage [Fig. 1b]

A clinical diagnosis of choroidal metastasis was made, and a detailed systemic history was elicited in order to localize a primary tumor. Her systemic history was significant: She gave a history of frequent headaches and a six month history of menorrhagia. A metastatic screening in the form of ultrasound of the abdomen, liver function tests, serum lactate dehydrogenase, and a gynecological consult were requested. Gynecological examination revealed

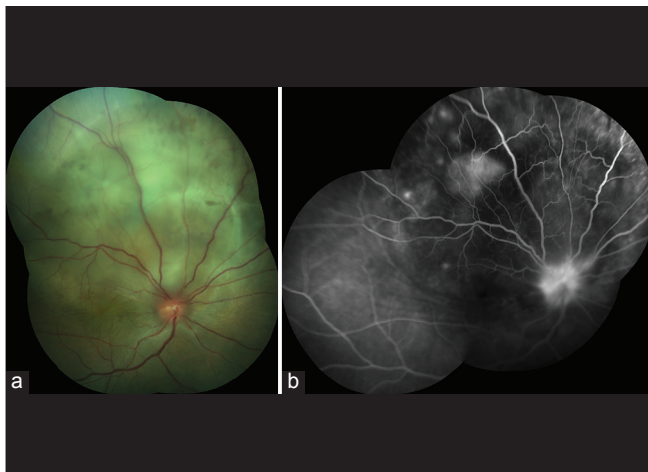


Figure 1: (a) Fundus photograph of the right eye showing serous retinal detachment with underlying choroidal, diffuse, yellowish-cream colored infiltrates. (b) Composite image of the fluorescein angiogram in the late phase demonstrating hyperfluorescence along with pin-point discrete leakages from the choroidal masses

an ulcerative mass arising from the cervix measuring approximately 4 cm × 4 cm × 3.5 cm, which bled on touch. A biopsy of the mass was performed which confirmed the diagnosis of poorly differentiated adenocarcinoma of the cervix with perivascular and perineural invasion. High resolution computed tomography (CT) scans of the chest showed multiple pleuroparenchymal metastatic nodules [Fig. 2a and b]. Positron emission tomography CT-(PET-CT) scan was performed which showed a bulky uterine cervix with increased metabolic activity. Multiple, hypermetabolic enhancing right supraclavicular, retropectoral, and mediastinal lymph nodes were noted. Multiple, hypermetabolic pleuroparenchymal lung nodules were also seen [Fig. 2c]. Hypermetabolic erosive lesions were seen involving the left parietal skull and a hypermetabolic lytic lesion seen in the subtrochanteric shaft of the left femur. A diagnosis of the International Federation of Gynecology and Obstetrics (FIGO) Stage IVb (American Joint Committee on Cancer staging-T3a N1 M1) adenocarcinoma of the cervix was made. In view of disseminated metastasis, she was advised for palliative chemotherapy and whole body radiation. She, however, declined treatment and succumbed to respiratory complications 2 months after diagnosis.

Discussion

A database search was performed on PubMed for ophthalmic metastasis of cervical cancer using the relevant search phrases. All relevant English language articles were extracted, with reference lists of the articles reviewed for applicable articles. In cases of non-English language articles, if the abstract was translated into English, the article was referenced as (abstract only) in the citation.

Bloch and Gartner, who had described metastasis to the eye and orbit from various primary tumors, reported a single case of metastatic cervical cancer. However, the details of the case, the precise site of the lesion, laterality, histopathological subtype, treatment, and outcome were not specified.^[15]

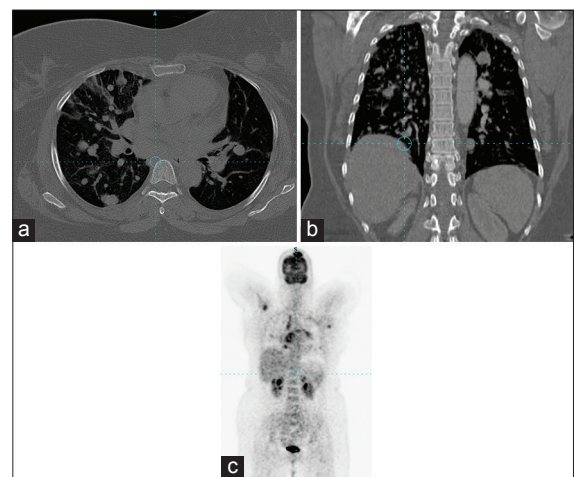


Figure 2: Axial (a) and coronal (b) slices of high-resolution computed tomography images of the chest demonstrate multiple bilateral randomly distributed metastatic nodules of varying sizes. (c) A positron emission tomography image showing hyper metabolic spots in the lungs, right supraclavicular lymph node and brain suggesting disseminated metastases

Table 1: The salient findings of available reports of cervical cancer with ocular and adnexal metastases

Author/year of publication	Age	OD/OS	Vision	Presenting symptoms	Location of metastasis	Primary tumor subtype	Staging of tumor prior to diagnosis of ocular metastases*	Other sites of metastases	Was ocular metastases the presenting feature of cervical cancer?	Treatment	Final outcome	Duration between diagnosis of ocular metastasis and death
Hertzanu <i>et al.</i> /1987	44	OD NA	NA	Proptosis, diplopia, blindness	Orbit (intraconal + extraconal mass)	Squamous cell carcinoma - Cervix	PU	None	Yes	Chemotherapy	NA	NA
Kurosawa <i>et al.</i> /1987	54	OD	20/100	Reduced vision, pain	Iris	Squamous cell carcinoma - Cervix	IV B	Lung	No	Radiation	DOD	NA
Wiegel <i>et al.</i> /1995	25	OS	NA	Reduced vision	Choroid	Adenocarcinoma - Cervix	I B	Lung	No	Chemotherapy, radiation	NA	NA
Ortiz <i>et al.</i> /1995	28	OD	20/20	Conjunctival mass	Subconjunctival tissue	Squamous cell carcinoma - Cervix	IV B	Lung	No	Chemotherapy	DOD	4 months
Lee <i>et al.</i> /1997	46	OS	20/80	Proptosis	Orbit (lateral orbital wall)	Squamous cell carcinoma - Cervix	II B	None	No	Radiation	DOD	4 months
Inoue <i>et al.</i> /2000	55	OU	20/20	Reduced vision	Choroid - both eyes	Squamous cell carcinoma - Cervix	III B	Lung, cerebellum	No	Chemotherapy, radiation	DOD	3 months
McCulley <i>et al.</i> /2002	29	OD	20/20	Proptosis, diplopia	Orbit (intraconal mass)	Subtype not known/ presumed cervical	NA	Left femur, spine, liver	No	Chemotherapy, radiation	DOD	NA
Park <i>et al.</i> /2005	57	OD	NPL	Proptosis, blindness	Orbit (intraconal mass)	Adenocarcinoma/ cervical origin confirmed by HPV typing	I B	Supraclavicular, submandibular nodes	No	Chemotherapy	DOD	NA
Gosslee <i>et al.</i> /2009	36	OS	20/30	Ptosis, swelling, pain	Orbit (superolateral orbital wall)	Squamous Cell Carcinoma - Cervix	II B	Right supraclavicular lymph node	No	Chemotherapy, radiation, surgery	DOD	3 months
Singh <i>et al.</i> /2009	50	OS	20/80	Diplopia	Orbit (medial orbital wall, medial canthus)	Squamous cell carcinoma - Cervix	PU	None	Yes	Chemotherapy, radiation	NA	NA
Sareen <i>et al.</i> /2012	59	OS	20/20	Proptosis, epiphora, headache	Orbit (left lateral rectus)	Squamous cell carcinoma - Cervix	III A	Lung, liver, adrenals, bone, and scalp	No	Radiation	DOD	4 months
Shibeeb <i>et al.</i> /2014	52	OU	CF at 1 m	Reduced vision	Choroid - Both eyes	Squamous cell carcinoma - Cervix	PU	Liver, bone	Yes	Radiation	DOD	3 months
Current case	45	OD	CF at 1 m	Reduced vision	Choroid	Adenocarcinoma - Cervix	PU	Lung, supraclavicular nodes, bones	Yes	None	DOD	2 months

*If staging was not mentioned, it was arrived at on the basis of the described clinical picture. The cases reported by Bloch and Gartner, and Ferry and Font have not been included in this table and subsequent analysis since details of those cases were not available. NA: Not available, OD: Oculus dexter (right eye), OS: Oculus sinister (left eye), NPL: No perception of light, DOD: Died of disease, PU: Previously undiagnosed, HPV: Human papillomavirus

Similarly, Ferry and Font, too in their series of 227 cases of ophthalmic metastasis, have reported that 4 cases of orbital metastasis in which the primary tumor was not identified could be cervical in origin.^[16]

In literature, 12 cases of documented cervical cancer metastasizing to the eye have been reported; our case being the 13th.^[1,4-14] The most common site for eye metastases was the orbit—it was seen in 53.84% (7/13) cases. This was closely followed by the choroid in 30.76% (4/13) cases; although 1 case had bilateral choroidal involvement.^[9] It is unusual that the orbit was involved in more cases as compared to the choroid. The choroid represents a high flow vasculature system—where metastatic cells that have been disseminated from tumors elsewhere in the body can find a suitable and receptive environment for growth.^[16,17] Therefore, choroidal metastasis is the most common intraocular tumour found among adults.^[17] In addition, uveal metastases outnumber orbital metastases by a ratio of 8 to 1.^[18] Iris and subconjunctival metastases from cervical primary were reported in 1 case each (7.69%).^[5,7]

The outcome of metastatic cervical cancer is regarded to be poor.^[19] The mean survival period after diagnosis of ocular and/or adnexal metastases from cervical cancer in those cases where data was available, was 3.28 months (range: 2–4 months; $n = 7$) indicating that metastasis to the eye usually foreshadow an ominous clinical course. This is lesser than 9–10 months that is, the reported average survival after diagnosis with uveal metastasis and 12–18 months in orbital metastasis in general.^[18,20] Among all documented cases of cervical metastases to the eye, lungs were the most common site of concurrent metastatic lesion with 46.15% (6/13) of the cases; followed by skeletal lesions which was seen in 30.76% (4/13) cases. Only in 3 cases, it was noted that ocular metastasis was the only metastatic lesion present. However, in these cases; details of the standard metastatic screening protocols and findings of PET-CT have not been mentioned. Therefore, it is possible that other metastatic sites could have been missed. In 4 cases including ours, the metastases caused visual complaints that prompted them to seek medical advice; and eventually led to the diagnosis of cervical cancer. It must be noted that these numbers are too few to indicate a predictable pattern. In a review of patients dying from malignancy, 8% displayed choroidal metastases on autopsy.^[15] Given the high number of cervical cancer cases, it is entirely plausible that choroidal metastases due to cervical malignancies are under-reported. The details of all available cases of documented ocular and adnexal metastasis arising from cervical primary malignancy are summarized in Table 1.

Treatment in cases of metastatic cervical cancer is largely palliative. Most systemic chemotherapy regimes are cisplatin-based.^[19] Local radiation to sites harboring metastasis helps to alleviate pain due to skeletal metastases. Palliative radiotherapy is administered as larger fractions over shorter periods of time than conventional radical courses of treatment to maximize benefit.^[21]

Summary

Ocular metastasis occurs late in the natural history of cervical cancer and often heralds a rapid downhill course. Our case possibly represents one end of the spectrum: That of extremely delayed presentation with disseminated metastasis. Although

rare, choroidal metastasis may be the presenting feature of primary cervical malignancy. Furthermore, cervical malignancy must be ruled out in women who present with orbital or choroidal metastases arising from an unknown primary.^[12] Literature shows that nearly a quarter of patients with orbital metastases develop ocular symptoms before the diagnosis of primary neoplasm.^[22] Therefore a high degree of suspicion and diagnostic skills are needed on the part of ophthalmologist while dealing with an ocular or adnexal metastasis of unknown primary as expedited diagnosis can have a profound impact on the outcome for the patient.^[8]

Acknowledgments

The authors acknowledge the contributions of Sumedh S. Hoskote, MD, Critical Care Medicine, Mayo Clinic, Rochester, MN, USA, Veena R. Iyer, MD, Department of Radiodiagnosis, University of Minnesota, MN, USA and Aniruddha Agarwal, MD, Stanley M. Truhlsen Eye Institute, University of Nebraska Medical Center, NE, USA.

Financial support and sponsorship

Nil.

Conflicts of interest

There are no conflicts of interest.

References

- Gosslee JM, Misra RP, Langford MP, Vekovius B, Byrd WA, Flynn SB. Orbital metastasis of keratinizing squamous cell cervical carcinoma with giant cells. A case report. *Int Ophthalmol* 2009;29:39-44.
- Kaarthigeyan K. Cervical cancer in India and HPV vaccination. *Indian J Med Paediatr Oncol* 2012;33:7-12.
- Setoodeh R, Hakam A, Shan Y. Cerebral metastasis of cervical cancer, report of two cases and review of the literature. *Int J Clin Exp Pathol* 2012;5:710-4.
- Hertzanu Y, Vellet AD, Fain BA, Ferreira MM, Ninin DT. Eye metastases in carcinoma of the cervix. A case report. *S Afr Med J* 1987;71:53-4.
- Kurosawa A, Sawaguchi S. Iris metastasis from squamous cell carcinoma of the uterine cervix. Case report. *Arch Ophthalmol* 1987;105:618.
- Wiegel T, Kleineidam M, Schilling A. Choroid metastasis in a patient with adenocarcinoma of the cervix. A case report. *Strahlenther Onkol* 1995;171:539-42.
- Ortiz JM, Esterman B, Paulson J. Uterine cervical carcinoma metastasis to subconjunctival tissue. *Arch Ophthalmol* 1995;113:1362-3.
- Lee HM, Choo CT, Poh WT. Orbital metastasis from carcinoma of the cervix. *Br J Ophthalmol* 1997;81:330-1.
- Inoue K, Numaga J, Kaji Y, Toda J, Kato S, Sakurai M, *et al*. Bilateral choroidal metastases secondary to uterocervical carcinoma of the squamous cell type. *Am J Ophthalmol* 2000;130:682-4.
- McCulley TJ, Yip CC, Bullock JD, Warwar RE, Hood DL. Cervical carcinoma metastatic to the orbit. *Ophthalm Plast Reconstr Surg* 2002;18:385-7.
- Park TW, Theuerkauf I, Morakkabati N. Orbital metastases of unknown origin: HPV typing identifies the primary tumor. *Acta Obstet Gynecol Scand* 2005;84:702-4.
- Singh K, Kumar V, Bhasker S, Mohanti BK. Carcinoma cervix with metastasis to the orbit: A case report and review of the literature. *J Cancer Res Ther* 2007;7:357-8.
- Sareen P, Blandon RE, Binder NR, Wallace DL. Metastasis of squamous cell cervical carcinoma to the orbit of the eye. *Gynecol Oncol Case Rep* 2012;2:83-6.

14. Shibeb O, Athanasiov P, Simon S, Gilhotra J. Cervical carcinoma manifesting as a progressive bilateral visual loss. *Case Rep Ophthalmol Med* 2014;2014:757261.
 15. Bloch RS, Gartner S. The incidence of ocular metastatic carcinoma. *Arch Ophthalmol* 1971;85:673-5.
 16. Ferry AP, Font RL. Carcinoma metastatic to the eye and orbit II. A clinicopathological study of 26 patients with carcinoma metastatic to the anterior segment of the eye. *Arch Ophthalmol* 1975;93:472-82.
 17. Arepalli S, Kaliki S, Shields CL. Choroidal metastases: Origin, features, and therapy. *Indian J Ophthalmol* 2015;63:122-7.
 18. Char DH, Miller T, Kroll S. Orbital metastases: Diagnosis and course. *Br J Ophthalmol* 1997;81:386-90.
 19. Friedlander M, Grogan M; U.S. Preventative Services Task Force. Guidelines for the treatment of recurrent and metastatic cervical cancer. *Oncologist* 2002;7:342-7.
 20. Shields CL, Shields JA, Gross NE, Schwartz GP, Lally SE. Survey of 520 eyes with uveal metastases. *Ophthalmology* 1997;104:1265-76.
 21. Borgelt B, Gelber R, Larson M, Hendrickson F, Griffin T, Roth R. Ultra-rapid high dose irradiation schedules for the palliation of brain metastases: Final results of the first two studies by the Radiation Therapy Oncology Group. *Int J Radiat Oncol Biol Phys* 1981;7:1633-8.
 22. Shields CL, Shields JA. Metastatic tumors to the orbit. *Int Ophthalmol Clin* 1993;33:189-202.
-