

This is an Open Access article licensed under the terms of the Creative Commons Attribution-NonCommercial 3.0 Unported license (CC BY-NC) ([www.karger.com/OA-license](http://www.karger.com/OA-license)), applicable to the online version of the article only. Distribution permitted for non-commercial purposes only.

# Orbital Cellulitis Presenting as a First Sign of Incomplete Kawasaki Disease

Eren Çerman<sup>a</sup> Muhsin Eraslan<sup>a</sup> Semra Akkaya Turhan<sup>a</sup>  
Sinem Altinyuva Usta<sup>b</sup> Figen Akalın<sup>b</sup>

Departments of <sup>a</sup>Ophthalmology and <sup>b</sup>Pediatrics, Marmara University School of Medicine, Istanbul, Turkey

## Key Words

Kawasaki disease · Orbital cellulitis · Sinusitis

## Abstract

A 6-year-old boy was referred to our hospital with orbital cellulitis. He had a history of 7 days of fever despite antibiotherapy. At first, he only had pharyngitis and conjunctivitis, but then an orbital mass evolved which restricted the movement of his right eye and there was also periorbital inflammation resembling orbital cellulitis. Examination at presentation revealed conjunctivitis with secretion, periocular inflammation and edema, right-preauricular lymphadenopathy and restriction of upgaze in the right eye. Laboratory findings included a white blood cell count of 19,000 cells per mm<sup>3</sup>, with 81.5% neutrophils, 15.0% lymphocytes, 1.2% monocytes and 0.4% basophils. The erythrocyte sedimentation rate was 52 mm/h and the C-reactive protein level was 46.3 mg/dl. Magnetic resonance imaging confirmed orbital cellulitis and pansinusitis. Vancomycin (60 mg/kg/day) and meropenem (100 mg/kg/day) were administered, but desquamation on his fingertips and a rash appeared on the tenth day. A pediatric consultation resulted in a diagnosis of incomplete Kawasaki disease (KD). After administration of aspirin, the orbital inflammation regressed in 3 days. No coronary artery lesions were detected on the first echocardiography, but these did appear 6 weeks later. This confirmed the KD diagnosis.

© 2013 S. Karger AG, Basel

## Introduction

Kawasaki disease (KD) is a multisystem vasculitis with a relatively unknown etiology. It was first described by Tomisaku Kawasaki in Japan [1]. KD particularly affects children younger than 5 years of age. Coronary artery lesions are the most serious complications of

Eren Çerman, MD, FEBOpht  
Acisu Sok. No. 6/2 Ideal apt. Visnezade mah.  
TR-34357 Besiktas Istanbul (Turkey)  
E-Mail [erenceraman@yahoo.com](mailto:erenceraman@yahoo.com)

KD; they can lead to myocardial infarction, coronary artery dilatation and sudden death in the acute and subacute phases of the illness. There is no diagnostic test for KD, with the diagnosis being based on the clinical features. The diagnostic criteria for classic KD are: prolonged fever lasting longer than 5 days, diffuse mucosal inflammation, bilateral nonexudative conjunctivitis, dysmorphic skin rashes, indurative angioedema of the hands and feet and cervical lymphadenopathy. The potentially severe outcome of either classic or incomplete KD without therapy emphasizes the importance of the identification and treatment of all patients with the disease [2]. We report a case with incomplete KD presenting with orbital cellulitis and pansinusitis.

### Case Report

A 6-year-old boy was referred to the Department of Ophthalmology, Marmara University School of Medicine, with the diagnosis of orbital cellulitis. He had had mild fever, pharyngitis and conjunctivitis for 7 days. Four days prior to presenting at our department, he had been referred with complaints of irritation to an ophthalmologist. Consultation with a pediatrician due to his fever resulted in a diagnosis of conjunctivitis and pansinusitis and he was treated with ampicillin-sulbactam and ceftriaxone 100 mg/kg/day. In the following 3 days, restriction of upgaze in the right eye and inflammation of the eyelids began and he was referred to us with a diagnosis of orbital cellulitis. An initial examination revealed normal visual acuity, bilateral conjunctivitis with excessive secretion, periocular inflammation and edema, right preauricular lymphadenopathy and right restriction in the upgaze and his lips were dry and cracked (fig. 1). Magnetic resonance imaging confirmed orbital cellulitis and pansinusitis (fig. 2).

His erythrocyte sedimentation rate on the first day of hospitalization was 55 mm/h and the C-reactive protein level was 22.4 mg/dl. Laboratory findings included a white blood cell (WBC) count of 19,000 cells per mm<sup>3</sup>, with 81.5% neutrophils, 15.0% lymphocytes, 1.2% monocytes and 0.4% basophils. The antibiotherapy was changed to vancomycin 60 mg/kg/day and meropenem 60 mg/kg/day. After 10 days of hospitalization without a clear response to antibiotherapy, periungual desquamation of the fingers started (fig. 3). Pediatric examination revealed a strawberry tongue. Repeated laboratory tests revealed a total WBC count of 15,300 cells per mm<sup>3</sup> with 63.8% neutrophils, an elevated platelet count (650,000 mm<sup>3</sup>), an erythrocyte sedimentation rate of 52 mm/h and an elevated C-reactive protein level of 46.3 mg/dl. The serum transaminase urine examination was normal. Following the algorithm defined previously, we concluded a diagnosis of incomplete KD (table 1; online suppl. table 2, see [www.karger.com/doi/10.1159/000257258](http://www.karger.com/doi/10.1159/000257258)) [3]. With the first echocardiography, no coronary artery lesions were detected. Aspirin (100 mg/day) was administered and by the third day of its administration, the orbital cellulitis and fever had regressed and the patient was discharged from hospital with oral antibiotics and aspirin. After 6 weeks, his control echocardiography revealed dilatation of the right and left coronary arteries and the diagnosis of incomplete KD was confirmed. He was treated with a single dose of intravenous immunoglobulin, 2 mg/kg over 10 h.

### Discussion

Incomplete KD should be considered in children who have unexplained fever for at least 5 days that is associated with two or three of the five diagnostic criteria for KD (table 1) [4].

Although laboratory values are nonspecific and nondiagnostic, they are quite characteristic and may prove useful in reducing suspicion of incomplete KD [2]. Typically, there is an elevated WBC count, platelet count, ESR and CRP. Intravenous immunoglobulin and aspirin are effective treatment choices for inflammation caused by KD.

KD results from an inappropriate immunological response to one or more infectious triggers in genetically susceptible individuals and fits between an infectious and an autoimmune disease on the spectrum [5, 6]. In this particular case, unresponsiveness to antibiotics but a good response to aspirin may have been associated with orbital inflammation as a part of KD. Although the existence of orbital lymphatics is controversial [7, 8], Rowley et al. [9] reported a characteristic, selective pattern of IgA plasma cell infiltration in acute KD in vascular and nonvascular tissue. This IgA plasma cell migration capability that manifests in KD may explain the peculiar presentation with orbital cellulitis. Newburger et al. [3] proposed that the description ‘atypical Kawasaki disease’ should be reserved for patients with complications that are generally not seen in KD. Our case could therefore be defined as atypical KD. Once previously, KD was reported as presenting with orbital cellulitis [10]. Our case shows that even incomplete KD may present with orbital cellulitis or sinusitis.

## Conclusion

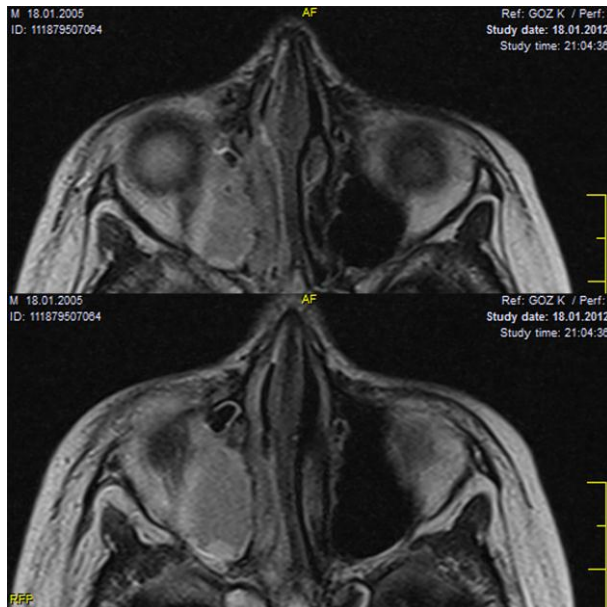
This case is an interesting example showing that an orbital cellulitis unresponsive to antibiotherapy should be investigated for underlying KD. The consequences of KD may be mortality and serious morbidity, so ophthalmologists should always be careful when pediatric patients present with fever and orbital cellulitis.

## References

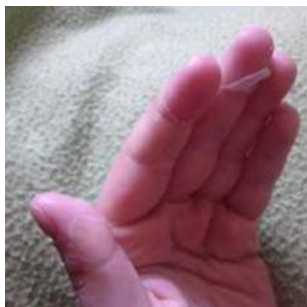- 1 Kawasaki T, Kosaki F, Okawa S, Shigematsu I, Yanagawa H: A new infantile acute febrile mucocutaneous lymph node syndrome (MLNS) prevailing in Japan. *Pediatrics* 1974;54:271–276.
- 2 Rowley AH: Incomplete (atypical) Kawasaki disease. *Pediatr Infect Dis J* 2002;21:563–565.
- 3 Newburger JW, Takahashi M, Gerber MA, et al: Diagnosis, treatment, and long-term management of Kawasaki disease: a statement for health professionals from the Committee on Rheumatic Fever, Endocarditis and Kawasaki Disease, Council on Cardiovascular Disease in the Young, American Heart Association. *Circulation* 2004;110:2747.
- 4 Shulman ST, Rowley AH: Advances in Kawasaki disease. *Eur J Pediatr* 2004;163:285–291.
- 5 Burgner D, Harnden A: Kawasaki disease: what is the epidemiology telling us about the etiology? *Int J Infect Dis* 2005;9:185–194.
- 6 Yeung RS: Kawasaki disease: update on pathogenesis. *Curr Opin Rheumatol* 2010;22:551–560.
- 7 Givner LB: Periorbital versus orbital cellulitis. *Pediatr Infect Dis J* 2002;21:1157–1158.
- 8 Dickinson AJ, Gausas RE: Orbital lymphatics: do they exist? *Eye* 2006;20:1145–1148.
- 9 Rowley AH, Schulman ST, Mask CA, et al: IgA plasma cell infiltration of proximal respiratory tract, pancreas, kidney, and coronary artery in acute Kawasaki disease. *J Infect Dis* 2000;182:1183–1191.
- 10 Sheard RM, Pandey KR, Barnes ND, Vivian AJ: Kawasaki disease presenting as orbital cellulitis. *J Pediatr Ophthalmol Strabismus* 2000;37:123–125.

**Table 1.** American Heart Association criteria for incomplete KD [3]

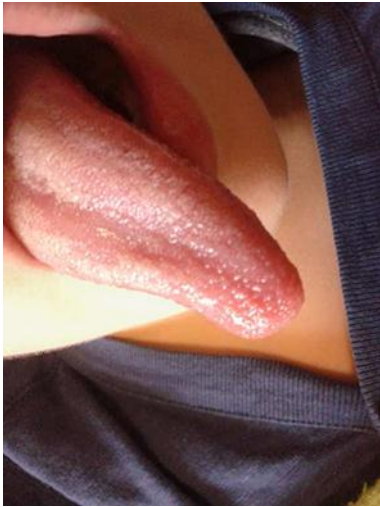Fever $\geq$ 5 days associated with $\geq$ 2 of the following principal criteria	Our case
Bilateral nonsuppurative conjunctivitis	Yes
One or more changes to the mucous membranes including pharyngeal injection, dry fissured lips, injected lips and strawberry tongue	Yes
Indurative angioedema of the hands and feet including peripheral erythema, peripheral edema, periungual desquamation or generalized desquamation	Yes
Dysmorphous skin rashes	No
Acute, nonpurulent, cervical lymphadenopathy $>$ 1.5 cm in diameter	No



**Fig. 1.** Orbital cellulitis as a first sign of underlying KD.



**Fig. 2.** Magnetic resonance imaging shows orbital cellulitis and sinusitis.



**Fig. 3.** Periungual desquamation in the subacute phase of KD.