

# Hemoptysis: A Rare Presentation of Mixed Gonadal Dysgenesis

Darvin V. Das, PK Jabbar, Ramesh Gomez, Seena TP

Department of  
Endocrinology, Trivandrum  
Medical College,  
Thiruvananthapuram, Kerala,  
India

ABSTRACT

The objective of the study was to present a case report on a phenotypic male mixed gonadal dysgenesis (MGD) who presented with hemoptysis due to secondary lung metastasis from dysgerminoma. Phenotypic male MGD (45, X/46, XY) with primary infertility and hemoptysis participated in the study. This study was conducted at a tertiary care center. Laparoscopic visualization of gonads and presence of Müllerian/ Wolffian structures were ascertained. Gonadectomy of intra abdominal dysgenetic gonad were done. Fluorescence *in situ* hybridization analysis was done in gonadal tissue to find the presence of Y chromosome. Intra-abdominal gonad showed dysgerminoma changes. Müllerian structures in the form of rudimentary uterus and fallopian tubes were seen. Left inguinal gonad showed normal testicular structures. Chemotherapy for secondary lung metastasis contemplated.

**KEYWORDS:** Chemotherapy, dysgerminoma, fluorescence *in situ* hybridization, male infertility, mixed gonadal dysgenesis

## INTRODUCTION

Mixed gonadal dysgenesis (MGD) presents as a spectrum of phenotype ranging from women with or without Turner's stigmata to individuals with ambiguous genitals and rarely normal male. The clinical presentation includes ambiguous genitals at birth, delayed puberty, virilization at puberty in women, or infertility. Here, we present a case of MGD with male phenotype who presented to us with hemoptysis due to secondary metastasis to lung from dysgerminoma arising from a dysgenetic gonad.

## CASE REPORT

A 34 year old male presented to the emergency department with a history of hemoptysis since 5 days. He had a history of loss of weight and appetite. He had no history of tuberculosis (TB) or TB contact, smoking, fever, or drugs. He also had a history of the inability to father a child and have never sought medical treatment for the same. There was no history of loss of libido, hypothyroidism, radiation to head or neck, surgery to head or abdomen, or symptoms of raised intracranial tension. On examination, his height was 156

cm and weight was 45 kg. His vitals were stable. He had pallor and digital clubbing. External genital examination showed genital ambiguity in the form of bifid scrotum, which was rugose and pigmented with a phallus of length 9 cm with well-formed glands [Figure 1]. The right gonads were not palpable in labioscrotal fold or elsewhere and the left gonads were palpable in the left inguinal region. There was no vaginal opening. Sexual maturity rate (SMR) P2 B1 with no axillary hair. He had poor facial and body hair. A natal history was later reviewed with him and there was no history of salt-wasting crisis, maternal virilization, or history of sex reversal. We considered the possibility of 46XY disorder of sex development (DSD), MGD, or ovotesticular DSD.

Laboratory investigations included hemoglobin of 8 g/dl, total leukocyte count of 8000/mm<sup>3</sup>, platelet count of 4.5 lakhs, and erythrocyte sedimentation rate of 60. Liver function test (LFT), renal function test (RFT), blood glucose, serum electrolytes, cortisol (8 am cortisol 16.08 mcg/dl), and 17-OH-progesterone were normal (1.1 ng/

**Address for correspondence:** Dr. Darvin V. Das, Assistant Professor, Department of Endocrinology, Government Medical College, Thiruvananthapuram-695 541, Kerala, India.  
E-mail: drdarvindas@gmail.com

Received: 02-04-2020  
Accepted: 08-06-2020

Revised: 05-05-2020  
Published: 27-10-2020

### Access this article online

#### Quick Response Code:



**Website:**  
www.jhrsonline.org

**DOI:**  
10.4103/jhrs.JHRS\_51\_20

This is an open access journal, and articles are distributed under the terms of the Creative Commons Attribution-NonCommercial-ShareAlike 4.0 License, which allows others to remix, tweak, and build upon the work non-commercially, as long as appropriate credit is given and the new creations are licensed under the identical terms.

**For reprints contact:** WKHLRPMedknow\_reprints@wolterskluwer.com

**How to cite this article:** Das DV, Jabbar PK, Gomez R, Seena TP. Hemoptysis: A rare presentation of mixed gonadal dysgenesis. J Hum Reprod Sci 2020;13:242-4.

ml). Pooled follicle-stimulating hormone and luteinizing hormone levels were 14 mIU/mL and 9 mIU/mL, respectively; thyroid-stimulating hormone: 3.8 mIU/L, T4: 130 nmol/L (60–140), basal total testosterone: 240 ng/dL, estradiol 20 pg/ml (normal male: 10–50 pg/ml), prolactin 12 ng/ml (5–20 ng/ml), and inhibin B 156 ng/ml (80–300 ng/ml). Work up for tuberculosis (TB) which includes sputum acid fast bacilli and TB polymerase chain reaction study with sputum and blood specimens were negative. Chest-X ray was normal.

High-resolution computed tomography chest showed irregular solid lesions in the right upper lobe suggestive of a lung metastasis. Search for primary malignancy was done and investigations included upper endoscopy, colonoscopy, USG abdomen and pelvis, and tumor markers study (alpha fetoprotein, lactate dehydrogenase, carcinoembryonic antigen, and prostate-specific antigen levels). Ultrasound of the pelvis showed hypoplastic uterus with no gonads visualized. Tumor markers and gastrointestinal study were normal. Karyotyping (30 cells and 100 cells) revealed 45, X genotype. In view of the possibility of malignancy arising from a dysgenetic gonad and the inability to localize primary malignancy from the initial evaluation, we proceeded with a laparoscopy. Laparoscopic examination was done and visualized the right gonads and ducts. Laparoscopy showed enlarged right gonads in the ovarian fossa with bilateral fallopian tubes and hypoplastic uterus [Figure 2]. The right gonad was adhering to the adjacent peritoneum. The left gonad was visualized in the left inguinal region and biopsy was taken to confirm the type of gonad. The right gonad with fallopian tubes and rudimentary uterus was removed. A thorough histopathological examination of the right gonad showed dysgerminoma, and the left gonad showed testicular tissue (seminiferous tubules and Leydig cells). Dysgerminoma arising from the right gonad showed sheets or nests of large, uniform polygonal cells with clear or eosinophilic cytoplasm with distinct squared off cell membranes and with loose stroma [Figure 3]. No ovarian tissue was noted in these sections. Fluorescence *in situ* hybridization (FISH) for the identification of Y chromosome was done in gonadal tissue. FISH showed mosaic pattern with 90% cells of 45,X and 10% showing X and Y chromosomes 45, X/46,XY.

## DISCUSSION

MGD is a chromosomal disease characterized by mosaicism with a karyotype ranging from 45,X/46,XY (classical form) to 45,X/47,XYY or 46X/46,XY/47,XYY. The phenotype includes women with or without Turner's stigmata to men with or without ambiguous genitalia. Internal ducts may range from the presence of Müllerian ducts and/or Wolffian ducts and

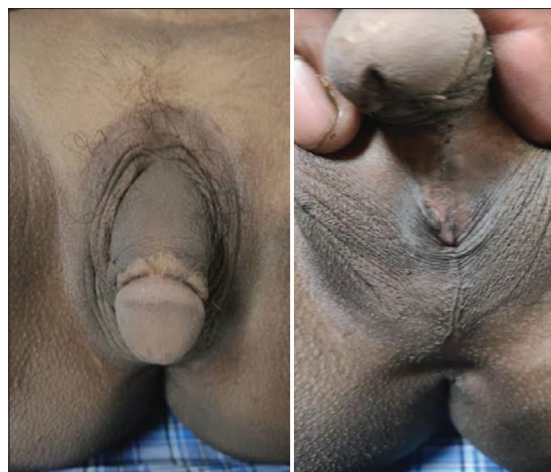

Figure 1: External genitalia

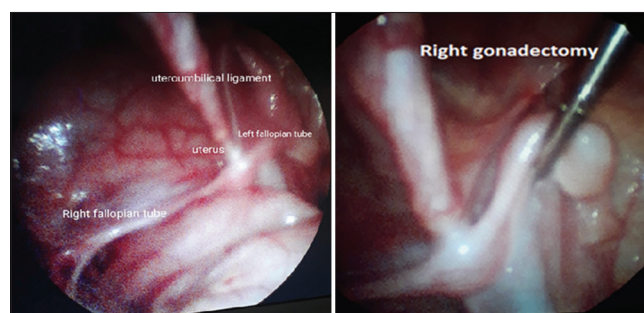


Figure 2: Laparoscopic view

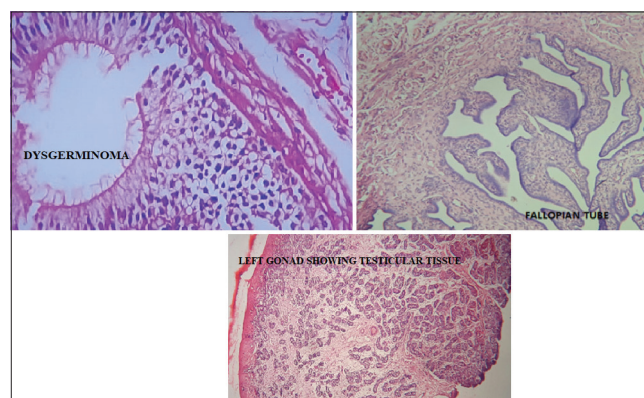


Figure 3: Histology of the resected gonads

gonads may show normal testis to streak gonads.<sup>[1]</sup> The estimated prevalence of tumor in MGD is reported to be 10%–15%.<sup>[2]</sup> The risk doubles as the individual approaches 30 years of age.<sup>[3]</sup>

In our case report, we present a phenotypically male who has ambiguous genitalia and a history of primary infertility who had never been evaluated and presented at adulthood with hemoptysis secondary to lung metastasis. We considered the possibility of 46, XY DSD, MGD, or ovotesticular DSD as differential

diagnosis for his genital ambiguity. Elevated serum total testosterone levels pointed to the possibility of testis as the gonad, though testosterone levels were not to a normal range of adult male. Estradiol levels were in the range of a normal male. Karyotype done on two separate occasions (30 cells and 100 cells) showed 45,X cells.<sup>[4]</sup> The high suspicion of an underlying Y chromosome was considered in this case, and hence, we planned a laparoscopy to locate gonads. Laparoscopy showed enlarged right gonad with Müllerian structures. Left inguinal gonad was biopsied in view of the possibility of a tumor. FISH done in the gonadal tissue revealed mosaicism 45, X/46,XY favoring MGD.<sup>[4]</sup> Bilateral gonadectomy is recommended in this condition considering the higher possibility of malignancy from the dysgenetic gonad.<sup>[5]</sup> Intra-abdominal dysgenetic gonads have a high risk of malignant changes compared to inguinal or scrotal. Our patient who has been reared and raised as a male and prefer female partner. The case report highlights the rare clinical presentation of MGD and issues regarding gonadectomy timing and follow up in a case of MGD. The preference for gonadectomy again varies based on the type of sex assigned and to live. Male MGD who desires to continue as male with inguinal or scrotal gonads may need for surveillance for malignancy time to time. Recommendation includes regular testicular self-examination and yearly testicular ultrasound in those patients who are reared as males.<sup>[5]</sup> No evidence supports appropriate frequency of monitoring or suggests that other methods of monitoring, such as laboratory screening, may be more useful in detecting onset of malignancy.<sup>[5]</sup> Intra-abdominal dysgenetic gonads need urgent localization and removal as in our case report. Individual who wish to be reared as females can undergo an early gonadectomy (regardless of the position of gonad) and later feminization with hormones. In our case, as the patient was a male and married wishing to father a child, we had to convince the patient regarding the situation. The right intra-abdominal gonad had to be removed in view of tumor changes as evident from a lung metastasis and gross morphology of the gonad with adjacent adhesion. The left inguinal gonad had to be visualized with ultrasound. Although ultrasound of left gonad was normal, we undertook a biopsy of the right gonad to rule out the presence of gonadoblastoma or malignant testicular tumors and dysgenesis. The right gonad was normal testicular histology. Postoperative tumor markers were normal. Considering the preservation of male gonad

function, we have planned regular monitoring of the right gonadal surveillance. Patients have been planned for chemotherapy with BEP regimen (bleomycin, etoposide, and carboplatin) from oncology division for dysgerminoma metastasis to lung.<sup>[6]</sup>

## CONCLUSION

Malignant testicular tumor risk escalates in dysgenetic gonad of intra-abdominal site and as the age progresses in MGD. Gonadectomy should be prompt in all DSD patients with Y chromosomes. Y chromosomes' search may be done in gonadal tissue in a strong clinical background when blood leukocytes do not show expected results.

## Declaration of patient consent

The authors certify that they have obtained all appropriate patient consent forms. In the form, the patient has given his consent for his images and other clinical information to be reported in the journal. The patient understands that name and initials will not be published and due efforts will be made to conceal identity, but anonymity cannot be guaranteed.

## Financial support and sponsorship

Self.

## Conflicts of interest

There are no conflicts of interest.

## REFERENCES

1. Gravholt CH, Fedder J, Naeraa RW, Müller J. Occurrence of gonadoblastoma in females with Turner syndrome and Y chromosome material: A population study. *J Clin Endocrinol Metab* 2000;85:3199-202.
2. Cools M, Boter M, van Gurp R, Stoop H, Poddighem P, Chris Lau YF, *et al.* Impact of the Y-containing cell line on histological differentiation patterns in dysgenetic gonads. *Clin Endocrinol* 2007;67:184-92.
3. Uehara S, Hashiyada M, Sato K, Nata M, Funato T, Okamura K. Complete XY gonadal dysgenesis and aspects of the SRY genotype and gonadal tumor formation. *J Hum Genet* 2002;47:279-84.
4. Saikia UK, Sarma D, Das DV, Goswami JK, Kaushik , Saikia C, *et al.* A case of mixed gonadal dysgenesis: A diagnostic challenge. *J Hum Reprod Sci* 2019;12:169-72.
5. McCann-Crosby B, Mansouri R, Dietrich JE, McCullough LB, Sutton VR, Austin EG, *et al.* State of the art review in gonadal dysgenesis: Challenges in diagnosis and management. *Int J Pediatr Endocrinol* 2014;2014:4.
6. Gershenson DM, Morris M, Cangir A, Kavanagh JJ, Stringer CA, Edwards CL, *et al.* Treatment of malignant germ cell tumors of the ovary with bleomycin, etoposide, and cisplatin. *J Clin Oncol* 1990;8:715-20.