

# Distraction osteogenesis for correction of mandibular abnormalities

Departments of Oral and Maxillofacial Surgery, <sup>1</sup>Pedodontics, College of Dental Sciences and Hospital, Rau, Indore, <sup>2</sup>Oral and Maxillofacial Surgery, Government Dental College, PGIMS, Rohtak, Haryana, India

Vinayak Karun, Navneet Agarwal<sup>1</sup>, Virendra Singh<sup>2</sup>

## ABSTRACT

**Introduction:** Management of mandibular deformities is challenging. Distraction osteogenesis is a relatively new technique with promising results. **Materials and Methods:** We selected 12 patients. The osteotomy site decided was proximal to the antegonial notch. Latency time was five to seven days. Consolidation period was eight weeks in eleven cases and six weeks in one case. **Results:** In all the patients, appreciable lengthening of mandible was achieved. **Discussion:** The greatest advantage of distraction osteogenesis is growth of soft tissue along with the growth of hard tissue. This increases post operative stability

**Key words:** Distraction osteogenesis, facial asymmetry, mandible lengthening

## Address for correspondence:

Dr. Vinayak Karun,  
Department of Oral and  
Maxillofacial Surgery,  
572, Greater Brajeshwari,  
Pipliyahana, Near Agarwal Public  
School, Indore - 452 016,  
Madhya Pradesh, India.  
E-mail: misterneo@gmail.com

## INTRODUCTION

Abnormalities of the mandible can be a major cause of concern, as they can lead to facial asymmetry and functional problems. They are usually managed by orthognathic surgery and augmentation procedures. The main drawback of orthognathic surgery is that it cannot be undertaken while the patient's growth is incomplete, and during this period, the patient has to bear a lot of psychological trauma and compromise with the functional efficiency.<sup>[1]</sup> Augmentation procedures, like hard or soft tissue grafting, are also associated with numerous complications like donor site morbidity, resorption of graft, infection, and so on. In recent times, distraction osteogenesis has evolved as a viable alternative to the above-mentioned procedures.

Through distraction osteogenesis we are able to guide the formation of the new bone and its spatial orientation, to form a structural part of the distracted bone. There is

excellent biological feasibility of the distraction method in the promotion of human bone regeneration.

It was first used by Codivilla in 1905,<sup>[2]</sup> for femoral lengthening, and popularized by Gavriil Ilizarov, a Russian orthopedic surgeon, in the 1950's.<sup>[3-7]</sup> McCarthy and Colleagues<sup>[2]</sup> were the first to apply distraction osteogenesis to the craniofacial skeleton in children having congenital craniofacial anomalies. The current study reports our clinical experience with the lengthening of a mandible in 12 patients, by distraction osteogenesis.

## MATERIALS AND METHODS

The present study was undertaken in 12 patients. The group under study included six female and six male patients, with an average age of 15 years (range six to twenty-six years). Only those cases with unilateral or bilateral hypoplasia of the mandible were selected. A thorough medical history was taken. Cephalometrics for Orthognathic Surgery,<sup>[8]</sup> soft tissue cephalometric analysis for orthognathic surgery,<sup>[9]</sup> and posteroanterior cephalometric analysis<sup>[10]</sup> were carried out to assess and quantify the asymmetry. Frontal and profile photographs of the patient were taken preoperatively, intraoperatively, postoperatively, and at regular follow-ups. An orthopantomogram (OPG) was done for diagnosing the cases of ankylosis, to determine the location of the osteotomy, to evaluate the position of the third molar in

### Access this article online

#### Quick Response Code:



Website:  
www.njms.in

DOI:  
10.4103/0975-5950.127653

relation to the osteotomy site, to determine the position of the inferior alveolar canal, and to measure the amount of bone formed in two cases of bone transportation. The distraction vector was kept oblique for simultaneous lengthening of the mandibular body and ramus. Custom-made stainless steel extraoral (in eight patients) and intraoral (in two patients) distraction devices from the Ortho Max Company, Baroda, India, were used. The technique of distraction was divided into four sequential periods. (1) *Osteotomy and Device fixation*: An incision was placed along the external oblique ridge. A full thickness mucoperiosteal flap was raised. Subsequently, the area of bone deficiency was identified. The osteotomy site decided was proximal to the antegonial notch, because this region provided adequate bone stock, for pin placement and for aligning the device according to the pre-decided vector. Buccal plate corticotomy and partial corticotomy of the lingual plate was done. The pins were placed perpendicular to the corticotomy, and then the distraction device was applied. A spreader was used to bring about a tension fracture of the lingual cortical plate and complete the osteotomy. Following closure of the incisions, extraoral dressing was placed, and it was changed daily for three to four days postoperatively. During the application of the intraoral distractor, all the steps were similar except a variation that the distractor was fixed with screws placed through the same incision that was used for approaching the site. There was no need for a percutaneous incision. (2) *Latency Period*: This was of five to seven days and represented the time required for reparative fibrous callus formation. (3) *Distraction Period*: The distraction period was the time when a traction force was applied to the bone segments and a new bone regenerate was formed. The rate of distraction was kept at 1 mm/day in two fractions of 0.5 mm. In consultation with orthodontists, it was decided that distraction would be stopped when the midline of the upper central incisor coincided with the midline of the lower central incisor. (4) *Consolidation Period*: This stabilization period was of six weeks in one patient and eight weeks in other patients, which allowed mineralization of the newly formed bone tissue prior to removal of the distraction device.

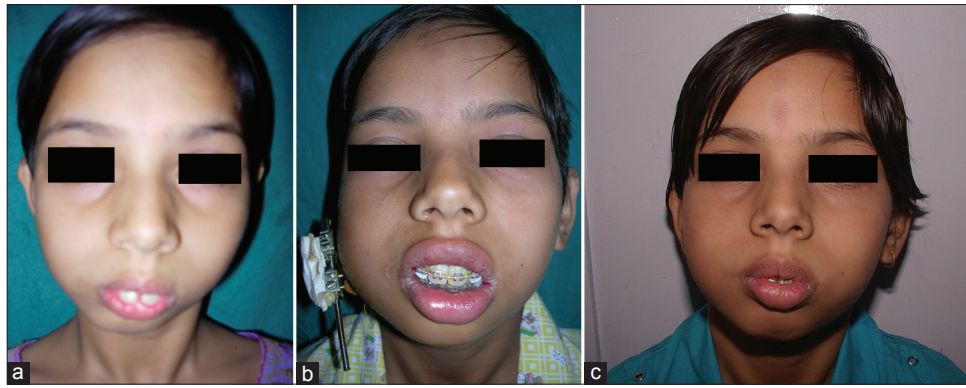In cases where temporomandibular joint ankylosis and distraction were performed simultaneously, both active and passive physiotherapy was started from the first postoperative day. The patient's progress and response was monitored on the standard patient monitoring chart designed for the study. Local care of the stab wound over the cheek was done by dressing and cleaning regularly with saline, hydrogen peroxide, and betadine ointment. Stitches were removed on the seventh postoperative day. A panoramic radiograph along with the lateral and posteroanterior cephalometric radiograph was performed to compare and document the correction

and the bone formation at the corticotomy site. The distractors were removed under local analgesia after completion of the consolidation period.

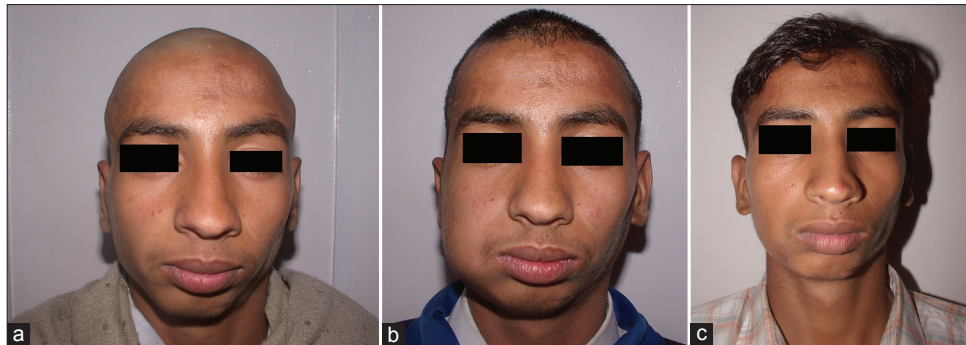
Patients were recalled on an Outpatient Department (OPD) basis after one month, three months, and six months, for follow-up. They were referred for orthodontic treatment after removal of the distractor. In this study, periodic follow-up was conducted for a minimum of six months to a maximum of two years. The clinical parameters that were evaluated included pain on movement, resistance to movement, paresthesia, loosening of pins/screws, infection, hardware failure, relapse, and scarring. Statistical analysis was carried out by finding the mean and standard deviation in most of the parameters, and the paired *t*-test was applied in the pre- and post-distraction cephalometric findings [Tables 7,9-11].

## RESULTS

In each case, an adequate amount of bone lengthening was achieved [Tables 6 and 8]. The amount of mandibular body lengthening achieved was in the range of 6-14 mm. The ramal lengthening achieved was in the range of 4 to 8 mm [Table 1]. Soft tissue analysis showed a decrease in the value of the facial convexity angle (G-Sn-Pg) and an increase in the value of mandibular prognathism (G-Pg), which were suggestive of an increase in the bulk of soft tissue, due to the anterior positioning of the mandible [Tables 8 and 9]. The age group of patients varied from 6-24 years with a mean of 17 years [Table 2]. Ten patients were treated using the extraoral distraction device [Figure 1a-c] and two patients with the intraoral distraction device [Figure 2a-c] [Table 3]. Out of the two patients treated with the intraoral distraction device, one patient was treated for unilateral mandibular hypoplasia and the other patient for bilateral mandibular hypoplasia. Out of the twelve patients, six patients had temporomandibular joint ankylosis. In four cases, the distraction device was applied after releasing the ankylosis, in a second operation. However, in two patients, it was applied simultaneously with ankylosis release [Table 4]. Out of these two patients, the external device was applied in one and the intraoral device in the other patient. Out of ten patients treated with the extraoral distraction device, bone transportation was done in two patients [Table 5]. In both the patients of bone transportation, we were able to decrease the amount of gap between the ends of the bone fragment. In one patient 14 mm and in the other 11 mm of bone lengthening was done. At every distraction, the resistance to movement was recorded. It was observed that moderate resistance to distraction was present in patients more during the morning time [Table 12]. Our study showed no evidence of nerve injury in any patient. In



**Figure 1:** (a) Extraoral distraction – pre-distraction view, (b) Extraoral distraction – intra-distraction view, (c) Extraoral distraction – post-distraction view



**Figure 2:** (a) Intraoral distraction – pre-distraction view, (b) Intraoral distraction – intra-distraction view, (c) Intraoral distraction – post-distraction view

**Table 1: Master chart**

Case no.	Age/ sex	Diagnosis	Device	Period of distraction (Days)	Consolidation period (Weeks)	Increase in md. Body length (mm)	Increase in ramal height (mm)	Chin deviation corrected (mm)	Result	Note
1	18/F	Retrognathia with left TMJ ankylosis	E/O	11	8	6	5	2	Slight discrepancy	-
2	18/F	Retrognathia with left TMJ Ankylosis	E/O	15	8	9	6	5	Slight discrepancy	-
3	18/M	Retrognathia with left TMJ ankylosis	E/O	19	8	11	8	6	Acceptable	-
4	16/M	B/L mandibular hypoplasia	I/O	14	8	10	6	2	Acceptable	-
5	12/F	Rt. mandibular. hypoplasia	E/O	11	8	7	5	3	Acceptable	-
6	16/F	Retrognathia with left TMJ ankylosis	E/O	12	8	7	4	3	Slight discrepancy	-
7	16/M	Retrognathia with right TMJ ankylosis	I/O	16	8	13	8	7	Acceptable	-
8	14/F	Retrognathia with right TMJ ankylosis	E/O	22	8	12	7	7	Acceptable	-
9	6/F	Left mandibular hypoplasia due to hemifacial microsomia	E/O	19	8	10	7	5	Acceptable	-
10	11/M	Right Mandibular Hypoplasia	E/O	17	6	11	8	3	Acceptable	-
11	26/M	Post trauma defect	E/O	26	8	14	-	-	Discrepancy	Bifocal bone transportation
12	7/M	Post surgical defect	E/O	17	8	11	-	-	Discrepancy	Bifocal bone transportation

md: Mandible, E/O: Extra oral, I/O: Intra oral TMJ: Temporomandibular joint

only two cases, loosening of pins was noticed [Table 13]. This however, did not affect our final result. The rate of infection was also minimum in the observed cases. It manifested as pus discharge from one of the skin pin interfaces on the eleventh post-operative day in one patient and on the twelfth post operative day in the other

patient. Pus culture and sensitivity was done, and the patients were put on oral antibiotics based on the report. The infection resolved uneventfully by the fifth day of antibiotic coverage. In two patients, hardware failure was observed. In one patient, slight bending of the distractor was observed from the fourth day of distraction, which

gradually increased until the tenth day of distraction. On the tenth day, the patient reported an audible click and severe pain in the distraction site, which gradually subsided on taking analgesics. Following that, the distraction appliance straightened. In the second patient, at the end of the distraction period, it was observed that the proximal pin was placed in the soft tissue. As the distractor would not have served the purpose of stabilizing the distracted fragments during the period of consolidation, the distraction device was removed and intermaxillary fixation was done. At the end of six months, a relapse was observed in only one case.

## DISCUSSION

Distraction osteogenesis has established itself as not only a reliable, but also a versatile technique, because along with an increase in volume of the hard tissue, it also facilitates soft tissue histogenesis, which makes it unique from orthognathic surgery and bone grafting. However, sometimes this technique is not sufficient to achieve the desired aesthetics and a secondary procedure has to be considered. The youngest patient in our study was six years old and her facial deformity was due to hemifacial microsomia. Karp and Thorne<sup>[11]</sup> have mentioned that early elongation of the mandible may minimize the

**Table 2: Age distribution of patients**

	No. of patients	Percentage
5-10 years	2	17
11-15 years	3	25
16-20 years	6	50
20-25 years	1	8
Mean age $\pm$ SD	14.75 $\pm$ 5.2	
Range	6-24 years	

**Table 3: Type of device used**

Type of device	No. of patients	Total No. of patients	% age
Intra oral	2	12	17
Extra oral	10	12	83

**Table 4: Time of distractor application in TMJ ankylosis patients**

Timing	No. of patients	Total no. of patients with ankylosis	% age
Simultaneous with ankylosis treatment	2	6	33
After treating ankylosis	4	6	67

TMJ: Temporomandibular joint

**Table 5: Purpose of distraction osteogenesis**

Procedure	No. of patients	Total no. of patients	% age
Facial asymmetry correction	10	12	83
Segmental defect correction by bifocal bone transportation	2	12	17

**Table 6: COGS analysis for hard tissue**

Values	Patient 1 (Distraction)		Patient 2 (Distraction)		Patient 3 (Distraction)		Patient 4 (Distraction)		Patient 5 (Distraction)		Patient 6 (Distraction)		Patient 7 (Distraction)		Patient 8 (Distraction)		Patient 9 (Distraction)		Patient 10 (Distraction)	
	Pre	Post	Pre	Post	Pre	Post	Pre	Post	Pre	Post	Pre	Post	Pre	Post	Pre	Post	Pre	Post	Pre	Post
N-A-Pg (Angle in degrees)	21	17	15	11	18	13	15	9	17	10	17	12	17	14	16	12	12	9	20	13
N-B	-15	-9	-16	-11	-11	-7	-17	-9	-5	-2	-15	-8	-12	-8	-22	-18	-12	-9	-9	-4
N-Pg	-20	-13	-20	-15	-16	-10	-11	-7	-13	-9	-22	-16	-18	-11	-26	-22	-18	-15	-14	-9
ANS-Gn	50	54	56	63	61	69	65	70	48	55	52	57	60	67	61	68	53	61	48	56
MP-HP (Angle in degrees)	33	36	31	36	24	28	24	29	26	29	17	19	27	30	30	35	29	34	19	23
Ar-Go	46	51	48	54	45	53	49	55	39	44	46	50	42	50	51	58	41	48	39	47
Go-Pg	59	65	66	75	64	76	71	81	66	73	62	69	63	76	54	65	48	58	69	80
B-Pg	2	2	4	6	3	7	5	2	3	2	1	2.5	6	9	2	6	3	5	2	5
Ar-Go-Gn (Angle in degrees)	123	126	123	127	118	123	122	126	115	118	120	122	121	126	122	124	138	141	111	117
AB	-5	-3	-1	-1	-3	-2	-6	-3	-5	-5	-3	-1	-8	-5	-1	-1	-5	-2	-10	-7

Values of COGS analysis are shown in table; Facial convexity (N-A-Pg Angle) decreased after distraction, Values of Ar-Go (representing mandibular ramus length) and Go-Pg (representing mandibular body length) increased after distraction



progressive restriction in midface growth by restoration of a more normal functional matrix.

In the two patients, who were treated with the intraoral distractor, skin scarring caused by transcutaneous fixation of the pins was avoided, and improved patient compliance was present during the fixation or consolidation phase (because there was no external component). These observations were in accordance with the findings of Douglas, Burton, and Smith,<sup>[12]</sup> who reported that intraoral appliances have had advantages over extraoral devices by not only reducing or eliminating the problems of facial scarring caused by transcutaneous pins, but also by avoiding the emotional and cosmetic disadvantages of an extraoral appliance. However, intraoral devices are somewhat difficult to place and their removal could be as difficult as the initial placement.

Six patients had facial asymmetry due to temporomandibular joint ankylosis. From these six patients, two patients were treated simultaneously for ankylosis and facial asymmetry and a satisfactory result was obtained. Rao *et al.*,<sup>[13]</sup> have reported that in the patients with temporomandibular joint ankylosis, simultaneous gap arthroplasty and distraction osteogenesis was a useful and effective technique for the management of the mandibular deformity.

Bone transportation was done in two patients. Although the complete defect could not be covered by bone lengthening, but the advantage was that less amount of graft was needed to reconstruct the defect, which decreased the chances of donor site morbidity and more soft tissue coverage was available, which increased the possibility of the success of the graft. Block and Otten<sup>[14]</sup> have also reported that in one of their patients treated with bone transportation, a defect was left that required grafting, but the definite advantage was that the required bone grafts were small and were easily managed.

**Table 7: Mean values of parameters in COGS analysis of hard tissue**

Parameters	Mean $\pm$ Standard deviation		P value (Paired 't' test) Statistical significance of the difference between the means
	Pre distraction	Post distraction	
N-A-Pg	16.8 $\pm$ 2.57	12 $\pm$ 2.45	<0.05 (Significant)
N-B	-13.4 $\pm$ 4.69	-8.5 $\pm$ 4.24	<0.05 (Significant)
N-P	-17.8 $\pm$ 4.49	-12.7 $\pm$ 4.45	<0.05 (Significant)
ANS-Gn	55.4 $\pm$ 6.07	62 $\pm$ 6.24	<0.05 (Significant)
MP-HP	26 $\pm$ 5.14	29.9 $\pm$ 5.67	<0.05 (Significant)
Ar-Go	44.6 $\pm$ 4.19	51 $\pm$ 4.13	<0.05 (Significant)
Go-Pg	62.2 $\pm$ 6.96	71.8 $\pm$ 7.38	<0.05 (Significant)
B-Pg	3.1 $\pm$ 1.52	4.65 $\pm$ 2.45	>0.05 (Non-significant)
Ar-Go-Gn	121.3 $\pm$ 7.02	125 $\pm$ 6.58	<0.05 (Significant)
AB	-4.7 $\pm$ 2.86	-3 $\pm$ 2.05	<0.05 (Significant)

**Table 8: COGS analysis for soft tissue**

Values	Patient 1 (Distraction)		Patient 2 (Distraction)		Patient 3 (Distraction)		Patient 4 (Distraction)		Patient 5 (Distraction)		Patient 6 (Distraction)		Patient 7 (Distraction)		Patient 8 (Distraction)		Patient 9 (Distraction)		Patient 10 (Distraction)	
	Pre	Post	Pre	Post	Pre	Post	Pre	Post	Pre	Post	Pre	Post	Pre	Post	Pre	Post	Pre	Post	Pre	Post
G-Sn-Pg (angle)	35°	31°	28°	21°	22°	18°	21°	15°	30°	27°	20°	16°	23°	16°	23°	18°	21°	15°	32°	25°
G-Pg (mm)	-10	-6	-11	-6	-13	-8	-11	-6	-9	-4	-12	-8	-13	-7	-11	-5	-12	-7	-11	-6
G-Sn: Sn-Me (mm)	1.35	1.08	1.43	1.2	1.41	1.2	1.28	1.1	1.25	1.1	1.23	1.0	1.39	1.1	1.38	1.1	1.47	1.2	1.39	1.14
Li to (Sn-Pg) (mm)	4	3	4	2	5	3	8	4	5	4	8	4	9	4	5	2	6	3	7	4
Si to (Li-Pg) (mm)	5	6	3	4	2	5	7	9	3	4	6	7	5	8	4	7	3	5	4	6

Table depicts COGS analysis for soft tissue, Facial convexity angle (G-Sn-Pg) decreased after distraction, Value of G-Pg increased after distraction indicating increase in mandibular prognathism

In three patients, satisfactory facial aesthetics could not be obtained after distraction. These patients had noticeable chin deviation even after the completion of the distraction. This showed that the decision taken to stop activating the distractor, once the upper and lower midline coincided, needed a serious consideration, as it was not adequate to achieve results from the aesthetic point of view. In all the three patients, sliding genioplasty was done to correct the residual deformity. Wolfgang Losken<sup>[15]</sup> have stated that since most mandibular advancements were performed on children, a secondary distraction or orthognathic surgery might be required in the future.

The magnitude of lengthening registered on the distraction device did not correlate with the actual amount of bone distraction, which was less than anticipated and difficult to predict, prior to distraction. The amount of bone distraction during lengthening was a result of linear device activation altered by the effect of extrinsic and intrinsic biomechanical factors. Similar finding was observed by Williams and Rowe<sup>[16]</sup> in their studies. In the analysis for of the hard tissue, it was found that there was a marked increase in ramal height after distraction osteogenesis. This finding was also consistent with the observations of Molina,<sup>[17]</sup> Sawaki,<sup>[18]</sup> and Ortiz,<sup>[17]</sup> who also had observed the simultaneous growth and adaptation of soft tissue and hard tissue. Chin deviation was also corrected to a significant extent. In all the patients, there was an improvement in facial aesthetics. The grading of the distraction was done as No/Mild/Moderate, each for the morning and evening distraction. The grading increased from mild to moderate in successive distractions, it indicated an increasing mineralization, as the bone healing progressed. Ilizarov<sup>[6]</sup> reported that to allow proper mineralization, distraction should be carried out at an optimal rate. In the study, that we conducted, it was observed that more resistance was present during the morning. It could be due to the reduced functional movements (swallowing, chewing, speaking, etc.) at night.

No neurosensory disturbance was observed in any case. Block *et al.*<sup>[19]</sup> and Michieli and Miotti<sup>[20]</sup> have shown that slow, sustained traction on the inferior alveolar nerve has a minimal effect on the vascularity of the nerve and

**Table 9: Mean values of parameters in COGS analysis for soft tissue**

Parameters	Mean ± Standard deviation		P value (Paired 't' test) Statistical significance of the difference between the means
	Pre distraction	Post distraction	
G-Sn-Pg	25.5 ± 5.31	20.2 ± 5.63	<0.05 (Significant)
G-Pg	-11.3 ± 1.25	-6.3 ± 1.25	<0.05 (Significant)
G-Sn: Sn-Me	1.35 ± 0.079	1.12 ± 0.064	<0.05 (Significant)
Li to (Sn-Pg)	6.1 ± 1.79	3.3 ± 0.82	<0.05 (Significant)
Si to (Li-Pg)	4.2 ± 1.54	6.1 ± 1.66	<0.05 (Significant)

**Table 10: PA cephalogram**

Values	Patient 1 (Distraction)		Patient 2 (Distraction)		Patient 3 (Distraction)		Patient 4 (Distraction)		Patient 5 (Distraction)		Patient 6 (Distraction)		Patient 7 (Distraction)		Patient 8 (Distraction)		Patient 9 (Distraction)		Patient 10 (Distraction)	
	Pre	Post	Pre	Post	Pre	Post	Pre	Post	Pre	Post	Pre	Post	Pre	Post	Pre	Post	Pre	Post	Pre	Post
Co-Go	60	61	58	59	65	67	58	68	45	51	54	55	42	52	53	54	48	50	55	57
Right	41	47	40	48	43	54	59	69	54	54	40	47	60	61	35	48	43	50	46	56
Left	46	47	44	45	49	50	43	52	32	40	42	43	36	46	40	41	34	35	39	40
Go-Mm	40	45	36	43	35	46	45	54	40	41	41	47	50	51	29	41	24	35	31	39
Right	6	4	10	5	8	2	0	2	4	1	7	4	9	2	8	1	6	1	6	2
Left																				
Mm-VL																				

Table depicts the value of P.A. cephalogram; Value of Co-Go and Go-Mm is found to increase which represent an increase in ramal height and mandibular body length

**Table 11: Mean values of parameters in P. A. Cephalogram**

Parameters	Mean $\pm$ Standard deviation		P value (Paired 't' test) Statistical significance of the difference between the means
	Pre distraction	Post distraction	
Co-Go right	53.8 $\pm$ 7.08	57.4 $\pm$ 6.34	<0.05 (Significant)
Co-Go left	46.1 $\pm$ 8.59	53.4 $\pm$ 7.15	<0.05 (Significant)
Go-Mm right	40.5 $\pm$ 5.38	45.4 $\pm$ 4.37	<0.05 (Significant)
Go-Mm left	37.1 $\pm$ 7.75	44.2 $\pm$ 5.65	<0.05 (Significant)
Mm-VL	6.4 $\pm$ 2.83	2.4 $\pm$ 1.42	<0.05 (Significant)

**Table 12: Number of patients with resistance to movement**

	Morning		Evening	
	Mild (%)	Moderate (%)	Mild (%)	Moderate (%)
Day 1	12 (100)	0 (0)	12 (100)	0 (0)
Day 2	12 (100)	0 (0)	12 (100)	0 (0)
Day 3	12 (100)	0 (0)	12 (100)	0 (0)
Day 4	12 (100)	0 (0)	12 (100)	0 (0)
Day 5	9 (85)	3 (15)	12 (100)	0 (0)
Day 6	5 (42)	7 (58)	12 (100)	0 (0)
Day 7	4 (33)	8 (67)	11 (92)	1 (8)
Day 8	1 (8)	11 (92)	9 (85)	3 (15)
Day 9	0 (0)	12 (100)	7 (58)	5 (42)
Day 10	0 (0)	12 (100)	3 (15)	9 (85)
Day 11	0 (0)	12 (100)	2 (18)	10 (82)
Day 12	0 (0)	12 (100)	1 (8)	11 (92)
Day 13	0 (0)	12 (100)	0 (0)	12 (100)
Day 14	0 (0)	12 (100)	0 (0)	12 (100)
Day 15	0 (0)	12 (100)	0 (0)	12 (100)
Day 16	0 (0)	12 (100)	0 (0)	12 (100)
Day 17	0 (0)	12 (100)	0 (0)	12 (100)
Day 18	0 (0)	12 (100)	0 (0)	12 (100)
Day 19	0 (0)	12 (100)	0 (0)	12 (100)
Day 20	0 (0)	12 (100)	0 (0)	12 (100)
Day 21	0 (0)	12 (100)	0 (0)	12 (100)
Day 22	0 (0)	12 (100)	0 (0)	12 (100)
Day 23	0 (0)	12 (100)	0 (0)	12 (100)
Day 24	0 (0)	12 (100)	0 (0)	12 (100)
Day 25	0 (0)	12 (100)	0 (0)	12 (100)
Day 26	0 (0)	12 (100)	0 (0)	12 (100)

**Table 13: Complications**

Name of complication	No. of patients	Total no. of patients	% age
Paresthesia	0	12	0
Loosening of pins	2	12	17
Infection	2	12	17
Hardware failure	2	12	17
Scarring	10	2	83

significant myelin degeneration or axoplasmic swelling are also uncommon.

In one patient, at the end of active distraction, a proximal pin was found to be in the soft tissue. This happened because there was not sufficient bone around the posterior pin. In another patient, loosening of the pin was present due to the high speed drilling of the bone, which leads to bone necrosis at the bone and pin interface, and ultimately loosening of the pin. The infection might have occurred due to lack of care of the pin and their interface. McCarthy<sup>[21]</sup> and Molina<sup>[17]</sup> also pointed out that pin loosening and infections are were possible implications, but could be dealt by using oral

antibiotics. A possible explanation for the initial bending and then straightening of the distraction rod, was that, during the time of surgery, only the buccal cortical plate was osteotomized and a green stick fracture of the lingual cortical plate occurred, but it did not separate. The intact lingual cortical plate resisted the opening of the distractor, but the gradual pull by the distractor resulted in so much stretch that the fracture of lingual cortical plate took place. Molina and Monasterio<sup>[17]</sup> also had a similar experience in their patients. They reported that in most of their patients, an increase in the force to distract the intraosseous pins was required at the end of the second week. This suddenly decreased, requiring minimal effort to turn the screw, during the remaining distraction period. Molina and Monasterio assumed that this corresponded with the fracture of the internal cortical layer of the mandible.

Post distraction orthodontic treatment is very necessary for the alignment of the dentition over the alveolar bone, for eruption guidance, correction of laterognathism, and correction of maxillomandibular transverse disharmony. We can conclude that an inadequate consolidation period and a delay in orthodontic treatment are the reasons for relapse in one of the cases. Klein and Howaldt<sup>[1]</sup> have observed a relapse in one of their cases and have cited a delay in orthodontic treatment as its cause.

Retention plates should be given post distraction and orthodontic treatment should be started as soon as possible after removal of the distraction device, to guide proper occlusion and oppose any forces of relapse, as has been advised by McCarthy<sup>[11]</sup> and Klein.<sup>[1]</sup> Papageorge and Charalabos<sup>[22]</sup> used the functional appliance after removal of the distraction device to maintain the position of the jaw. Stability of the distracted fragment could be enhanced by internal rigid fixation.

## CONCLUSION

Like all surgical procedures, distraction osteogenesis also has some disadvantages. The distraction device has to remain in place for a period encompassing the lag, distraction, and healing period of the bone. This may have some psychological effect on a child. The external devices leave scars that result from the pin tracks in the skin. The absolute compliance of the patient and the family is of utmost importance, and close and frequent follow follow-up is needed. The high cost of the device may also be a disadvantage. Moreover, sometimes this procedure alone is not sufficient to achieve the desired results and additional surgeries have to be done.

Despite the disadvantages that have been mentioned, the advantages of this technique largely outweigh its

drawbacks. If the principles of osteodistraction set by Ilizarov and McCarthy *et al.* are followed closely, patients can have a greatly improved functional and aesthetic result, due to correction of the mandibular abnormalities. As new research findings and advances in technological development occur, these disadvantages will be minimized.

## ACKNOWLEDGMENT

We gratefully acknowledge the guidance and support given by Dr. Nageshwar Iyer in conducting this study and Dr. Manish Goyal for providing the statistical support.

## REFERENCES

- Klein C, Howaldt HP. Lengthening of the hypoplastic mandible by gradual distraction in childhood-a preliminary report. *J Craniomaxillofac Surg* 1995;23:68-74.
- Troulis MJ, Padwa B, Kaban LB. Distraction osteogenesis: Past, present and future. *Facial Plast Surg* 1998;14:205-15.
- Klug CN, Millesi-Schobel GA, Millesi W, Watzinger F, Ewers R. Preprosthetic vertical distraction osteogenesis of the mandible using an L-shaped osteotomy and Titanium membranes for guided bone regeneration. *J Oral Maxillofac Surg* 2001;59:1302-8.
- Ilizarov GA. Basic principles of transosseous compression and distraction osteosynthesis. *Orthop Travmatol Protez* 1971;32:7-15.
- Ilizarov GA. The tension stress effect on the genesis and growth of tissues, Part I the influence of stability of fixation and soft-tissue preservation. *Clin Orthop Relat Res* 1989;238:249-81.
- Ilizarov GA. The tension stress effect on the genesis and growth of tissues. Part II the influence of rate and frequency of distraction. *Clin Orthop Relat Res* 1989;239:263-85.
- Ilizarov GA. Clinical application of the tension stress effect for limb lengthening. *Clin Orthop Relat Res* 1990;250:8-26.
- Burstone CJ, James RB, Legan H, Murphy GA, Norton LA. Cephalometrics for orthognathic surgery. *J Oral Surg* 1978;36:269-77.
- Legan HL, Burstone CJ. Soft tissue cephalometric analysis for orthognathic surgery. *J Oral Surg* 1980;38:744-51.
- Polley JW, Figueroa AA, Liou EJ, Cohen M. Longitudinal analysis of mandibular asymmetry in hemifacial microsomia. *Plast Reconstr Surg* 1997;99:328-39.
- Karp NS, McCarthy JG, Schreiber JS, Sissan HA, Thorne CH. Membranous bone lengthening: A serial histological study. *Ann Plast Surg* 1992;29:2-7.
- Douglas LR, Douglass JB, Smith PJ. Intraoral mandibular distraction osteogenesis in a patient with severe micrognathia secondary to TMJ ankylosis using a tooth and bone-anchored device: A case report. *J Oral Maxillofac Surg* 2000;58:1429-33.
- Rao K, Kumar S, Kumar V, Singh AK, Bhatnagar SK. The role of simultaneous gap arthroplasty and distraction osteogenesis in the management of temporomandibular joint ankylosis with mandibular deformity in children. *J Craniomaxillofac Surg* 2004;32:38-42.
- Block MS, Otten J, McLaurin D, Zoldos J. Bifocal distraction osteogenesis for mandibular defect healing: Case reports. *J Oral Maxillofac Surg* 1996;54:1365-70.
- Samchukov. Textbook – craniofacial distraction osteogenesis. USA: Mosby Publications; 2001.
- Williams JK, Rowe NM, Mackool RJ, Levine JP, Hollier LH, Longaker MT, *et al.* Controlled multiplanar distraction of the mandible. *J Craniomaxillofac Surg* 1998;9:504-13.
- Molina F, Ortiz-Monasterio F. Mandibular elongation, and remodelling by distraction: A farewell to major osteotomies. *Plast Reconstr Surg* 1995;96:825-40.
- Sawaki Y, Hagino H, Yamamoto H, Ueda M. Trifocal distraction osteogenesis for segmental mandibular defect: A technical innovation. *J Craniomaxillofac Surg* 1997;25:310-5.
- Block MS, Daire J, Stover J. Changes in the inferior alveolar nerve following mandibular lengthening in the dog using distraction osteogenesis. *J Oral Maxillofac Surg* 1993;51:652-60.
- Michieli S, Miotti B. Controlled gradual lengthening of mandible after osteotomy: *Minerva Stomatol* 1976;25:77-88.
- McCarthy JG, Schreiber J, Karp N, Thorpe CH, Grayson BH. Lengthening the human mandible by gradual distraction. *Plast Reconstr Surg* 1992;89:1-8.
- Papageorge MB, Apostolidis C. Simultaneous mandibular distraction and arthroplasty in a patient with TMJ ankylosis and mandibular hypoplasia. *J Oral Maxillofac Surg* 1999;57:328-33.

**How to cite this article:** Karun V, Agarwal N, Singh V. Distraction osteogenesis for correction of mandibular abnormalities. *Natl J Maxillofac Surg* 2013;4:206-13.

**Source of Support:** Nil. **Conflict of Interest:** None declared.