

Uterine granuloma involving the myometrium: Two case reports

Navneet Takkar, Pragya Goel, Irneet Kaur, Alka Sehgal

Departments of Pathology, Obstetrics and Gynaecology, Government Medical College and Hospital, Chandigarh, Haryana and Punjab, India

ABSTRACT

Uterine granulomas confined to the myometrium are uncommon. Granulomas maybe infectious, non-infectious or idiopathic in origin. They may be diffuse or focal in nature. In this report, we describe two cases of granulomas of diffuse variety involving the myometrium. The first case shows non-necrotizing granuloma probably related to previous instrumentation. The second case depicts caseating granulomas along with Leiomyoma of uterus.

Key Words: Granulomatous inflammation, myometrium, uterus

INTRODUCTION

Uterine granuloma is a rare entity and may be either focal or diffuse in nature. Focal granulomas are usually related to a previous biopsy or surgery.^[1] Diffuse granulomas represent a local reaction without an obvious cause or may be associated with infection or systemic granulomatous disorders. Infective conditions associated with uterine granulomas could be tuberculosis, atypical mycobacteria, endemic mycosis, cytomegalovirus infection and parasites.^[2-4] We report two cases of uterine granuloma, the first in which there was diffuse non-necrotizing granuloma. The second case showed diffuse granulomas with caseation in the myometrium and was positive for acid fast bacillus (AFB) stain.

CASE REPORTS

Case 1

A 50-year-old patient presented in August 2010 with heavy and irregular bleeding per vaginum for last 10 months. She had undergone dilatation and curettage (D and C) and cervical biopsy in December 2009 for menorrhagia. Histopathology showed a disordered proliferative phase with chronic cervicitis. Patient received medical management with temporary relief. She had a second episode of menometrorrhagia in March 2010 followed by a repeat D and C. The endometrial curettings was reported as simple hyperplasia without atypia. Her general, local

examination and routine investigations were normal.

A total abdominal hysterectomy with bilateral salpingo-oophorectomy was performed and the patient was discharged in satisfactory condition on eighth post-operative day. Histology revealed endometrium in proliferative phase and myometrium showed multiple non-necrotizing epithelioid cell granulomas. Stain for AFB, fungal organisms were negative [Figure 1]. No cytomegalovirus inclusion bodies were seen and there was no evidence of vasculitis. Uterine cervix showed chronic cervicitis and bilateral adnexa were unremarkable. Workup for systemic disorders i.e., tuberculosis, vasculitis and sarcoidosis was negative. Patient was asymptomatic at 6 weeks and one year follow-up.

Case 2

A 40-year-old presented with pain and mass lower abdomen of five months duration with no menstrual irregularity. General physical examination was normal, local examination was suggestive of fibroid corresponding to size of 18 weeks pregnant uterus. Her routine investigations were normal. Ultrasonography revealed a large single intramural fibroid 10 × 9.7cm with thin endometrium and normal ovaries. Ultrasound guided FNAC was consistent

Address for Correspondence: Dr. Navneet Takkar,
House no.125-A, Sector 24-A, Chandigarh,
Haryana and Punjab, India.
E-mail: navneet@doctor.com

Access this article online

Quick Response Code:



Website:
www.jmidlifehealth.org

DOI:
10.4103/0976-7800.109643

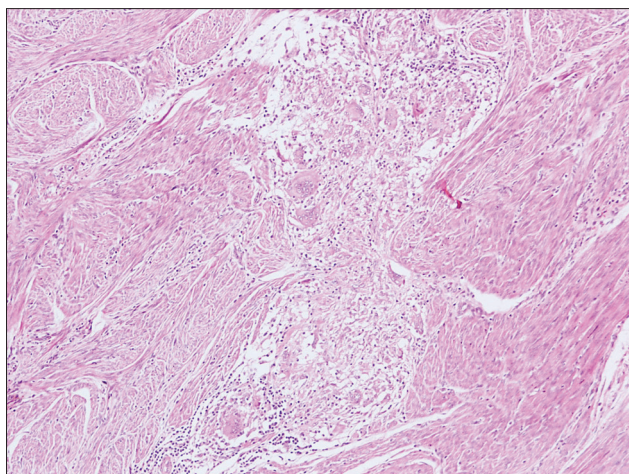


Figure 1: Photomicrograph showing non-caseating epithelioid cell granulomas with multinucleated giant cells present in the myometrium (H and E, ×200)

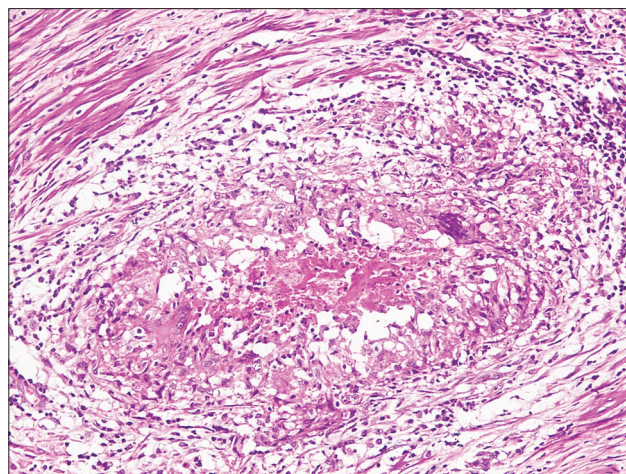


Figure 2: Photomicrograph showing a caseating epithelioid cell granuloma (H and E, ×400)

with findings of leiomyoma. Patient underwent a total abdominal hysterectomy. Histopathological examination revealed endometrium in secretory phase, uterine tumor as leiomyoma and in addition myometrium showed caseating epithelioid granulomas along with Langerhans and foreign body giant cells [Figure 2]. Stain for AFB was positive. Screening for tuberculosis elsewhere in the body was negative. Patient was started on ATT despite hysterectomy and absence of tuberculosis elsewhere because the adnexa was left behind where the possibility of a tubercular focus could not be ruled out. Currently patient has completed Category I DOTS therapy and asymptomatic on follow-up.

DISCUSSION

Granulomas of uterine corpus and cervix are an uncommon histopathological finding. Uterine granuloma involving myometrium is rare. When clinicians encounter patients with granulomatous inflammation, they are faced with a diagnostic dilemma to determine its cause. A variety of infectious and non-infectious conditions are associated with granuloma formation. Non infectious conditions include granulomatous inflammation following surgical instrumentation, foreign body reaction, systemic granulomatous disorders like sarcoidosis, systemic vasculitides like giant cell arteritis or may be idiopathic i.e., without an obvious underlying cause.^[5-7] The first case in our study showed diffuse granulomatous lesions in myometrium of non-necrotizing variety. There was history of surgical intervention for uterine bleeding in the form of Dilatation and Curettage done twice at an interval of three months. A 10 year retrospective study by Hoff *et al.*, showed that 8 of 11 patients with incidental granulomas of the uterus had a known history of instrumentation, which consisted of dilatation and curettage ($n = 4$), endometrial biopsy ($n = 2$), hysterosalpingogram ($n = 1$)

and hysteroscopy ($n = 1$).^[8] Four of these patients had more than one episode of instrumentation. None of the patients had clinical evidence of sarcoidosis or systemic infection and stains for microorganisms were negative. The clinical scenario of the first case correlates with this study where well formed, non-necrotizing granulomas of the uterus were found with a history of instrumentation. The patient had endometrial defects as shown on histopathology which can explain all the clinical features. It is highly unlikely that the uterine granuloma accounted for this clinical presentation.

Similarly there was no evidence of systemic granulomatous disease or tuberculosis based on clinical and laboratory evidence. Hence a history of instrumentation may explain the presence of uterine granulomas in the first case.

Despite its contiguity with endometrium, myometrial involvement is seldom seen in genital tract tuberculosis. Sinha *et al.*, reported a case of myometrial tuberculosis detected on sonography as multiple anechoic areas of variable size with well defined borders scattered throughout the myometrium.^[9] Histopathological examination of endometrial curettages were suggestive of tuberculosis. After receiving antitubercular treatment patient was relieved of menorrhagia and a repeat sonogram showed a homogenous myometrium with absence of anechoic areas. The second case presented with a pelvic mass suggestive of Leiomyoma, confirmed on FNAC and had no menstrual complaint. There was incidental detection of tubercular granulomatous inflammation of myometrium along with Leiomyoma in this case. Surprisingly her endometrium was in secretory phase and did not show any granuloma formation. Nogales-Ortiz *et al.*, in a 31 year study on pathology of female genital tuberculosis reported that microscopic involvement of myometrium was observed

in 20% of the cases.^[2] In the Indian context, tuberculosis remains the most common cause of diffuse granulomas since two thirds of tuberculosis cases in South East Asia are found here. Misra *et al.*, reviewed 5,085 biopsy specimens (3,510 endometrial and 1,575 cervical) of these 28 endometrial and 2 cervical biopsy specimens were reported as granulomatous inflammation, consistent with tuberculosis. Myometrial involvement was not observed in any of the endometrial biopsy specimens in which myometrium was included.^[10] This supports the infrequent involvement of myometrium in genital tuberculosis.

To conclude, uterine granuloma involving myometrium is rare. There is need for awareness about instrumentation causing granuloma formation, and also to look for an additional pathology such as tubercular granuloma which may present as an incidental finding warranting therapy.

REFERENCES

1. Almoujahed MO, Briski LE, Prysak M, Johnson LB, Khatib R. Uterine granulomas: Clinical and pathological features. *Am J Clin Pathol* 2002;117:771-5.
2. Nogales-Ortiz F, Tarancón I, Nogales FF Jr. The pathology of

- female genital tuberculosis. A 31-year study of 1436 cases. *Obstet Gynecol* 1979;53:422-8.
3. Bylund DJ, Nanfro JJ, Marsh WL Jr. Coccidioidomycosis of female genital tract. *Arch Pathol Lab Med* 1986;110:232-5.
4. Frank TS, Himebaugh KS, Wilson MD. Granulomatous endometritis associated with histologically occult cytomegalovirus in a healthy patient. *Am J Surg Pathol* 1992;16:716-20.
5. DiCarlo FJ Jr, DiCarlo JP, Robboy SJ, Lyons MM. Sarcoidosis of the uterus. *Arch Pathol Lab Med* 1989;113:941-3.
6. Hernández-Rodríguez J, Tan CD, Rodríguez ER, Hoffman GS. Gynecologic vasculitis: An analysis of 163 patients. *Medicine (Baltimore)* 2009;88:169-81.
7. Kelly P, McCluggage WG. Idiopathic uterine Granulomas: Report of a series with morphological similarities to idiopathic ovarian cortical granulomas. *Int J Gynecol Pathol* 2006;25:243-6.
8. Hoff E, Prayson RA. Incidental granulomatous inflammation of the uterus. *South Med J* 2002;95:884-8.
9. Sinha R, Gupta D, Tuli N. Genital tract tuberculosis with myometrial involvement. *Int J Gynaecol Obstet* 1997;57:191-2.
10. Mishra K, Wadhwa N. Uterine granulomas: Tuberculosis an important cause. *Am J Clin Pathol* 2002;118:966-7.

How to cite this article: Takkar N, Goel P, Kaur I, Sehgal A. Uterine granuloma involving the myometrium: Two case reports. *J Mid-life Health* 2013;4:60-2.

Source of Support: Nil, **Conflict of Interest:** None declared.

Staying in touch with the journal

1) Table of Contents (TOC) email alert

Receive an email alert containing the TOC when a new complete issue of the journal is made available online. To register for TOC alerts go to www.jmidlifehealth.org/signup.asp.

2) RSS feeds

Really Simple Syndication (RSS) helps you to get alerts on new publication right on your desktop without going to the journal's website. You need a software (e.g. RSSReader, Feed Demon, FeedReader, My Yahoo!, NewsGator and NewzCrawler) to get advantage of this tool. RSS feeds can also be read through FireFox or Microsoft Outlook 2007. Once any of these small (and mostly free) software is installed, add www.jmidlifehealth.org/rssfeed.asp as one of the feeds.