


Case Report

Non-ischemic priapism following recurrent idiopathic ischemic priapism treated successfully with selective arterial embolization and postoperative vacuum therapy before delayed inflatable penile prosthesis placement: A single case report

Francesco Del Giudice,¹  Gian Maria Busetto,¹ Benjamin I Chung,² Simon L Conti,² Matteo Ferro,³ Martina Maggi,¹ Alessandro Sciarra,¹ Paul E Perito,⁴ Martin S Gross,⁵ Gabriele Antonini¹ and Ettore De Berardinis¹

¹Department of Urology, “Sapienza” Rome University, Policlinico Umberto I, Rome, Italy, ²Department of Urology, Stanford University Medical Center, Stanford, California, USA, ³Division of Urology, European Institute of Oncology, Milan, Italy, ⁴Department of Urology, Coral Gables Hospital, Coral Gables, Florida, and ⁵Section of Urology, Dartmouth-Hitchcock Medical Center, Lebanon, New Hampshire, USA

Abbreviations & Acronyms

ED = erectile dysfunction
 EDITS = erectile dysfunction inventory of treatment satisfaction
 IIEF-5 = International Index of Erectile Function-5
 IP = ischemic priapism
 IPP = inflatable penile prosthesis
 MRI = magnetic resonance imaging
 NIP = non-ischemic priapism
 PD = Peyronie disease
 PGE1 = prostaglandin-E1
 ROS = reactive oxygen species
 US = ultrasound
 VED = vacuum erectile device

Introduction: Priapism is defined as a persistent tumescence or erection of the penis not associated to sexual desire and/or stimulation. Idiopathic recurrent priapism may also occasionally follow treatment of veno-occlusive priapism and represents a diagnostic and therapeutic challenge.

Case presentation: We report a single case of non-ischemic priapism that resulted after distal shunting procedure for severe and prolonged ischemic priapism and yet occurred without evidence of a cavernosal–sinusoidal fistula that was successfully treated with a bilateral selective arterial embolization. Our protocol of delayed inflatable penile prosthesis placement after a vacuum erectile device program was implemented.

Conclusions: The continuing use of a vacuum erectile device represented a bridge and an adjuvant therapy useful to facilitate later prosthesis placement. Anatomical and functional outcomes were optimal. No postoperative complaints or complications were reported.

Key words: erectile dysfunction, inflatable penile prosthesis, ischaemic priapism, non-ischemic priapism, vacuum erectile devices.

Correspondence: Francesco Del Giudice M.D., Department of Urology, “Sapienza” Rome University, Policlinico Umberto I, Viale del Policlinico 155, 00161 Rome, Italy. Email: francesco.delgiudice@uniroma1.it

This is an open access article under the terms of the Creative Commons Attribution-NonCommercial-NoDerivs License, which permits use and distribution in any medium, provided the original work is properly cited, the use is non-commercial and no modifications or adaptations are made.

Received 27 June 2018; accepted 31 August 2018.
 Online publication 20 September 2018

Keynote message

- 1 Vacuum erectile devices in the management of erectile dysfunction.
- 2 Delayed inflatable penile prosthesis placement after a single prolonged episode of priapism.
- 3 Prevention of pseudo-coffin effect and postoperative penile shortening after penile prosthesis placement.

Introduction

Priapism is defined as a persistent tumescence or erection of the penis not associated to sexual desire and/or stimulation.¹ Idiopathic recurrent priapism may also occasionally follow treatment of veno-occlusive priapism and represents a diagnostic and therapeutic challenge.^{1,2}

In protracted ischemic IP, when an MRI or a corporal biopsy show evidence of corporal smooth muscle fibrosis, immediate prosthesis implantation can be considered. This procedure carries potential complications such as distal erosion, cavernositis, and prosthesis infection.³ These risks must be weighed against delayed prosthesis placement, which can result in technical difficulties due to severe corporal fibrosis.⁴

We report a single case of NIP that resulted after distal shunting procedure for severe and prolonged IP and yet occurred without evidence of a cavernosal–sinusoidal fistula. For

definitive treatment of the patient's postoperative ED, we utilized a combined approach merging the mechanical traction of VED therapy before delayed IPP placement.

Case Report

A 47-year-old Caucasian man with no medical history presented to the Emergency Room of our Hospital with a painful sustained erection lasting 48 h. He denied any drug use and had no history of trauma or sickle cell disease. Corporal aspiration revealed dark cavernosal blood, and blood gas analysis showed a low oxygen partial pressure and high carbon dioxide partial pressure. Color Doppler US of the penis was performed to confirm the diagnosis of IP and showed the absence of blood flow in the cavernous arteries.

Treatment of IP was performed with repeated cycles of cavernous aspiration and irrigation with saline and then with 3–4 doses of 200 µg/mL phenylephrine, which resulted in partial detumescence. The erection returned within 20 min, and surgical management was deemed necessary. An Al Ghorrab shunt was performed, along with the Burnett corporal snake maneuver using a size 8 Hegar dilator, resulting in complete detumescence.⁵

After 3 days of complete detumescence the patient developed another episode of acute priapism with a painful and clinical nearly complete erection. Color Doppler US of the penis revealed the appearance of high bilateral cavernosal arterial flow state (right cavernosal: 61 cm/s; left cavernosal: 58 cm/s; Fig. 1a). An MRI of the corpora showed the diffuse presence of penile fibrosis, confirmed the high flow state but no evidence of cavernosal–sinusoidal fistula was detected (Fig. 1b).

Because of the evidence of non-viable cavernosal tissue demonstrated by the MRI study and in accordance to patient's wish we decided to immediately perform a bilateral arterial embolization of the cavernosal trunks using an absorbable gelatin sponge material (Spongostan®; Ethicon Inc., Somerville, NJ, USA) with the aim to definitively resolve the patient's new clinical condition (Fig. 1c). Penile detumescence occurred within 1 h after the procedure. The penis remained detumescent without any spontaneous erections after embolization.

A VED usage program was implemented 2 weeks after discharge in order to stretch the fibrotic penis and to facilitate delayed IPP placement. The patient was asked to purchase and use a vacuum device for a 12-week period (Medis®; Vacuum Therapy Devices, Milan, Italy) without the constriction ring

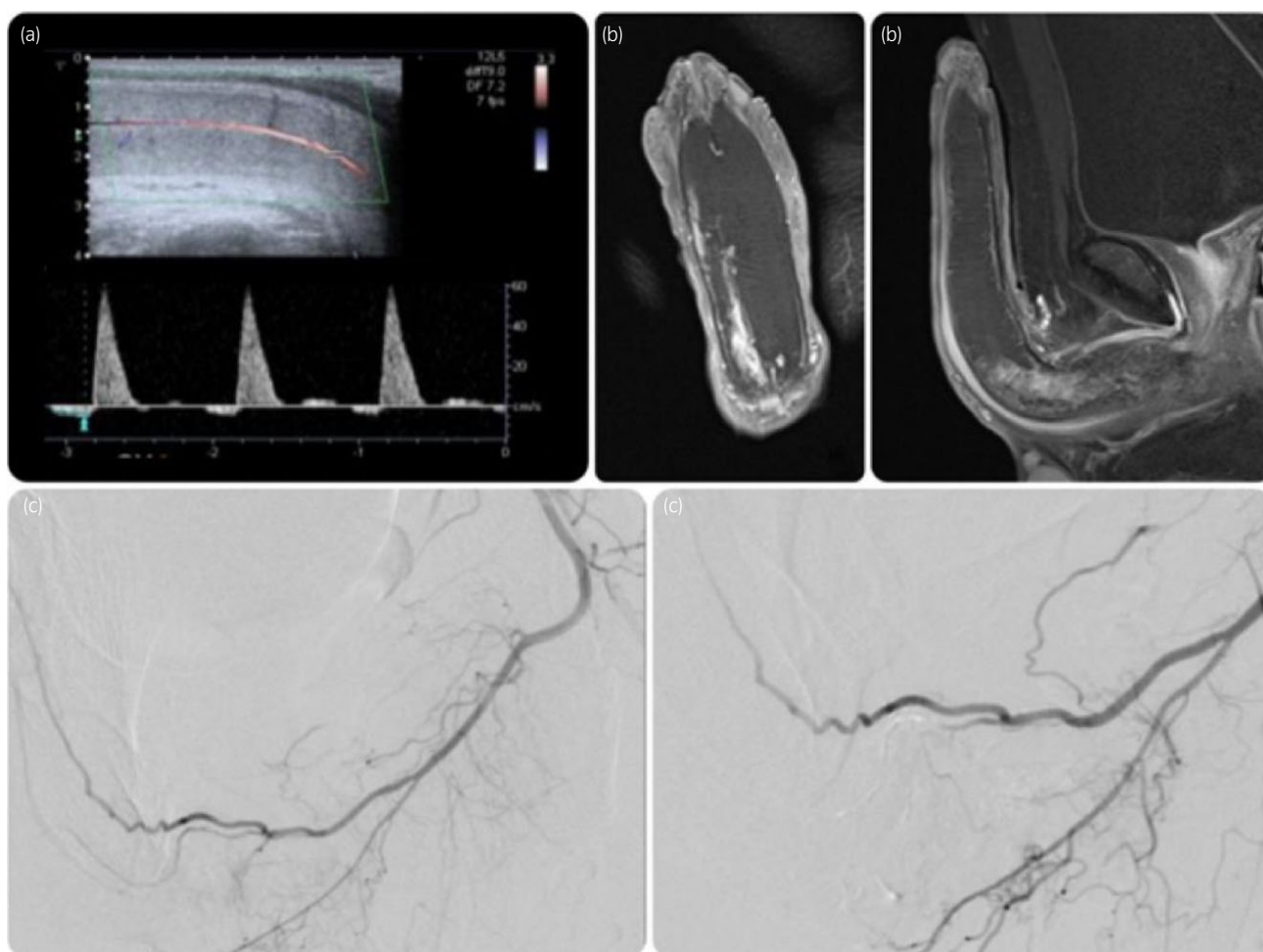


Fig. 1 (a) Color Doppler US revealing high-velocity flow (61 cm/s) in the right cavernosal artery at priapism recurrence; (b) MRI of the penis after gadolinium administration at priapism recurrence; (c) before and after super selective embolization of the left cavernosal trunk.

for 5 min twice daily. Penile length, defined as distance from the pubic bone to the urethral meatus along the dorsum of the stretched flaccid penis, was recorded at the beginning and at the end of the scheduled VED program. A significant improvement in penile length was achieved (10.5 vs 12 cm). During the treatment period, IIEF-5 score of 7 was reported. No adverse events were associated with VED therapy.

At the end of the scheduled VED program, the patient underwent AMS™ (Boston Scientific, Marlborough, MA, USA) LGX 700™ IPP placement with a minimally invasive infrapubic approach.⁶ At 6-month follow-up from IPP placement, the patient's IIEF-5 and EDITS scores were 23 and 74 respectively. Penile length with maximal inflation of the device was 12.7 cm.

Discussion

NIP generally occurs after perineal or penile trauma resulting in a laceration in the cavernosal artery and leading to a fistula between the artery and the lacunar spaces of the sinusoidal tissue.⁷

The presence of a high-flow state without color Doppler US and/or angiographic evidence of cavernosal–sinusoidal fistula has also been described.⁸ In our patient this scenario seemed to be confirmed by the preoperative Doppler US and MRI studies, as well as the intraoperative selective pudendal arteriogram, each of which were negative for the presence of any lacunar arterio-sinusoidal communication. This particular condition is extremely rare and pathophysiologically controversial, in that it suggests that in long-standing erections, permanent damage to the penile microvascular system may change IP into the NIP type.⁹ In their animal model, Munarriz *et al.* demonstrated how reestablishing corporal blood flow during the management of IP is associated with reperfusion of ischemic tissues with increase in corporal oxygen tension generating ROS, which may cause tissue damage and local alterations of PGE1 production. These local microenvironment modifications may interfere with the recovery of the cavernosal tissue and could potentially play a role in the development of the NIP.¹⁰ In their retrospective series of NIP following perineal trauma, Hisasue *et al.* reported how a conservative management could itself be effective for the clinical resolution and that in case of embolization, an autologous clot material seemed to be able to prevent the “permanent erection” complication.¹¹ In our case we retained that the immediate selective arterial embolization had to be considered the first choice of treatment considering the patient's extreme and low likelihood of erectile function recovery. In this situation, the patient rejected immediate semi-rigid prosthetic device placement and decided on delayed IPP placement after a VED program.

Late IPP implantation can result in well-described technical difficulties due to the development of severe corporal fibrosis, with high rates of revision surgery.^{1,2,5} As a result, we emphasized the need for an adjunct therapy for the prevention of the fibrotic corporal retraction in order to potentially ease IPP placement. At the same time one of the most common and prevalent complaints following prosthesis surgery is penile length loss, especially for conditions related to fibrosis.

Even if different rehabilitation programs based on VED have been previously described for other conditions like PD, to our knowledge there is no consensus in literature on how to facilitate IPP insertion and to obtain optimal functional results after severe cases of priapism.¹²

Mechanical VED traction therapy to model the corpora cavernosa has been firmly established in the literature. In their large retrospective analysis, Sellers *et al.* demonstrated how a preoperative VED application before IPP placement promoted several benefits and in particular this daily traction exercise was associated with increased ease of corpus cavernosum dilation, accommodation of larger cylinders, and finally with improved patient satisfaction with postoperative length.¹³

In our experience the continuing use of a VED represented a bridge and an adjuvant therapy useful to facilitate later prosthesis placement. Further study is needed to elucidate the utility of VED in improving the microscopic compliance of the areolar cavernosal tissue and the collateral oxygenation of the spongiosum tissue of the penis. We feel that this treatment method merits further evaluation with similar cases.

Conflict of interest

The authors declare no conflict of interest.

References

- Montague DK, Jarow J, Broderick GA *et al.* American Urological Association guideline on the management of priapism. *J. Urol.* 2003; **170**: 1318–24.
- Berger R, Billups K, Brock G *et al.* Report of the American Foundation for Urologic Disease (AFUD) Thought Leader Panel for evaluation and treatment of priapism. *Int. J. Impot. Res.* 2001; **13**(Suppl 5): S39–43.
- El-Bahnasawy MS, Dawood A, Farouk A. Low-flow priapism: risk factors for erectile dysfunction. *BJU Int.* 2002; **89**: 285–90.
- Zacharakis E, Garaffa G, Raheem AA *et al.* Penile prosthesis insertion in patients with refractory ischaemic priapism: early vs delayed implantation. *BJU Int.* 2014; **114**: 576–81.
- Burnett AL, Pierorazio PM. Corporal “snake” maneuver: corpora-glanular shunt surgical modification for ischemic priapism. *J. Sex. Med.* 2009; **6**: 1171–6.
- Antonini G, Busetto GM, De Berardinis E *et al.* Minimally invasive infrapubic inflatable penile prosthesis implant for erectile dysfunction: evaluation of efficacy, satisfaction profile and complications. *Int. J. Impot. Res.* 2016; **28**: 4–8.
- Witt MA, Goldstein I, Saenz de Tejada I *et al.* Traumatic laceration of intracavernosal arteries: the pathophysiology of non-ischemic, high flow, arterial priapism. *J. Urol.* 1990; **143**: 129–32.
- Seftel AD, Haas CA, Brown SL *et al.* High flow priapism complicating veno-occlusive priapism: pathophysiology of recurrent idiopathic priapism? *J. Urol.* 1998; **159**: 1300–1.
- Pryor J, Akkus E, Alter G *et al.* Priapism. *J. Sex. Med.* 2004; **1**: 116–20.
- Munarriz R, Park K, Huang YH *et al.* Reperfusion of ischemic corporal tissue: physiologic and biochemical changes in an animal model of ischemic priapism. *Urology* 2003; **62**: 760–4.
- Hisasue S, Kobayashi K, Kato R *et al.* Clinical course linkage among different priapism subtypes: dilemma in the management strategies. *Int. J. Urol.* 2008; **15**: 1006–10.
- Antonini G, De Berardinis E, Del Giudice F *et al.* Inflatable penile prosthesis placement, scratch technique and postoperative vacuum therapy as a combined approach to definitive treatment of Peyronie's disease. *J. Urol.* 2018; <https://doi.org/10.1016/j.juro.2018.04.060>.
- Sellers T, Dineen M, Wilson SK. Vacuum preparation protocol and cylinders that lengthen allows implantation of longer cylinders reducing complaints of shortened penile length following implantation. *J. Sex. Med.* 2009; **6**: 447–9.