

Received: 2019.04.09
Accepted: 2019.09.18
Published: 2019.10.04

Serum C-Reactive Protein and Max Polyp Diameter Are Useful Markers of Complications of Small-Intestinal Polypectomy

Authors' Contribution:
Study Design A
Data Collection B
Statistical Analysis C
Data Interpretation D
Manuscript Preparation E
Literature Search F
Funds Collection G

ABCDEF **Jiangfeng Tu**
ABCDEF **Huiqin Gao**
ABCDEF **Wensheng Pan**

Department of Gastroenterology, Zhejiang Provincial People's Hospital, People's Hospital of Hangzhou Medical College, Hangzhou, Zhejiang, P.R. China

Corresponding Author: Wensheng Pan, e-mail: wspan223@163.com
Source of support: Major Medical Health Science and Technology Project of Zhejiang Province (No. 291825894)

Background: This study aimed to identify the risk factors of complications after small-intestinal polypectomy by single-balloon enteroscopy (SBE), and to assess the value of serum C-reactive protein (CRP) and the max polyp diameter (Dmax) in predicting postoperative complications of small-intestinal polypectomy.

Material/Methods: Between April 2017 and April 2018, clinical data from 37 patients who underwent small-intestinal polypectomy were retrospectively analyzed.





Results: Thirty-seven small-intestinal polypectomy procedures (18 oral and 19 anal) were carried out in 37 patients (M: F 20: 17; age 35.6±13.0 years). A total of 1081 small-intestine polyps were removed. Three patients (8.1%) had bleeding and 3 patients (8.1%) had perforation after small-intestinal polypectomy. Based on multivariate logistic analysis, CRP [1.104 (95% CI 1.022–1.191)] was the only risk factor for complications among the patients. According to the area under the receiver operating characteristic (AUROC) curve, CRP (27.5 mg/L), Dmax (3.5 cm), and the combination of CRP + Dmax appear to be predictive factors for complications after small-intestinal polypectomy.

Conclusions: SBE is an effective endoscopic tool for patients with small-intestinal polyps. CRP, Dmax, and the combination of CRP+Dmax may be potential predictors of complications from small-intestinal polypectomy.

MeSH Keywords: **C-Reactive Protein • Intestine, Small • Postoperative Complications**

Abbreviations: **CRP** – C-reactive protein; **DAE** – device-assisted enteroscopy; **CE** – capsule endoscopy; **SBE** – single-balloon enteroscopy; **DBE** – double-balloon enteroscopy; **IRB** – Institutional Review Board; **ROC** – receiver operating characteristic; **PJS** – Peutz-Jeghers syndrome; **Dmax** – the max polyp diameter

Full-text PDF: <https://www.medscimonit.com/abstract/index/idArt/917062>

 1085  3  2  13



Background

Patients with small-intestinal polyps are always difficult to treat due to the length, tortuosity, and location of the small bowel. Small-bowel exploration has been drastically revolutionized by device-assisted enteroscopy (DAE) [1].

Compared with capsule endoscopy (CE), which is only a diagnostic technique, single-balloon enteroscopy (SBE) and double-balloon enteroscopy (DBE) are used to diagnose and treat diseases of the small intestine, such as Crohn's disease, polypectomy, and bleeding [2–5]. Three studies performed meta-analyses to determine the diagnostic and therapeutic yields of DBE and SBE; all 3 studies reported that both DBE and SBE had similar diagnostic and therapeutic fields [6–8].

To the best of our knowledge, there are few studies on the role of SBE in adults with small-intestinal polyps in China. In this study, we retrospectively studied cases from our medical experience and analyzed the function of SBE and the risk factors of complications after small-intestinal polypectomy.

Material and Methods

All patients who received SBE treatment for small-intestinal polyps found by small-bowel CT scan at Zhejiang Provincial People's Hospital from April 2017 to April 2018 were eligible for the study. Patients were excluded if they had concomitant infection (fever, positive stool culture, positive blood culture, infiltrates on chest x-ray examination, or documented skin infection) before SBE. The clinicopathological factors included age, sex, the route of SBE, CRP tested on the second morning after SBE, polyp number, the max polyp diameter (Dmax), and complications. The endoscopist had already performed about 30 small-bowel polypectomies prior to conducting this study.

Ethical issues

This study was reviewed and approved by the Institutional Review Board (IRB) of Zhejiang Provincial People's Hospital (approval number KY2018008). Patient identification numbers were used to collect and analyze clinical records. Personal information was anonymized and de-identified prior to analysis.

Single-balloon enteroscopy

All examinations were carried out while patients were under general anesthesia, with endotracheal intubation by Olympus SIF Q260. For both antegrade and retrograde approaches, a standard bowel preparation with polyethylene glycol (30–40 mL/kg/h) was required [9]. Adverse effects that occurred within 30 days after the excision of polyps from the

Table 1. Clinical and demographic characteristics of patients.

| Characteristics | |
|------------------------------|-----------|
| Patients (n) | 37 |
| Sex (M: F) | 20: 17 |
| Age (years) | 35.6±13.0 |
| Small intestine polyps (n) | 29.2±57.2 |
| Route of SBE (Oral, Anal)(n) | 19: 18 |
| Complications | 6 (16.2%) |
| Perforation (n,%) | 3 (8.1%) |
| Bleeding (n,%) | 3 (8.1%) |
| Follow-up (months) | 6.9±2.6 |

SBE – single-balloon enteroscopy.

small intestine were tracked by weekly telephone contact with the patients' family members.

Statistical analysis

All statistical analyses were performed using SPSS 20.0 software. Data are presented as the mean ± standard deviation (SD) or as geometrical means (95% confidence interval [CI]) for continuous variables and as percentages for categorical variables. General characteristics were compared among participants with and without CE using the *t* test. Categorical variables were analyzed via the chi-square test. Odds ratios (ORs) and 95% confidence intervals (CIs) were calculated using a logistic analysis of the risks of complications after small-intestinal polypectomy, and receiver operating characteristic (ROC) analysis was used to determine the cut-off points for CRP after small-intestinal polypectomy for postoperative complications. *P* values less than 0.05 were considered statistically significant.

Results

A total of 37 patients were included in the present study. The clinical and demographic characteristics of the patients are shown in Table 1. The site of polyps was the small bowel. The histology of polyps was hamartoma. We performed 18 antegrade and 19 retrograde approaches, which were all successfully performed. In our research, 16.2% (6/37) of patients had complications after small-intestinal polypectomy: 8.1% (3/37) of patients had bleeding, 8.1% (3/37) of patients had perforation, and 3 patients required emergency surgery after SBE resulting from perforation. During the follow-up, no patients required emergency surgery due to intussusception.

Patients were divided into 2 groups according to the presence of complications after small-intestinal polypectomy. The patients'

Table 2. Characteristic information of the complication group and no complication group after small intestinal polypectomy.

| | Complication (n=6) | No complication (n=31) | P value |
|------------------|--------------------|------------------------|---------|
| Age (ys) | 28.2±12.7 | 37.0±12.6 | 0.14 |
| Sex (M: F) | 3: 3 | 17: 14 | 0.83 |
| Polyp number (n) | 77.5±80.9 | 19.9±45.9 | 0.18 |
| Dmax (cm) | 6.0±3.2 | 3.3±2.2 | <0.05 |
| CRP (mg/L) | 87.0±77.2 | 8.3±8.5 | <0.05 |

Dmax – the max polyp diameter; CRP – C-reactive protein.

Table 3. Logistic analysis of the risks of complications.

| | Univariate logistic analysis | | Multivariate logistic analysis | |
|------|------------------------------|-------|--------------------------------|-------|
| | OR (95% CI) | P | OR (95% CI) | P |
| Dmax | 1.449 (1.029–2.041) | <0.05 | 1.891 (0.983–3.637) | 0.06 |
| CRP | 1.106 (1.005–1.218) | <0.05 | 1.104 (1.022–1.191) | <0.05 |

Dmax – the max polyp diameter; CRP – C-reactive protein.

basic characteristics are shown in Table 2 (characteristic information of the complication group and no complication group after small-intestinal polypectomy). There was no significant difference between the 2 groups based on age, sex, or polyp number ($P>0.05$). The max polyp diameter in the complication group (6.0 ± 3.2 cm) was larger than that of the no complication group (3.3 ± 2.2 cm, $P<0.05$). CRP in the complication group (87.0 ± 77.2 mg/L) was significantly higher than that of the no complication group (8.3 ± 8.5 mg/L, $P<0.05$). We found that Dmax (OR=1.449, 95% CI=1.029–2.041, $P<0.05$), and CRP (OR=1.106, 95% CI=1.005–1.218, $P<0.05$) were risk factors for fever after small-intestinal polypectomy by univariate logistic analysis, as shown in Table 3. Multivariate logistic regression showed that CRP (OR 1.104, 95% CI 1.022–1.191, $P<0.05$) was the only risk factor that predicted complications.

The ROC curve showed that CRP (≥ 27.5 mg/dl, AUC=0.858, sensitivity=83.3%, specificity=96.8%), Dmax (≥ 3.5 cm, AUC=0.750, sensitivity=83.3%, specificity=61.3%), and the combination of CRP+Dmax (AUC=0.984, sensitivity=100%, specificity=96.8%) were all predictors for the complications shown in Figure 1.

Discussion

To the best of our knowledge, this study is the first to address the therapeutic efficacy and safety of enteroscopic resection of small-intestinal polyps using SBE in China. Figure 2 shows the polypectomy operation. In our study, a total of 1081 small-intestinal polyps among 37 patients were removed; the complication rate was 16.2%, which is higher than previous studies reporting a 4.3–13.6% complication rate [10,11]. This supports

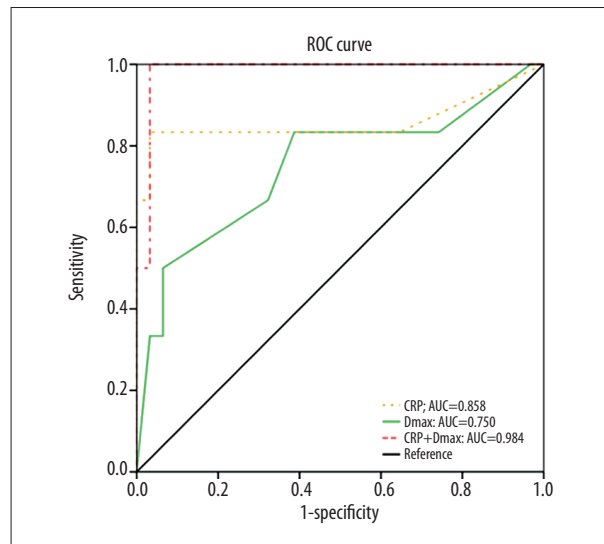


Figure 1. Receiver operating characteristic curves of CRP, Dmax, and the combination of CRP+Dmax for prediction of complications from small-intestinal polypectomy.

the therapeutic efficacy of SBE in treating exceptionally large polyps that are localized in the small intestine. We conclude that SBE could play an important role in small-intestinal polypectomy, which is consistent with a range of previous studies [5,7]. Our increased complication rate may be due to the larger polyps in our patients. The previous research also showed that polyp size was the only risk for complications [12]. It has been recently estimated that the cumulative risk for intussusceptions among patients with Peutz-Jeghers syndrome (PJS) is 33% by age 10 years and 50% by age 20 years due to the small size of intestinal polyps [13]. According to our study, SBE

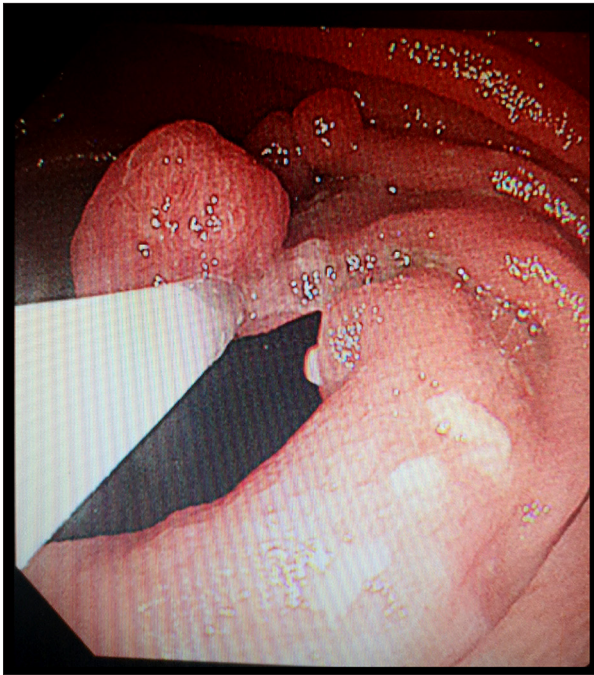

Figure 2. An image of the polypectomy operation.

References:

1. Rahmi G, Vinet MA, Perrod G et al: Efficacy of double-balloon enteroscopy for small-bowel polypectomy: Clinical and economic evaluation. *Therap Adv Gastroenterol*, 2017; 10: 465–72
2. Rondonotti E, Spada C, Adler S et al: Small-bowel capsule endoscopy and device-assisted enteroscopy for diagnosis and treatment of small-bowel disorders: European Society of Gastrointestinal Endoscopy (ESGE) Technical Review. *Endoscopy*, 2018; 50: 423–46
3. Koul A, Pham DM, Nanda A et al: Safety and efficacy of single-balloon enteroscopy in management of gastrointestinal bleeding in patients with a left ventricular assist device. *Endosc Int Open*, 2017; 5: E179–83
4. Pinto-Pais T, Pinho R, Rodrigues A et al: Emergency single-balloon enteroscopy in overt obscure gastrointestinal bleeding: Efficacy and safety. *United European Gastroenterol J*, 2014; 2: 490–96
5. Torroni F, Romeo E, Rea F et al: Conservative approach in Peutz-Jeghers syndrome: Single-balloon enteroscopy and small bowel polypectomy. *World J Gastrointest Endosc*, 2014; 6: 318–23
6. Wadhwa V, Sethi S, Tewani S et al: A meta-analysis on efficacy and safety: Single-balloon vs. double-balloon enteroscopy. *Gastroenterol Rep (Oxf)*, 2015; 3: 148–55
7. Kim TJ, Kim ER, Chang DK et al: Comparison of the efficacy and safety of single- versus double-balloon enteroscopy performed by endoscopist experts in single-balloon enteroscopy: A single-center experience and meta-analysis. *Gut Liver*, 2017; 11: 520–27
8. Lipka S, Rabbanifard R, Kumar A, Brady P: Single versus double balloon enteroscopy for small bowel diagnostics: A systematic review and meta-analysis. *J Clin Gastroenterol*, 2015; 49: 177–84
9. Bizzarri B, Borrelli O, de'Angelis N et al: Management of duodenal-jejunal polyps in children with Peutz-Jeghers syndrome with single-balloon enteroscopy. *J Pediatr Gastroenterol Nutr*, 2014; 59: 49–53
10. Ohmiya N, Nakamura M, Takenaka H et al: Management of small-bowel polyps in Peutz-Jeghers syndrome by using enteroclysis, double-balloon enteroscopy, and videocapsule endoscopy. *Gastrointestinal Endoscopy*, 2010; 72: 1209–16
11. Sakamoto H, Yamamoto H, Hayashi Y et al: Nonsurgical management of small-bowel polyps in Peutz-Jeghers syndrome with extensive polypectomy by using double-balloon endoscopy. *Gastrointest Endosc*, 2011; 74: 328–33
12. Goverde A, Wagner A, Korsche SE et al: Small-bowel surveillance in patients with Peutz-Jeghers syndrome: Comparing magnetic resonance enteroclysis and double balloon enteroscopy. *J Clin Gastroenterol*, 2017; 51(4): e27–33
13. Hinds R, Philp C, Hyer W, Fell JM: Complications of childhood Peutz-Jeghers syndrome: Implications for pediatric screening. *J Pediatr Gastroenterol Nutr*, 2004; 39: 219–20

may play an important role in small-bowel polyps for patients with PJS. In our study, we found that the maximum diameter of polyps was a risk factor for complications. Therefore, during SBE, the endoscopist should be especially careful if the patient has large small-intestinal polyps. Additionally, CRP, Dmax and the combination of CRP+Dmax are potential markers for predicting complications. For patients with CRP >27.5 mg/dl and Dmax >3.5 cm after small-intestinal polypectomy, additional monitoring is necessary to prevent bleeding and perforation.

The present study has several limitations. First, it was a single-center study with a small number of patients. Second, the dedicated endoscopist had technical mastery in performing small-intestinal polypectomy; the availability of equipment and well-trained endoscopists may limit the widespread use of small-intestinal polypectomy.

Conclusions

Single-balloon enteroscopy is an effective endoscopic tool for small-intestinal polypectomy. CRP, Dmax, and the combination of CRP+Dmax may be potential predictors of complications from small-intestinal polypectomy.