

Role of the optic nerve sheath diameter in the assessment of the effectiveness of decompressive surgery after malignant middle cerebral artery infarction

Papel do diâmetro da bainha do nervo óptico na avaliação da eficácia da cirurgia descompressiva após infarto maligno da artéria cerebral média

Ozgun Senol¹ Zeliha Cosgun² Emine Dagistan² Bekir Enes Demiryurek³ Seckin Emre Cancan¹

¹Bolu Abant Izzet Baysal University, Faculty of Medicine, Department of Neurosurgery, Bolu, Turkey.

²Bolu Abant Izzet Baysal University, Faculty of Medicine, Department of Radiology, Bolu, Turkey.

³Bolu Abant Izzet Baysal University, Faculty of Medicine, Department of Neurology, Bolu, Turkey.

Address for correspondence Bekir Enes Demiryurek (e-mail: bekirenes10@gmail.com).

Arq. Neuropsiquiatr. 2022;80(7):671–675.

Abstract

Background After a case of stroke, intracranial pressure (ICP) must be measured and monitored, and the gold standard method for that is through an invasive technique using an intraventricular or intraparenchymal device. However, The ICP can also be assessed through a non-invasive method, comprised of the measurement of the optic nerve sheath diameter (ONSD) through ultrasound (US).

Objective To evaluate the ICP of patients who underwent wide decompressive craniectomy after middle cerebral artery (MCA) infarction via preoperative and postoperative ONSD measurements.

Methods A total of 17 patients, aged between 34 and 70 years, diagnosed with malignant MCA infarction with radiological edema and mid-line shift, who underwent decompressive surgery, were eligible. From the records, we collected data on age, sex, preoperative and postoperative Glasgow Coma Scale (GCS) scores, National Institutes of Health Stroke Scale (NIHSS) score, the degree of disability in the preoperative period and three months postoperatively through the scores on the Modified Rankin Scale (MRS), and the preoperative and postoperative midline shift measured by computed tomography (CT) scans of the brain.

Keywords

- ▶ Middle Cerebral Artery
- ▶ Infarction
- ▶ Decompressive Craniectomy
- ▶ Optic Nerve Neoplasms

received
November 10, 2020
accepted
September 26, 2021

DOI <https://doi.org/10.1055/s-0042-1754345>.
ISSN 0004-282X.

© 2022. Academia Brasileira de Neurologia. All rights reserved. This is an open access article published by Thieme under the terms of the Creative Commons Attribution-NonDerivative-NonCommercial-License, permitting copying and reproduction so long as the original work is given appropriate credit. Contents may not be used for commercial purposes, or adapted, remixed, transformed or built upon. (<https://creativecommons.org/licenses/by-nc-nd/4.0/>)
Thieme Revinter Publicações Ltda., Rua do Matoso 170, Rio de Janeiro, RJ, CEP 20270-135, Brazil

Results Preoperatively, the mean GCS score was of 8 (range: 7.7–9.2), whereas it was found to be of 12 (range 10–14) on the first postoperative day ($p = 0.001$). The mean preoperative NIHSS score was of 21.36 ± 2.70 and, on the first postoperative day, it was of 5.30 ± 0.75 ($p < 0.001$). As for the midline shift, the mean preoperative value was of 1.33 ± 0.75 cm, and, on the first postoperative day, 0.36 ± 0.40 cm ($p < 0.001$). And, regarding the ONSD, the mean preoperative measurement was of 5.5 ± 0.1 mm, and, on the first postoperative day, it was of 5 ± 0.9 mm ($p < 0.001$).

Conclusion The ocular US measurement of the ONSD for the preoperative and postoperative monitoring of the ICP seems to be a practical and useful method.

Resumo

Antecedentes Após um acidente vascular cerebral (AVC), a pressão intracraniana (PIC) deve ser medida e monitorada, e o método padrão-ouro para isso é um procedimento invasivo por meio de um dispositivo intraventricular ou intraparenquimal. No entanto, a PIC também pode ser avaliada por um método não invasivo, composto da medida do diâmetro da bainha do nervo óptico (DBNO) por ultrassom (US).

Objetivo Avaliar a PIC de pacientes submetidos a craniectomia descompressiva ampla após infarto da artéria cerebral média (ACM) por meio das medidas do DBNO nos períodos pré e pós-operatório.

Métodos Um total de 17 pacientes, com idades entre 34 e 70 anos, diagnosticados com infarto maligno da ACM com edema radiológico e deslocamento da linha média, e que foram submetidos a cirurgia descompressiva, eram elegíveis. A partir dos prontuários, coletamos informações relativas à idade, gênero, pontuações pré e pós-operatórias na Escala de Coma de Glasgow (ECG), pontuação na escala de AVC dos National Institutes of Health (NIH), o grau de incapacidade no pré-operatório e após três meses da operação pelas pontuações na Escala de Rankin Modificada (ERM), e o desvio da linha média no pré e pós-operatório medido por tomografia computadorizada (TC) cerebral.

Resultados No pré-operatório, a pontuação média na ECG foi de 8 (variação: 7,7–9,2), e, no primeiro dia do pós-operatório, 12 (variação 10–14) ($p = 0,001$). A pontuação média na escala dos NIH foi de $21,36 \pm 2,70$ no pré-operatório, e de $5,30 \pm 0,75$ no primeiro dia de pós-operatório ($p < 0,001$). Quanto ao desvio da linha média, no pré-operatório ele teve uma média de $1,33 \pm 0,75$ cm, e de $0,36 \pm 0,40$ cm no primeiro dia de pós-operatório ($p < 0,001$). E o DBNO apresentou uma média pré-operatória de $5,5 \pm 0,1$ mm, e de $5 \pm 0,9$ mm no primeiro dia de pós-operatório ($p < 0,001$).

Conclusão A mensuração ocular do DBNO por US para o monitoramento da PIC no pré e no pós-operatório parece ser um método prático e útil.

Palavras-chave

- ▶ Artéria Cerebral Média
- ▶ Infarto
- ▶ Craniectomia Descompressiva
- ▶ Neoplasias do Nervo Óptico

INTRODUCTION

Despite recent advances in medical care, acute ischemic stroke (IS) still carries elevated mortality and morbidity rates.^{1,2}

Following acute the middle cerebral artery (MCA) occlusions, 1% to 10% of patients develop “malignant” MCA infarction, which may lead to a significant increase in intracranial pressure (ICP) and cerebral herniation.³

In some cases of MCA infarction, edema may present more rapidly and become more severe in the first 24 hours. Despite aggressive medical treatment, hemispheric infarctions have high mortality rates, ranging from 70% to 80%.^{1–3}

The prognosis of malignant MCA infarction is poor, comprising parenchymal injury, increased ICP, herniation, and secondary neuronal injury.⁴

Intracranial hypertension is defined as a cerebrospinal fluid (CSF) pressure ≥ 20 mmHg. The gold standard for measuring ICP is an invasive technique using an intraventricular or intraparenchymal device,^{5,6} which is neither suitable nor practical due to the serious complications, such as infections and increased risk of hemorrhage.⁶ Conversely, measuring the optic nerve sheath diameter (ONSD) through ocular ultrasonography (US) to identify increased ICP is a non-invasive method that has been reported^{5–7} to be more sensitive and specific when compared with the invasive techniques.

The literature^{5,8} states that the normal length of the ONSD in healthy individuals is < 4.5 mm, and values > 5 mm reflect an ICP > 20 mmHg.

The present study was designed to evaluate the ICP of patients who underwent wide decompressive craniectomy after MCA infarction through the preoperative and postoperative measurements of the ONSD by US.

METHODS

Patient selection

A retrospective search of our clinic's medical records from 2014 to 2018 was performed to obtain data on patients diagnosed with malignant MCA infarction with radiological edema and midline shift who underwent decompressive surgery before any noticeable neurological deterioration in the scores on the Glasgow Coma Scale (GCS) and the National Institutes of Health Stroke Scale (NIHSS).

A total of 17 patients between the ages of 34 and 70 years were eligible for inclusion. From the records, we collected data on age, sex, preoperative and postoperative GCS scores, NIHSS score, the degree of disability in the preoperative period and three months postoperatively through the scores on the Modified Rankin Scale (MRS), and the preoperative and postoperative midline shift measured by computed tomography (CT) scans of the brain. Midline shifts > 0.5 cm on the CT were considered significant. The MRS score was categorized as follows: 0 to 3–favorable; 4 to 5–unfavorable; and 6–dead.

Patients with significant contralateral infarction, cases with a major secondary hemorrhagic infarction that affected more than 50% of the MCA territory (including any previously-known coagulopathies with severe secondary infarction), history of elevated ICP (due to conditions like pseudotumor cerebri, hydrocephalus, or the presence of a ventriculoperitoneal shunt), pregnant patients, patients with any severe diseases, which can be a contraindication to magnetic resonance imaging (MRI), and cases with a medical history of ocular disease (such as glaucoma, cataract etc.) were excluded.

Surgical procedure

The time elapsed between the onset of the infarction and the decompressive surgery was determined. Any cases in which the patient was operated on within the first 48 hours were included. All included decompressive procedures were completed with a unilateral, wide fronto-temporoparietal hemi-craniectomy involving partial occipital bone and an enlarging duraplasty.

Ocular evaluations

The ONSD measurement was performed by radiology specialists who were well-trained and certified by the Health Ministry of Turkey. A 7.5-MHz linear probe was used by applying a thin layer of gel to both eyes of the patient while they were lying in the supine position. The ONSD measurement was performed with a US machine (Sonosite 180 Plus, Fujifilm, Minato, Tokyo, Japan) with a linear transducer 3 mm posteriorly to the globe at the sagittal and transverse views. The average ONSD was determined through a calculation of the mean value of the transverse and sagittal measurements of the right and left ONSDs.

Statistical analysis

The values pertaining to the descriptive analysis of the variables were expressed as means and standard deviations (SDs) in normal distribution, and the parameters with abnormal distribution were expressed as the median of the 25th and 75th percentiles. For the continuous variables, the differences between preoperative and postoperative measurements were evaluated using the paired sample *t*-test when the data were normally distributed and the Wilcoxon signed-rank test when the assumption of normality was not met. Values of *p* lower than 0.05 were considered statistically significant. The statistical analyses were performed using the Statistical Package for the Social Sciences (IBM SPSS Statistics for Windows, IBM Corp., Armonk, NY, United States) software, version 20.0.

RESULTS

The mean age of the sample was 53.6 ± 9.0 years, and there were 13 male patients and 4 female patients. In total, 3 patients (MRS score of 6) had died after craniectomy within the first 24 hours after surgery; 5 patients were found to be capable of carrying out their daily activities (MRS scores ranging from 0–3). The preoperative and postoperative NIHSS, GCS, and MRS scores, as well as the values pertaining to the midline shifts and ONSD, are presented in **Table 1**.

Nine of the patients had left MCA IS, and eight had right MCA IS. No significant differences were found regarding the mean ONSDs of left MCA IS (5.6 ± 0.3 mm) and right MCA IS (5.4 ± 0.5 mm) ($p = 0.01$).

A significant difference was observed regarding the preoperative mean ONSD (5.5 ± 0.4 mm) and the postoperative value found on day 1 (5 ± 0.4 mm) ($p < 0.001$) (**Table 2**, **Figure 1**). The changes in ONSD, midline shift, and *p*-values, as well as the changes in the scores on the NIHSS, GCS, and MRS are presented in **Table 2**.

DISCUSSION

In the present study, preoperative and postoperative monitoring of the ICP, and, indirectly, of the cerebral perfusion, was effectively achieved by ONSD measurements through ocular US in patients with malignant MCA infarction. In total, 10% to 15% of supratentorial ISs are comprised of massive unilateral hemispheric infarctions that cover the MCA territory and result in cerebral edema, herniation, and death.^{4,9} These kinds of malignant hemispheric infarctions usually originate from another artery or from cardiac embolism. For a group of patients with different MCA infarctions, mortality rates have been reported to be between 30%–66%, and they may rise up to 80% in patients with malignant MCA infarctions.^{10,11} Therefore, the treatment for malignant MCA infarction should be rapid and aggressive.¹²

The retrobulbar part of the optic nerve is tightly contained within the subarachnoid space; thus, it may be affected by an increase in CSF pressure. Ocular US is a widely used tool to evaluate the ONSD. Hansen and Helmke¹³ reported that the ONSD measurement in children with hydrocephalus is

Table 1 Preoperative and postoperative NIHSS, GCS and MRS scores, and midline shift and ONSD values

Patient #	Age	Sex	Preop. NIHSS	NIHSS 1 st day	Preop. GCS	GCS 1 st day	Preop. MRS	MRS 3 rd month	Preop. midline shift (cm)	1 st day midline shift (cm)	Preop. ONSD (mm)	1 st day ONSD (mm)
1.	43	Male	21	19	8	9	5	5	2.1	0.6	5.9	5.4
2.	54	Male	17	12	9	14	5	3	2	0.8	5.8	5.3
3.	57	Male	24	20	7	10	5	4	1.6	0	5.4	4.7
4.	62	Male	29	Exitus	6	Exitus	5	6	2.9	0	5.9	0
5.	55	Male	23	9	8	14	5	3	1.1	0.3	5.8	5.4
6.	40	Male	24	19	7	10	5	4	1.7	0	5.2	5
7.	63	Male	28	Exitus	5	Exitus	5	6	1.6	0	5.8	0
8.	43	Male	26	20	7	9	5	4	0.5	0	5.5	5.2
9.	51	Male	18	16	12	13	4	4	0	0	5.3	4.8
10.	49	Male	19	11	8	14	4	2	0	0.2	5.1	4.6
11.	70	Female	22	18	8	12	5	4	0.9	0	5.6	4.9
12.	63	Female	30	Exitus	4	Exitus	5	6	3.2	0	5.5	0
13.	64	Female	21	14	10	14	5	2	1.6	0.9	5.6	5.1
14.	42	Male	24	11	8	14	5	2	2	0.6	5.7	5.2
15.	56	Male	20	17	9	12	5	2	1.7	0.5	5.6	5.1
16.	45	Female	22	16	8	12	5	4	1.1	0	5.1	4.6
17.	54	Male	18	12	10	11	4	2	2.3	1.1	5.3	4.8

Abbreviations: GCS, Glasgow Coma Scale; MRS, Modified Rankin Scale; NIHSS, National Institutes of Health Stroke Scale; ONSD, optic nerve sheath diameter.

Table 2 Changes in ONSD and midline shift values and NIHSS, GCS and MRS scores

	Preoperative	Postoperative	p-value
ONSD (mm)	5.5 ± 0.4	5.0 ± 0.4	< 0.001*
NIHSS	21.36 ± 2.70	15.30 ± 0.75	< 0.001*
Midline shift	1.33 ± 0.75	0.36 ± 0.40	< 0.001*
GCS	8 (7.7–9.2)	12 (10–14)	0.001*
MRS	5 (4.7–5.0)	3.5 (2–4)	0.007*

Abbreviations: GCS, Glasgow Coma Scale; MRS, Modified Rankin Scale; NIHSS, National Institutes of Health Stroke Scale; ONSD, optic nerve sheath diameter.

Note: *Significant differences in changes in ONSD. Results expressed as the means ± standard deviations or interquartile ranges.

correlated with the ICP. Another study in patients with traumatic brain injury indicated that the ONSD, which was measured by ocular US, shortens as the ICP decreases.¹⁴ Geeraerts et al.⁶ noted that the ONSD measurement by ocular US, a non-invasive method, was an effective and reliable method to monitor the ICP of patients who were in the intensive care unit with a diagnosis of traumatic brain injury. A study from Pakistan¹⁵ also reported that ONSD values were significantly decreased in patients who had undergone decompressive surgery following a traumatic brain injury, which is in line with the results of other studies in the literature.

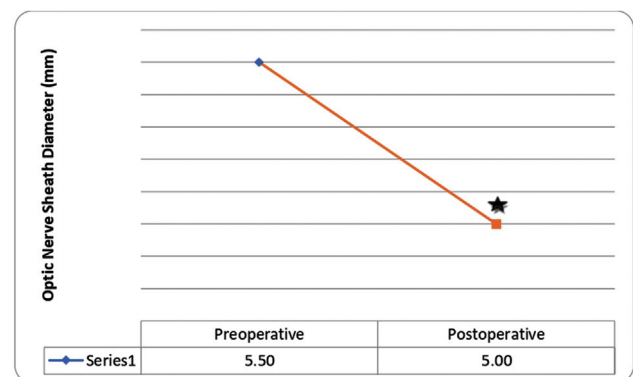


Figure 1 Preoperative and postoperative measurements of the optic nerve sheath diameter. Values are expressed as means and standard deviations. Significantly different when compared with preoperative (baseline) value ($p < 0.05$).

In the literature, there are many papers on the correlation between the ICP and ONSD, but few have explored the correlation between the ICP and ONSD after a case of stroke.

A study from the United Kingdom¹⁶ that addressed the clinical and radiological outcomes of decompressive surgery in patients with malignant MCA infarction revealed that the ONSD values had decreased following the surgical procedure.

In another study,¹⁷ the decrease in ONSD values was observed to be more significant in patients who had undergone the decompressive procedure after malignant MCA infarction compared with patients submitted to

decompressive craniectomy following non-malignant MCA infarctions. The authors of the article¹⁷ have also stated that the decrease in ONSD values was associated with the volume of the infarction and disability.

In the present study, we observed a significant reduction in ONSD values, which is corroborated by the clinical outcomes achieved after the decompressive surgery.

In studies comparing optic nerve US and invasive catheter methods, the mean ONSD of patients with an ICP > 20 mmHg was measured as 5.68 mm,¹⁸ 5.7 mm,¹⁹ and 7.6 mm,²⁰ and were found to be correlated with invasive ICP.

Notably, the present study has some limitations. The vital parameters of the patients were not recorded, and their effect on the ICP was not investigated. In addition, subgroups of the medical antiedema therapy (the name of anti-edema medication, ventilation rate, elevation status of the head) and the clear effect of the treatment were not investigated.

The present retrospective study, which provides reflections on the outcomes of a method that we use in our clinical practice to evaluate the ICP with a previously well-known non-invasive method, is limited in its ability to show a clear correlation between imaging techniques and ONSD measurements. Performing daily imaging scans to assess the patients' intracranial edema or midline shift is not considered as practical a method as clinical observation and bedside ONSD measurements. Of course, in cases of significant deterioration of the GCS and in planned routines, CT scans were performed. In those cases, CT supported our perspective on this point. In a future prospective study with a larger sample, we will develop a design to show this correlation in detail. With this preliminary exciting retrospective analysis, we are laying a foundation to demonstrate an easier and non-invasive bedside method in the clinical follow-up of cases of malignant MCA infarction.

In conclusion, the ocular measurement of the ONSD by US to preoperatively and postoperatively monitor the ICP appears to be a practical, non-invasive, and useful method.

Authors' Contributions

BED, OS, YD: contributed substantially to the conception or design of the study; ED, ZC, SEC: contributed to the collection, analysis, or interpretation of data; OS, YD: contributed to the writing or critical review of the manuscript; BED, ZC: contributed to the approval of the final version to be published.

Conflict of Interest

The authors have no conflict of interests to declare.

References

- Berkhemer OA, Fransen PS, Beumer D, et al; MR CLEAN Investigators. A randomized trial of intraarterial treatment for acute ischemic stroke. *N Engl J Med* 2015;372(01):11–20
- Jovin TG, Chamorro A, Cobo E, et al; REVASCAT Trial Investigators. Thrombectomy within 8 hours after symptom onset in ischemic stroke. *N Engl J Med* 2015;372(24):2296–2306
- Hacke W, Schwab S, Horn M, Spranger M, De Georgia M, von Kummer R. 'Malignant' middle cerebral artery territory infarction: clinical course and prognostic signs. *Arch Neurol* 1996;53(04):309–315
- Frank JJN. Large hemispheric infarction, deterioration, and intracranial pressure. *Neurology* 1995;45(07):1286–1290
- Kimberly HH, Shah S, Marill K, Noble V. Correlation of optic nerve sheath diameter with direct measurement of intracranial pressure. *Acad Emerg Med* 2008;15(02):201–204
- Geeraerts T, Merceron S, Benhamou D, Vigué B, Duranteau JJCC. Noninvasive assessment of intracranial pressure using ocular sonography in neurocritical care patients. *Intensive Care Med* 2008;12(S2):117
- Dubourg J, Javouhey E, Geeraerts T, Messerer M, Kassai B. Ultrasonography of optic nerve sheath diameter for detection of raised intracranial pressure: a systematic review and meta-analysis. *Intensive Care Med* 2011;37(07):1059–1068
- Dip F, Nguyen D, Rosales A, et al. Impact of controlled intra-abdominal pressure on the optic nerve sheath diameter during laparoscopic procedures. *Surg Endosc* 2016;30(01):44–49
- Vahedi K, Vicaut E, Mateo J, et al; DECIMAL Investigators. Sequential-design, multicenter, randomized, controlled trial of early decompressive craniectomy in malignant middle cerebral artery infarction (DECIMAL Trial). *Stroke* 2007;38(09):2506–2517
- Guerra WK-W, Gaab MR, Dietz H, Mueller J-U, Piek J, Fritsch MJ. Surgical decompression for traumatic brain swelling: indications and results. *J Neurosurg* 1999;90(02):187–196
- Silver FL, Norris JW, Lewis AJ, Hachinski VC. Early mortality following stroke: a prospective review. *Stroke* 1984;15(03):492–496
- Hacke W, Schwab S, Horn M, Spranger M, De Georgia M, von Kummer R. 'Malignant' middle cerebral artery territory infarction: clinical course and prognostic signs. *Arch Neurol* 1996;53(04):309–315
- Hansen H-C, Helmke K. Validation of the optic nerve sheath response to changing cerebrospinal fluid pressure: ultrasound findings during intrathecal infusion tests. *J Neurosurg* 1997;87(01):34–40
- Tayal VS, Neulander M, Norton HJ, Foster T, Saunders T, Blaiwas M. Emergency department sonographic measurement of optic nerve sheath diameter to detect findings of increased intracranial pressure in adult head injury patients. *Ann Emerg Med* 2007;49(04):508–514
- Waqas M, Bakhshi SK, Shamim MS, Anwar S. Radiological prognostication in patients with head trauma requiring decompressive craniectomy: Analysis of optic nerve sheath diameter and Rotterdam CT Scoring System. *J Neuroradiol* 2016;43(01):25–30
- Albert AF, Kirkman MA. Clinical and radiological predictors of malignant middle cerebral artery infarction development and outcomes. *J Stroke Cerebrovasc Dis* 2017;26(11):2671–2679
- Berrouschot J, Sterker M, Bettin S, Köster J, Schneider D. Mortality of space-occupying ('malignant') middle cerebral artery infarction under conservative intensive care. *Intensive Care Med* 1998;24(06):620–623
- Geeraerts T, Merceron S, Benhamou D, Vigué B, Duranteau J. Non-invasive assessment of intracranial pressure using ocular sonography in neurocritical care patients. *Intensive Care Med* 2008;34(11):2062–2067
- Kimberly HH, Shah S, Marill K, Noble V. Correlation of optic nerve sheath diameter with direct measurement of intracranial pressure. *Acad Emerg Med* 2008;15(02):201–204
- Širanovic M, Turkovic TM, Gopevic A, et al. Comparison of ultrasonographic measurement of optic nerve sheath diameter (ONSD) versus direct measurement of intracranial pressure (ICP) in traumatic brain injury patients. *Signa Vitae* 2011;6(01):33–35