



Case report

An interesting septic embolism



Funda Uluorman ^{a,*}, Zülkif Tanrıverdi ^{b,1}, Can Sevinç ^{c,2}, Özer Badak ^{d,2},
Hüdai Çatalyürek ^{e,2}

^a Department of Pulmonology, Izmir Atatürk Education and Research Hospital, Izmir, Turkey

^b Department of Cardiology, Sırnak İdil Hospital, Sırnak, Turkey

^c Department of Pulmonology, Dokuz Eylül University, Izmir Turkey

^d Department of Cardiology, Dokuz Eylül University, Izmir, Turkey

^e Department of Cardiovascular Surgery, Dokuz Eylül University, Izmir Turkey

A B S T R A C T

Keywords:
Septic emboli
Pacemaker
Vegetation

Septic pulmonary embolism is a rare disease but mortality and morbidity of it is high. Septic pulmonary emboli comes from infected heart valves, thrombophlebitis, and pulmonary artery catheter or infected pacemaker wires as many sources [1,2]. In recent years, pacemaker is a common treatment of the bradycardia that is persisted in the etiology of septic embolism, its applications has started to pick up [3]. There is the growing number of patients with pacemaker, according to this the frequency of pacemaker lead infection and the number of patients at risk for right-sided endocarditis increase [4]. The patients don't have specific clinical and radiological features because of this it is very difficult to define, so the diagnosis is often delayed [5]. A detailed medical history, a detailed physical examination in diagnosis and evaluation of good additional imaging methods is very important. Early diagnosis and proper treatment, the implementation of the management, can provide good results.

© 2014 The Authors. Published by Elsevier Ltd. This is an open access article under the CC BY-NC-ND license (<http://creativecommons.org/licenses/by-nc-nd/3.0/>).

Case presentation

A 40-year-old man presented with chest pain to emergency room. Poor general condition of the patient and he was confused. His vital findings, arterial blood pressure is 100/60 mmHg, cardiac pulse is 68/min respiratory rate is 20/min, fever is 38.5 °C. Auscultation of the heart, there is 3/6 systolic souffle in all of the cardiac zones. He has had pacemaker one year ago because of syncope. In patient's current medical history, there was a tooth extraction before starting complaints.

In cases of emergency bedside echocardiography; left ventricular systolic function is normal but there is a pacemaker lead in the right atrium and related to this lead there is echogenicity (Fig. 1). Transesophageal echocardiograph is showed that moving multi-lobulated vegetation, attached to the lead 30 × 12 mm in size in the right atrium. CRP, ESR and WBC elevation in patients, he had

diagnosis of infective endocarditis associated with pacemaker lead and empirical antibiotic therapy was started.

Because of he has serious chest pain, thorax CT angiography is taken. Right pulmonary lower lobe anterior segment pulmonary artery has vascular filling defect as related to pulmonary embolism (Fig. 2).

Because of he has diagnosis of infective endocarditis associated with pacemaker lead, it is evaluated in cardiology and cardiovascular surgical council.

It is judged again indication of pacemaker, concluded that remove of this is more suitable.

He is operated by cardiovascular surgery, infectious material and the lead was removed, cultures were sent. Culture of patient coagulase-negative staphylococci (CNS) was growth. The treatment was continued according to antibiogram.

After the operation, pacemaker battery is removed by cardiology.

After effective dose and time of antibiotics infection is controlled. After treatment the patient discharged to home without problem. The three-year follow-up of there is no problem about patient.

Discussion

Cardiac pacemaker and implantable cardioverter defibrillator (ICD) are created a revolution in the treatment of patients that have

* Corresponding author. Tel.: +90 232 244 44 44, +90 232 244 2906, 90 5059504317 fax: +90 2322431530.

E-mail addresses: fuluorman@hotmail.com, arslan_funda@mynet.com (F. Uluorman), ztverdi@gmail.com (Z. Tanrıverdi), csevinc@deu.edu.tr (C. Sevinç), ozer.badak@deu.edu.tr (Ö. Badak), hudai.catalyurek@deu.edu.tr (H. Çatalyürek).

¹ Tel.: +90 4865513636.

² Tel.: +90 232412 22 22.

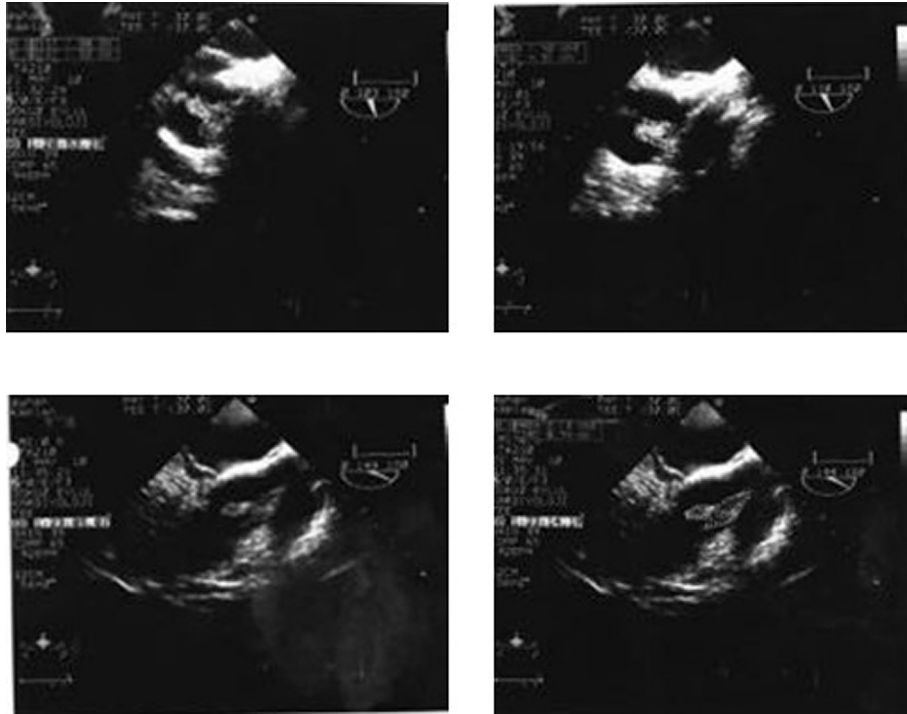


Fig. 1. Multilobulated ekojenite, attached to the lead 30 × 12 mm in size in the right atrium.

heart rhythm problem in parallel, clinical indications for use of the device for each of the two groups gradually expanded [6].

However, like all foreign bodies, cardiac pacemaker and implantable cardioverter defibrillator (ICD) also carry a risk of infection. Due to the increase in the number of that device, implanted pacemaker and ICD infections have become more common problems in clinical practice [7]. The incidence of cardiac pacemaker may vary greatly between such as studies. Recent study based on population, showed that the incidence of definite device infection was 1.9 per 1000 device-years and the cumulative probability of device infection was higher among patients with

defibrillators compared with those with pacemakers [8]. There is a high mortality associated with infections of the devices (% 27–65) is reported [9].

Approximately 25% of acute cardiac pacemaker infections occur an acute event (in a period of; device to be installed in the first 1–2 months), but up to 8–12 months of delays in diagnosis may occur [10]. In our case, was diagnosed septic embolism with the pacemaker one year after the application.

As with other forms of infective endocarditis, echocardiography and blood cultures are based on the diagnosis in infective endocarditis that is related to cardiac device.

Especially echocardiography, plays a key role in infective endocarditis that is related to cardiac device both vegetation of the electrode diagnosis and to follow up after the removal of electrodes.

Septic emboli is frequently occurring the complication of cardiac device infection and its the most important diagnostic tool in detecting thorax CT. Our patient's thorax CT angiography was revealed filling defects that mimics the pulmonary thromboembolism that was thought to be associated with the septic embolism. What's interesting is that there is no radiological findings that we're used to see in the septic embolism in our patient.

Radiological findings of multiple, small diffuse lung opacities, look alike of bronchopneumonia, wedge-shaped in the periphery of lung, form of a two-sided nodules, cavitations in the nodules may present [11]. However, there was no abnormal radiological finding in our case showed, parenchymal was unremarkable (Fig. 3).

Based on here; detailed patients medical stories, systematic physical examinations and echocardiography was very convenient and useful approaches in cases of pulmonary thromboembolism. It is difficult to diagnose without clinical suspicion. This delays appropriate treatment; thus careful medical history and physical examination by the physician are very important. Also, thorough echocardiographic evaluation of all cardiac valves, including right-sided valves, should be carried out in all patients with suspecting infective endocarditis, especially when the patient has a risk factor

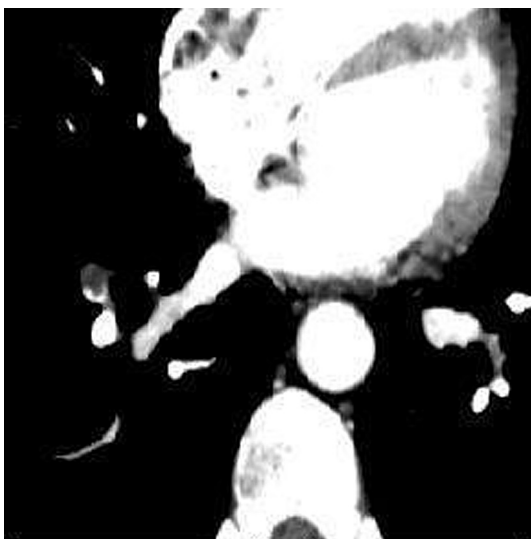


Fig. 2. Right pulmonary lower lob anterior segment pulmonary artery has vascular filling defect.

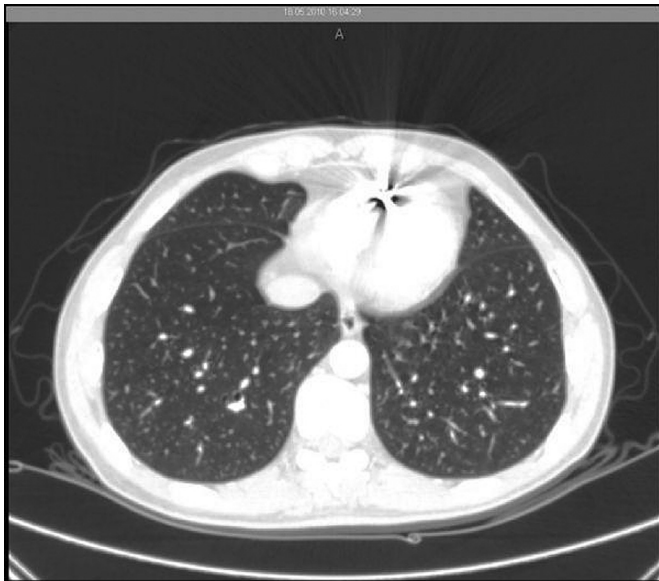

Fig. 3. There is no abnormal radiological finding in parenchymal.

[12]. If insufficient history is taken and has no echocardiography we think diagnosis of pulmonary embolism according to chest pain, fever and torax BT angiography findings and then we can give the patient anticoagulant therapy against antibiotics. Especially in recent years, increased heart battery applications commensurate increase in cases of infective endocarditis. This is when evaluating patients with this aspect should be on the look out. The most frequent infective endocarditis in previous years as a result of venous catheters, valve pathology, recently the pacemaker has begun to take place in etiology.

Because of this, indication of this kind of cardiac device applications must be well done, and be careful of any complications that may arise, after all of this decision will be appropriate. If these

devices have been proven infection, the treatment recommended by the guidelines, is the long-term antibiotic therapy and removal of the device. [13].

We want to emphasize once again that especially on the occasion of septic emboli diagnosis, clinical history, physical examination and echocardiographic imaging is important considerations and in the presence of infection, treatment is removal of the device in this case.

References

- [1] Celikel TH, Muthuswamy PP. Septic pulmonary emboli second ary to internal jugular vein phlebitis (postanginal sepsis) caused by *Eikenella corrodens*. *Am Rev Respir Dis* 1984;130:510–3.
- [2] Kuhlman JE, Fishman EK, Teigen C. Pulmonary septic emboli: diagnosis with CT. *Radwlogy* 1990;174:211–3.
- [3] Martínez-Sellés Manuel, Bueno Hector, Almendral Jesus, Díaz-Castro Oscar. Pulmonary embolism after pacemaker implantation. *Tex Heart Inst J* 2001;28(4):318–9.
- [4] Iezzi F, Cini R, Sordini P. Tricuspid-valve repair for pacemaker leads endocarditis. *BMJ Case Rep* 2010. <http://dx.doi.org/10.1136/bcr.01.2010.2673>.
- [5] Cook RJ, Ashton RW, Aughenbaugh GL, et al. Septic pulmonary embolism: presenting features and clinical course of 14 patients. *Chest* 2005;128:162–6.
- [6] Karchmer AW, Longworth DL. Infections of intracardiac devices. *Infect Dis Clin North Am* 2002;16:477–505.
- [7] Baddour LM, Bettmann MA, Bolger AF, Epstein AE, Ferrieri P, Gerber MA, et al. Nonvalvular cardiovascular device-related infections. *Circulation* 2003;108:2015–31.
- [8] Uslan DZ, Sohail MR, St Sauver JL, Friedman PA, Hayes DL, Stoner SM, et al. Permanent pacemaker and implantable cardioverter defibrillator infection: a population-based study. *Arch Intern Med* 2007;167:669–75.
- [9] Klug D, Lacroix D, Savoye C, et al. Systemic infection related to endocarditis on pacemaker leads: clinical presentation and management. *Circulation* 1997;95:2098–107.
- [10] Gandelman G, Frishman WH, Wiese C, et al. Intravascular device infections: epidemiology, diagnosis and management. *Cardiol Rev* 2007;15:13–23.
- [11] Jaffe RB, Koschmann EB. Septic pulmonary emboli. *Radiology* 1970;96(3):527–32.
- [12] Abdelbar A, Azzam R, Yap KH, Abousteit A. Isolated pulmonary infective endocarditis with septic pulmonary embolism complicating a right ventricular outflow tract obstruction: scarce and devious presentation. *Case Rep Surg* 2013;2013:746589. <http://dx.doi.org/10.1155/2013/746589> [Epub 2013 Sep.].
- [13] Chua JD, Wilkoff BL, Lee I, Juratli N, Longworth DL, Gordon SM. Diagnosis and management of infections involving implantable electrophysiologic cardiac devices. *Ann Intern Med* 2000;133:604–8.