



Internal urethral sphincter reconstruction with anterior bladder neck tube for robotic and laparoscopic radical prostatectomy: improving early return of continence

Zhibin Xu, Jie Zhao, Zhenghui Guan, Maomao Guo, Hao Bian, Zhenchi Li, Wenchao Zhao, Sudong Liang, Yu Liu, Siyang Zhang, Jiangping Wang

Department of Urology, The Affiliated Taizhou People's Hospital of Nanjing Medical University, Taizhou School of Clinical Medicine, Nanjing Medical University, Taizhou, China

Contributions: (I) Conception and design: J Wang, Z Xu; (II) Administrative support: J Wang; (III) Provision of study materials or patients: J Wang, Z Xu; (IV) Collection and assembly of data: M Guo, H Bian, J Zhao, Z Guan, Y Liu, S Zhang; (V) Data analysis and interpretation: J Zhao, Z Guan, Z Li, W Zhao, S Liang; (VI) Manuscript writing: All authors; (VII) Final approval of manuscript: All authors.

Correspondence to: Jiangping Wang, MD. Department of Urology, The Affiliated Taizhou People's Hospital of Nanjing Medical University, Taizhou School of Clinical Medicine, Nanjing Medical University, 366 Taihu Road, Taizhou 225300, China. Email: mingzhujp@126.com.

Background: In recent years, despite several surgical techniques having been applied, the early incontinence rate after radical prostatectomy (RP) remains high. In this study, we reconstructed an internal urethral sphincter (IUS) with anterior bladder neck tube (ABNT) to improve early return of continence and find a more effective technique for early urinary incontinence after RP.

Methods: In this study, 96 previous patients who did not receive an ABNT between October 2018 and May 2020 were compared as historical controls (the control group). A total of 210 consecutive patients underwent robotic or laparoscopic RP with ABNT between May 2020 and February 2023 (the ABNT group). The inclusion criteria included Eastern Cooperative Oncology Group (ECOG) score 0-1 and localized prostate cancer (clinical stages cT1-3, cN0, cM0). The exclusion criteria included patients with diabetes, neurologic diseases, previous pelvic operations, symptoms of urinary incontinence, prior radiation, focal therapy, or androgen deprivation therapy for prostate cancer. ABNT was reconstructed with a U-shaped flap from the anterior wall of the bladder neck, and was then anastomosed with the urethra. In the control group, the bladder outlet was directly anastomosed with the urethra. Continence, as defined if 0 pads were used per day and International Consultation on Incontinence Questionnaire-Short Form (ICIQ-SF) score ≤ 6 , was assessed at 1, 4, 8, 12, and 24 weeks after catheter removal. At 2 weeks after catheter removal, urethral pressure profilometry (UPP) and upright urethrography were performed to evaluate the function of ABNT in the ABNT group.

Results: More patients in the ABNT group were continent than those in the control group at 1 week (85.2% vs. 22.9%, $P < 0.001$), 4 weeks (91.4% vs. 27.1%, $P < 0.001$), 8 weeks (95.2% vs. 40.6%, $P < 0.001$), 12 weeks (100% vs. 71.9%, $P < 0.001$), and at 24 weeks (100% vs. 87.5%, $P < 0.001$) after catheter removal. Stricture was presented in 5.2% and 2.1% ($P = 0.34$) in the ABNT group and control group, respectively. UPP showed that a functional IUS was reconstructed with ABNT. Upright urethrography showed that the ABNT was filled with contrast medium in the urination period and with no contrast medium during the storage period and interruption of urination.

Conclusions: The ABNT technique significantly improved early return of continence in comparison with the no ABNT technique, especially the immediate continence. The ABNT technique reconstructed the functional IUS with acceptable urethral stricture. The limitations of the present study include that the comparison was conducted retrospectively with a historical cohort and lack of randomization, and the single center setting. A prospective, randomized, and multicenter evaluation is expected.

Keywords: Prostate cancer; radical prostatectomy (RP); urinary continence; anterior bladder neck tube (ABNT); internal urethral sphincter (IUS)

Submitted Nov 15, 2023. Accepted for publication Apr 03, 2024. Published online Jun 26, 2024.

doi: 10.21037/tau-23-583

View this article at: <https://dx.doi.org/10.21037/tau-23-583>

Introduction

Prostate cancer is commonly treated with radical prostatectomy (RP). The ideal RP is realized when the concurrent presence of urinary continence and sexual potency is achieved, with no evidence of positive surgical margins (PSM), and complications (1). The incontinence rate at 1 year after RP is about 5.4–18.6% (2), and the early incontinence rate is worse. In fact, the likelihood of a patient requiring pads after surgery is typically 70–80% at 6 weeks, 50–60% at 3 months, and 20–40% at 6 months. Questionnaires of health-related quality of life and continence administered to patients who underwent RP have shown that urinary incontinence affects the physical, psychological, and social well-being of patients and, thus, has a considerable impact on quality of life (3–6). As a result, a variety of surgical techniques have been described in the attempt to improve the recovery of urinary continence after RP, including posterior or anterior reconstruction, Retzius space preservation, prostatic fascia preservation, and functional urethral length (FUL) preservation, among others. Although these technologies have improved continence to a certain extent, persistent challenges are still faced.

Urodynamic studies have confirmed that postoperative incontinence seems to depend upon the reduction in FUL, caused by the loss of internal urethral sphincter (IUS) (7,8). Some surgical techniques have been described to preserve or reconstruct FUL, such as sparing of the external urethral sphincter (EUS) (9), maximal urethral length (10), bladder neck preservation (BNP) (11), bladder neck plication stitch (12,13), and anterior bladder neck tube (ABNT) (14–16).

In the 1990s, ABNT was conducted by several surgeons in open RP (14–16). In this study, we performed robotic or laparoscopic RP with ABNT, aiming to reconstruct the functional IUS and improve early return of continence. We present this article in accordance with the STROBE reporting checklist (available at <https://tau.amegroups.com/article/view/10.21037/tau-23-583/rc>).

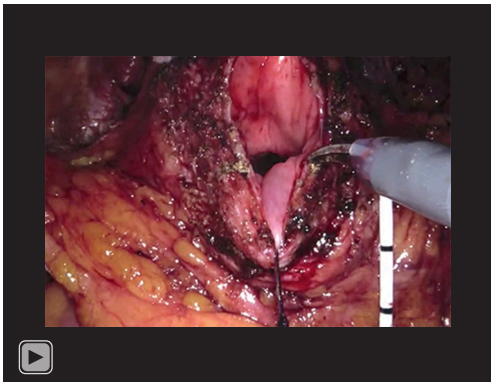
Methods

Study population and design

Between May 2020 and February 2023, 210 consecutive patients (the ABNT group) underwent pure laparoscopic (n=83) or robotically-assisted (n=127) RP with ABNT. As a historical control group with suitable follow-up information, 96 consecutive preceding patients were identified who had undergone laparoscopic (n=56) or robotically-assisted (n=40) RP with no ABNT between October 2018 and May 2020. Patients choose robot or laparoscopes laparoscopy based on the cost. The inclusion criteria included Eastern Cooperative Oncology Group (ECOG) score 0–1 and localized prostate cancer (clinical stages cT1–3, cN0, cM0). Preoperative assessment included multiparametric magnetic resonance imaging (MRI) of the prostate in all cases. The exclusion criteria were contraindications for undergoing RP. Patients with diabetes, neurologic diseases, previous pelvic operations, symptoms of urinary incontinence, prior radiation, focal therapy, or androgen deprivation therapy for prostate cancer were excluded. The present study was performed at our hospital after obtaining approval from the Institutional Ethics Committee. All patients underwent the assigned treatment by a single surgeon (J.W.) with experience in RP of >100 cases at the start of the study. The study was conducted in accordance with the Declaration of Helsinki (as revised in 2013). The study was approved by the ethics board of The Affiliated Taizhou People's Hospital of Nanjing Medical University (No. KY2021-032-02) and informed consent was obtained from all individual participants.

Surgical technique

The standard extrafascial technique, according to Hurtes and Patel (4,17), was performed in most patients, and nerve sparing was performed in selected patients. The bladder outlet was directly anastomosed with urethra in the control



Video 1 ABNT technique. ABNT, anterior bladder neck tube.

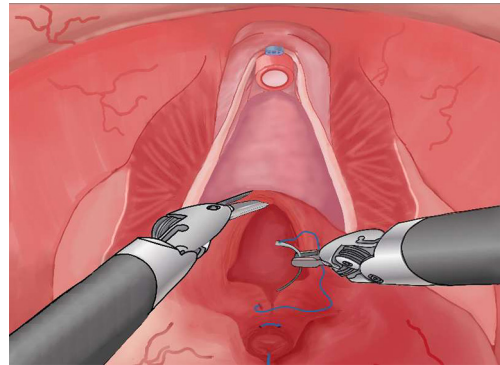


Figure 3 Both sides of the U-shaped flap are sutured to form an ABNT. ABNT, anterior bladder neck tube.

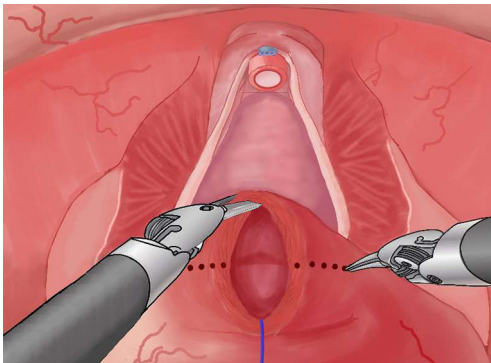


Figure 1 Two marker lines on the anterior wall of the bladder neck.

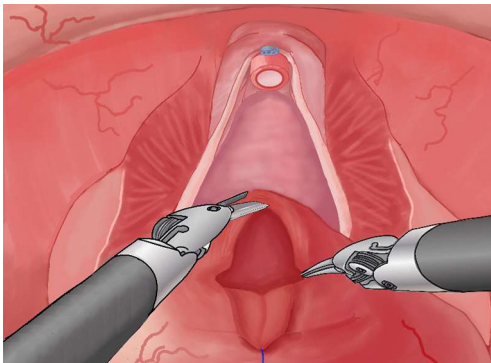


Figure 2 The U-shaped flap formed after incising along the marker lines.

group, and ABNT was reconstructed before anastomosis in the ABNT group. Bilateral standard pelvic lymph node dissection was performed in patients with intermediate and high risk, based on the D'Amico classification.

Details of the ABNT technique are shown in the accompanying *Video 1*. The steps can be summarized as follows: (I) A 2-0 line, passed through the bladder neck at 6 o'clock, is used for pulling. Electrocoagulation is used to mark 2 points, which are at about 4 o'clock and 8 o'clock of the bladder neck, and 10 mm away from 6 o'clock. Then, 2 15 mm lines are marked along anterior wall of bladder neck, from the 2 marker points and perpendicular to the muscle fiber of bladder neck (*Figure 1*). (II) The anterior wall of bladder neck is incised along the 2 marker lines to form a U-shaped flap. The width of the U-shaped flap is 20 mm and the length is 15 mm (*Figure 2*). When the bladder wall is thick, the width can be appropriately increased to avoid ABNT having a too narrow diameter. When the bladder wall is thin, the width can be appropriately reduced to avoid ABNT having a thicker diameter. (III) Both edges of the U-shaped flap are 3/0 "barbed" running sutured longitudinally from 2 marker points to form an ABNT. During suturing, pay attention to the precise alignment of the various layers of bladder wall to avoid ABNT stenosis (*Figure 3*). (IV) Then, the bladder orifice is sutured longitudinally (*Figure 4*). (V) ABNT and urethra anastomosis is performed by a 3/0 "barbed" running suture, starting at 4 o'clock on the urethra and then proceeding clockwise (*Figure 5*). After completing the posterior anastomosis of the urethra, insert the urinary catheter and pass through the anastomosis with the help of pulling at the 6 o'clock point.

Data collection

Collected data included preoperative variables, age, body mass index (BMI), prostate volume, prostate-specific

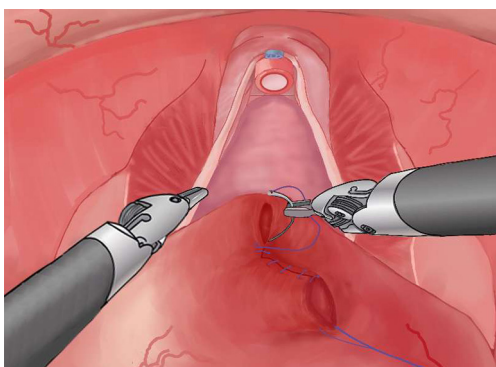


Figure 4 Continue to suture the bladder orifice longitudinally after the formation of ABNT. ABNT, anterior bladder neck tube.

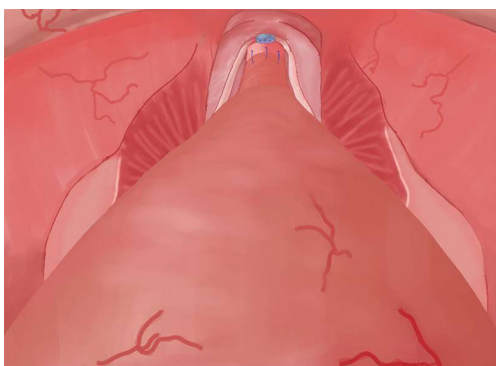


Figure 5 ABNT is anastomosed with urethra. ABNT, anterior bladder neck tube.

antigen (PSA), clinical T stage, Gleason score at biopsy, and D'Amico risk stratification (*Table 1*); intraoperative variables, including console surgery time, ABNT time, estimated blood loss, and nerve sparing (*Table 2*); and postoperative variables, including continence outcomes, complications, and pathological stage (*Table 2*).

The continence rate was assessed at 1, 4, 8, 12, and 24 weeks after catheter removal by a urological fellow (J.Z.). The question “How many pads or adult diapers per day did you usually use to control leakage during the last 1 or 4 weeks?” and the International Consultation on Incontinence Questionnaire-Short Form (ICIQ-SF) questionnaire were administered either at the follow-up office visit or via telephone interviews. Patients were considered continent if 0 pad was used per day and ICIQ-SF score ≤ 6 (18). Continence data were verified independently by two coauthors (Z.G. and H.B.). Immediate urinary continence would be defined as continence within 1 week of catheter

removal (19). The retrospective continence date of the control group were collected from the follow-up manuals, and the missing data were supplemented by telephone interview.

At 2 weeks after catheter removal, urethral pressure profilometry (UPP) and upright urethrography were performed to evaluate the function of ABNT.

Statistical analysis

The baseline demographics, tumor characteristics, and operative and postoperative outcomes were collected in a computerized database. Continuous variables were reported as means and standard deviation (SD), median and interquartile range (IQR). Categorical variables were reported as percentages. Because this was a nonrandomized comparative study, differences among patient characteristics of the two groups were compared by univariate tests. For categorical variables, the comparison was performed by the χ^2 test. For continuous variables, we used *t*-test, as the data were normally distributed, and nonparametric test, as the data were not normally distributed. Data analysis was performed using the software SPSS 25.0 (IBM Corp., Armonk, NY, USA) and statistical significance was defined as $P < 0.05$.

Results

Both groups had similar baseline demographics and characteristic data on univariate analysis (age, BMI, prostate volume, PSA, clinical T stage, biopsy Gleason score, and D'Amico class) (*Table 1*). Estimated blood loss, nerve sparing, final pathological stage, lymph node dissections, and surgical margins did not significantly differ between the groups (*Table 2*). The endoscopic operative time was significantly longer in the ABNT group, at 97.7 (79.5–111.2) minutes versus 83.4 (65.8–90.2) minutes ($P = 0.004$) (*Table 2*). *Table 3* summarizes a comprehensive list of complications. The 2 groups had no significant differences in urethral stricture (5.2% vs. 2.1%, $P = 0.34$) (*Table 3*).

Catheter removal was performed on postoperative 10–14 days. More patients achieved continence return in the ABNT group. At 1 week after catheter removal, 85.2% of the patients in the ABNT group were continent versus 22.9% of the patients in the control group ($P < 0.001$). At 4 weeks, these percentages were 91.4% and 27.1% ($P < 0.001$), 8 weeks 95.2% and 40.6% ($P < 0.001$), 12 weeks 100% and 71.9% ($P < 0.001$), and 24 weeks 100% and

Table 1 Preoperative characteristics of the study population

Variables	ABNT group, (n=210)	Control group, (n=96)	P value
Age (years), median (IQR)	73.0 (69.0, 77.8)	74.2 (68.6, 76.7)	0.92
BMI (kg/m ²), median (IQR)	24.1 (22.6, 26.5)	24.5 (21.9, 26.1)	0.87
Prostate volume (mL), median (IQR)	38.7 (29.6, 50.9)	36.7 (31.3, 52.6)	0.74
PSA (ng/mL), median (IQR)	11.0 (7.6, 22.5)	13.3 (7.9, 25.2)	0.78
Clinical T stage, n (%)			0.86
T1	35 (16.7)	14 (14.6)	
T2	136 (64.8)	65 (67.7)	
T3	39 (18.6)	17 (17.7)	
Biopsy Gleason score, n (%)			0.27
3+3	31 (14.8)	14 (14.6)	
3+4	52 (24.8)	28 (29.2)	
4+3	54 (25.7)	30 (28.8)	
4+4	49 (23.3)	20 (20.8)	
>4+4	24 (11.4)	4 (4.2)	
D'Amico class, n (%)			0.82
Low	43 (20.5)	17 (17.7)	
Intermediate	94 (44.8)	46 (47.9)	
High	73 (34.8)	33 (34.4)	

ABNT, anterior bladder neck tube; IQR, interquartile range; BMI, body mass index; PSA, prostate-specific antigen.

Table 2 Intraoperative outcomes and surgical pathology

Variables	ABNT group (n=210)	Control group (n=96)	P value
Endoscopic surgery time (min), median [IQR]	97.7 [79.5, 111.2]	83.4 [65.8, 90.2]	0.004
Estimated blood loss (mL), median [IQR]	50 [20, 100]	48 [20, 95]	0.88
Nerve sparing, n (%)			0.91
Bilateral	7 (3.3)	2 (2.1)	
Monolateral	5 (2.4)	2 (2.1)	
Non	198 (94.3)	92 (95.9)	
Final pathological stage, n (%)			0.87
pT2	116 (55.2)	50 (52.1)	
pT3	90 (42.9)	44 (45.8)	
pT4	4 (1.9)	2 (2.1)	
Lymph node dissections, n (%)			0.97
Non	43 (20.5)	20 (20.8)	
N0	149 (71.0)	67 (69.8)	
N1	18 (8.6)	9 (9.4)	
Surgical margins, n (%)			0.51
Negative	175 (83.3)	77 (80.2)	
Positive	35 (16.6)	19 (19.8)	

IQR, interquartile range; ABNT, anterior bladder neck tube.

Table 3 Surgical complications after RP

Complications	ABNT group	Control group	P value
Intraoperative bowel injury	0	0	
Intraoperative ureteric injury	0	0	
Pulmonary embolism	0	0	
Acute urinary retentions	0	0	
Anastomotic urine leakage	0	0	
Lymphocele requiring drainage	0	0	
Wound infection	0	0	
Urethral stricture	11 (5.2)	2 (2.1)	0.34
Incisional hernia	0	0	
Residual urine >50 mL	0	0	

Data are presented as n (%). RP, radical prostatectomy; ABNT, anterior bladder neck tube.

Table 4 Continence outcomes

Continence	ABNT group (n=210)	Control group (n=96)	P value
1 week	179 (85.2)	22 (22.9)	<0.001
4 weeks	192 (91.4)	26 (27.1)	<0.001
8 weeks	200 (95.2)	39 (40.6)	<0.001
12 weeks	210 (100.0)	69 (71.9)	<0.001
24 weeks	210 (100.0)	84 (87.5)	<0.001

Data are presented as n (%). ABNT, anterior bladder neck tube.

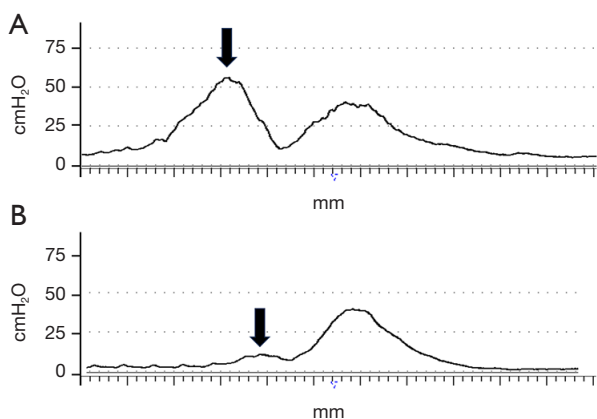


Figure 6 Postoperative UPP. (A) A towering ABNT peak (black arrow) was shown in the continence group. (B) A low-lying ABNT peak (black arrow) was shown in the incontinence group. UPP, urethral pressure profilometry; ABNT, anterior bladder neck tube.

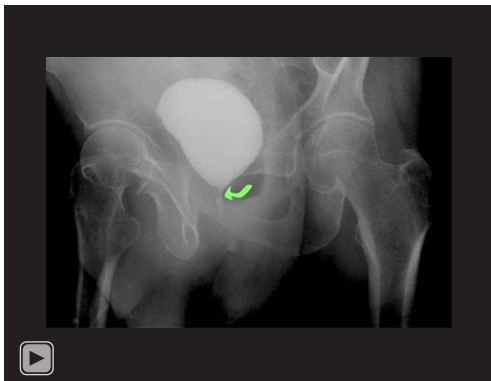
87.5% ($P < 0.001$), respectively. *Table 4* summarizes the continence rate.

At 2 weeks after catheter removal, 92 patients in the ABNT group underwent UPP, including 84 patients with continence and 8 patients with incontinence. UPP of all patients were bimodal. There was an ABNT peak proximal to EUS peak (*Figure 6*). A towering ABNT peak was always shown in the continence group (*Figure 6A*), and a low-lying ABNT peak was always shown in the incontinence group (*Figure 6B*). The FUL of ABNT were comparable with EUS ($P > 0.05$), when the sum FUL and UFA were significantly higher than that of EUS respectively ($P < 0.05$). *Table 5* summarizes the various UPP data. Upright urethrography of 15 patients with continence showed that a long tubularized neo-urethra proximal to anastomosis and the EUS was filled with contrast medium immediately at the beginning of the urination period, and filled with

Table 5 Data of UPP

Variables	UPP population (n=92)
FUL (mm)	28.2±6.6 ^a
FUL-ABNT	14.0 (11.0, 17.0) ^p
FUL-EUS	13.8±3.6
MUP (cmH ₂ O)	65.0 (41.8, 77.5) ^p
MUP-ABNT	29.5 (11.5, 72.3) ^a
MUP-EUS	56.5 (40.0, 65.0)
UFA (mm × cmH ₂ O)	752.0±357.4 ^a
UFA-ABNT	240.0 (126.8, 482.0) ^a
UFA-EUS	436.9±179.4

Data are presented as mean ± standard deviation or median (interquartile range). ^a, compared with EUS $P < 0.05$; ^b, compared with EUS $P > 0.05$. UPP, urethral pressure profilometry; FUL, functional urethral length; ABNT, anterior bladder neck tube; EUS, external urethral sphincter; MUP, maximum urethral pressure; UFA, urethral functional area.

**Video 2** Upright urethrography.

no contrast medium there during the storage period and interruption of urination (*Video 2*).

Discussion

Researchers have recognized the important role of FUL in urinary continence, and confirmed that preserving the bladder neck and apex urethra can preserve FUL and improve continence in the early post-RP period (9-11). However, the prostate protrusion at the apex urethra or neck of the bladder often squeezes the urethra or bladder neck, and results in the inability to preserve these tissues with sufficient thickness and length. Meanwhile, preservation of the apex urethra and bladder neck has a risk of PSM at both

ends of the prostate (20,21). FUL reconstruction is a way to avoid the above problems.

The ABNT was first reported to reconstruct FUL in 1953 (22). The most extensive series was conducted by Steiner, Seaman, and Connolly in open RP during the 1990s (14-16). Steiner reported 3- and 6-month continence rates of 55% and 87%, respectively (14). Seaman reported that 27 of 29 (93%) and 28 of 29 (97%) participants were fully continent by 3 months and 6 months follow-up, respectively (15). Although these studies confirmed that ABNT improved return of continence after 3 months, the early continence within 3 months was not recorded, the sample size of these studies was small, and the continence rates of different studies varied greatly.

Based on these works, we firstly and successfully performed ABNT in robotically assisted and pure laparoscopic RP. The continence rate at 1 week (immediate continence) after catheter removal was 85.2%, and gradually improved to 91.4% by 4 weeks, 95.2% by 8 weeks (95.2%), and 100% by 12 weeks. Notably, our early continence rates within 3 months after RP, especially the immediate urinary continence rate, were significantly higher than those in the control group, open RP with ABNT, and others to preserve or reconstruct FUL (9-15,23) (*Figure 7*). ABNT allowed for a much more rapid recovery of continence after RP, and significantly improved the physical, psychological, and social well-being of patients. Since bladder neck and urethra preservation were not required, ABNT avoided the additional PSM risk at both ends of the prostate, and can be applied in all organ-confined prostate cancer cases. Since the operation is simple, ABNT can be completed by surgeons who master the robotically assisted and laparoscopic technique.

ABNT function in the sense of an IUS has not been substantiated by research. In this study, we conducted postoperative UPP and upright urethrography in the ABNT group. All of UPP were bimodal, which was significantly different from the unimodal UPP of other standard RP (24). The first peak of the bimodal UPP, formed by ABNT, significantly improved FUL. Upright urethrography showed that a long tubularized neo-urethra was filled with contrast medium in the urination period (*Video 2*). During the storage period or interruption of urination, ABNT was filled with no contrast medium (*Video 2*). The UPP and urethrography results showed that the annular smooth muscle of ABNT continuously contracted and provided sufficient closing pressure during the storage period, supporting the improved early

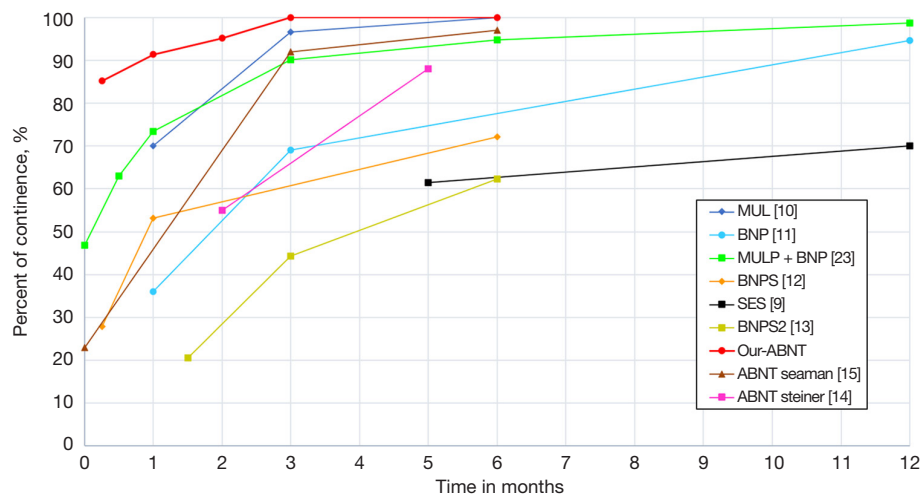


Figure 7 Continence rates of our ABNT and a series of techniques to preserve or reconstruct FUL. MUL, maximal urethral length; BNP, bladder neck preservation; MULP, maximal urethral length preservation; BNPS, bladder neck plication stitch; SES, sparing of external sphincter; ABNT, anterior bladder neck tube; FUL, functional urethral length.

continence rates after RP. In addition, ABNT can flexibly open and close under the control of consciousness and, thus, provided a longer effective sphincteric segment. Relevant studies have also shown the support for this view. The annular smooth muscle of anterior bladder neck was innervated with sympathetic nerve (25-27), suggesting that ABNT has fine synchronicity, harmonious with the natural IUS. In our study, no more urethral stricture developed in the ABNT group than in the control group (5.2% vs. 2.1%, $P=0.34$), whereas urethral stricture reached 12–22% in a previous series of open RP with ABNT (15,16). Compared with these surgeries, urethral stricture in this study was significantly reduced. This may be the advantage of robotic and laparoscopic RP over open RP. Additionally, these urethral strictures had been easily cured.

This study showed that ABNT technology was becoming a new way to immediately overcome urinary incontinence after RP. The limitations of the present study include that it entailed a retrospective comparison with a historical cohort. The urinary continence date was retrospectively collected from previous follow-up manuals and supplementary interviews by telephone. Prospective UPP and upright urethrography were only performed in the ABNT group. Further, this was not a prospective randomized study. Although all surgeries were performed by a single surgeon, all surgeries of the ABNT group were completed after those of the control group. Thirdly, this was a single-surgeon series, and others must corroborate our findings.

Conclusions

The ABNT is a simple technique in robotic and laparoscopic RP, has been shown to effectively reconstruct the functional IUS, and therefore improves early return of continence, especially the immediate continence without compromising PSM and stricture. This sphincter reconstruction not only greatly improves the quality of life after RP, but may also be applicable to other urinary incontinence caused by sphincter dysfunction. The limitations of the present study include the retrospective comparison with a historical cohort, lack of randomization, and the single center setting. A prospective, randomized, and multicenter evaluation is anticipated.

Acknowledgments

Funding: This work was funded by the Research on the Application of Urinary Tract “switch” Reconstruction Technology in Postoperative Urinary Incontinence after Radical Prostatectomy for Prostate Cancer (No. TZKY20220210).

Footnote

Reporting Checklist: The authors have completed the STROBE reporting checklist. Available at <https://tau.amegroups.com/article/view/10.21037/tau-23-583/rc>

Data Sharing Statement: Available at <https://tau.amegroups.com/article/view/10.21037/tau-23-583/dss>

Peer Review File: Available at <https://tau.amegroups.com/article/view/10.21037/tau-23-583/prf>

Conflicts of Interest: All authors have completed the ICMJE uniform disclosure form (available at <https://tau.amegroups.com/article/view/10.21037/tau-23-583/coif>). The authors have no conflicts of interest to declare.

Ethical Statement: The authors are accountable for all aspects of the work in ensuring that questions related to the accuracy or integrity of any part of the work are appropriately investigated and resolved. The study was conducted in accordance with the Declaration of Helsinki (as revised in 2013). The study was approved by the ethics board of The Affiliated Taizhou People's Hospital of Nanjing Medical University (No. KY2021-032-02) and informed consent was obtained from all individual participants.

Open Access Statement: This is an Open Access article distributed in accordance with the Creative Commons Attribution-NonCommercial-NoDerivs 4.0 International License (CC BY-NC-ND 4.0), which permits the non-commercial replication and distribution of the article with the strict proviso that no changes or edits are made and the original work is properly cited (including links to both the formal publication through the relevant DOI and the license). See: <https://creativecommons.org/licenses/by-nc-nd/4.0/>.

References

1. Ficarra V, Rossanese M, Crestani A, et al. Robot-assisted Radical Prostatectomy Using the Novel Urethral Fixation Technique Versus Standard Vesicourethral Anastomosis. *Eur Urol* 2021;79:530-6.
2. Vis AN, van der Poel HG, Ruiters AEC, et al. Posterior, Anterior, and Periurethral Surgical Reconstruction of Urinary Continence Mechanisms in Robot-assisted Radical Prostatectomy: A Description and Video Compilation of Commonly Performed Surgical Techniques. *Eur Urol* 2019;76:814-22.
3. Lane JA, Donovan JL, Young GJ, et al. Functional and quality of life outcomes of localised prostate cancer treatments (Prostate Testing for Cancer and Treatment [ProtecT] study). *BJU Int* 2022;130:370-80.
4. Hurtes X, Rouprêt M, Vaessen C, et al. Anterior suspension combined with posterior reconstruction during robot-assisted laparoscopic prostatectomy improves early return of urinary continence: a prospective randomized multicentre trial. *BJU Int* 2012;110:875-83.
5. Pessoa RR, Maroni P, Kukreja J, et al. Comparative effectiveness of robotic and open radical prostatectomy. *Transl Androl Urol* 2021;10:2158-70.
6. Yilin Z, Fenglian J, Yuanling W, et al. Predictors for lower urinary tract symptoms in patients underwent radical prostatectomy: implications for postoperative nursing care. *J Clin Nurs* 2022;31:1267-72.
7. Pfister C, Cappele O, Dunet F, et al. Assessment of the intrinsic urethral sphincter component function in postprostatectomy urinary incontinence. *Neurourol Urodyn* 2002;21:194-7.
8. Dubbelman YD, Bosch JL. Urethral sphincter function before and after radical prostatectomy: Systematic review of the prognostic value of various assessment techniques. *Neurourol Urodyn* 2013;32:957-63.
9. Lei Y, Alemozaffar M, Williams SB, et al. Athermal division and selective suture ligation of the dorsal vein complex during robot-assisted laparoscopic radical prostatectomy: description of technique and outcomes. *Eur Urol* 2011;59:235-43.
10. Hamada A, Razdan S, Etafy MH, et al. Early return of continence in patients undergoing robot-assisted laparoscopic prostatectomy using modified maximal urethral length preservation technique. *J Endourol* 2014;28:930-8.
11. Gu X, Araki M, Wong C. Continence outcomes after bladder neck preservation during robot-assisted laparoscopic prostatectomy (RALP). *Minim Invasive Ther Allied Technol* 2015;24:364-71.
12. Choi SK, Park S, Ahn H. Randomized clinical trial of a bladder neck plication stitch during robot-assisted radical prostatectomy. *Asian J Androl* 2015;17:304-8.
13. Beattie K, Symons J, Chopra S, et al. A novel method of bladder neck imbrication to improve early urinary continence following robotic-assisted radical prostatectomy. *J Robot Surg* 2013;7:193-9.
14. Steiner MS, Burnett AL, Brooks JD, et al. Tubularized neourethra following radical retropubic prostatectomy. *J Urol* 1993;150:407-9; discussion 409-10.
15. Seaman EK, Benson MC. Improved continence with tubularized bladder neck reconstruction following radical retropubic prostatectomy. *Urology* 1996;47:532-5.
16. Connolly JA, Presti JC Jr, Carroll PR. Anterior bladder

- neck tube reconstruction at radical prostatectomy preserves functional urethral length--a comparative urodynamic study. *Br J Urol* 1995;75:766-70.
17. Patel VR, Coelho RF, Palmer KJ, et al. Periurethral suspension stitch during robot-assisted laparoscopic radical prostatectomy: description of the technique and continence outcomes. *Eur Urol* 2009;56:472-8.
 18. Student V Jr, Vidlar A, Grepl M, et al. Advanced Reconstruction of Vesicourethral Support (ARVUS) during Robot-assisted Radical Prostatectomy: One-year Functional Outcomes in a Two-group Randomised Controlled Trial. *Eur Urol* 2017;71:822-30.
 19. Umari P, Eden C, Cahill D, et al. Retzius-Sparing versus Standard Robot-Assisted Radical Prostatectomy: A Comparative Prospective Study of Nearly 500 Patients. *J Urol* 2021;205:780-90.
 20. Bellangino M, Verrill C, Leslie T, et al. Systematic Review of Studies Reporting Positive Surgical Margins After Bladder Neck Sparing Radical Prostatectomy. *Curr Urol Rep* 2017;18:99.
 21. Hoeh B, Hohenhorst JL, Wenzel M, et al. Full functional-length urethral sphincter- and neurovascular bundle preservation improves long-term continence rates after robotic-assisted radical prostatectomy. *J Robot Surg* 2023;17:177-84.
 22. FLOCKS RH, CULP DA. A modification of technique for anastomosing membranous urethra and bladder neck following total prostatectomy. *J Urol* 1953;69:411-5.
 23. Heo JE, Lee JS, Goh HJ, et al. Urethral realignment with maximal urethral length and bladder neck preservation in robot-assisted radical prostatectomy: Urinary continence recovery. *PLoS One* 2020;15:e0227744.
 24. Dubbelman YD, Groen J, Wildhagen MF, et al. Urodynamic quantification of decrease in sphincter function after radical prostatectomy: relation to postoperative continence status and the effect of intensive pelvic floor muscle exercises. *Neurourol Urodyn* 2012;31:646-51.
 25. Tulloch AG. Sympathetic activity of internal urethral spincter. In empty and partially filled bladder. *Urology* 1975;05:353-5.
 26. Walz J, Epstein JI, Ganzer R, et al. A Critical Analysis of the Current Knowledge of Surgical Anatomy of the Prostate Related to Optimisation of Cancer Control and Preservation of Continence and Erection in Candidates for Radical Prostatectomy: An Update. *Eur Urol* 2016;70:301-11.
 27. Song LJ, Lu HK, Wang JP, et al. Cadaveric study of nerves supplying the membranous urethra. *Neurourol Urodyn* 2010;29:592-5.
- (English Language Editor: J. Jones)

Cite this article as: Xu Z, Zhao J, Guan Z, Guo M, Bian H, Li Z, Zhao W, Liang S, Liu Y, Zhang S, Wang J. Internal urethral sphincter reconstruction with anterior bladder neck tube for robotic and laparoscopic radical prostatectomy: improving early return of continence. *Transl Androl Urol* 2024;13(6):994-1003. doi: 10.21037/tau-23-583