

CASE REPORT



A case of dorsal oblique fingertip amputation

Shinsuke Takeda^a, Masahiro Tatebe^a, Akimasa Morita^b, Hidemasa Yoneda^a, Katsuyuki Iwatsuki^a and Hitoshi Hirata^a

^aDepartment of Hand Surgery, Nagoya University Graduate School of Medicine, Nagoya, Japan; ^bDepartment of Orthopaedic Surgery, Suzuka Kaisei Hospital, Suzuka, Japan

ABSTRACT

This study reports successful finger replantation in a patient with a dorsal oblique fingertip amputation. When repairing this unique type of injury, an evaluation of the remaining vessels is more useful for successful replantation than the anatomical zone classification. We propose that Kasai's classification is appropriate for guiding treatment.

ARTICLE HISTORY

Received 15 March 2017
Accepted 25 June 2017

KEYWORDS

Dorsal oblique fingertip amputation; Kasai's classification; replantation

Introduction

Although the fingertip is the most commonly injured part of the hand, dorsal oblique amputation of the fingertip is quite rare. These injuries are very difficult to reconstruct because there are few remaining intact vessels for vascular anastomosis. Both the stump status (clear-cut or not) and the survival of the distal transverse palmar arterial arch (DTPA) affect the possibility of replantation significantly. Here we report a rare case of dorsal oblique fingertip amputation.



Case report

A 43-year-old male carpenter presented with a dorsal oblique amputation of his left middle finger sustained while using a drill. The wound had a mildly blunt-cut surface. The injury occurred three hours before we began surgical repair. The amputated distal part of the finger included dorsal skin, the entire distal phalangeal bone, and the entire nail complex (Figure 1(a)). The DTPA remained intact at the proximal stump, and we found three DTPA branches. The ulnar branch to the fingertip was intact, and the other two were ruptured. One artery in the stump appeared to be the distal part of the central branch of the DTPA (Figure 1(b)). X-ray imaging revealed that the distal joint surface of the middle phalangeal head was injured. We fixed the distal interphalangeal (DIP) joint in approximately

30° flexion with two crossed 1.0 mm C-wires. We incised the radial side of the DTPA and anastomosed it to the central pulp artery of the distal stump using 11-0 nylon suture (Figure 2(a, b)). We then performed one venous anastomosis to prevent congestion of the replanted fingertip. We administered heparin (10,000 U/day) and prostaglandin (120 µg/day) for four days after the operation. The patient's postoperative course was uneventful, and he was discharged nine days after the operation. Three months later the patient returned to work. A radiograph revealed DIP joint non-union six months postoperatively, and the patient reported pain at the operative site. Therefore, we re-fixed the DIP joint using a DTJ screw (Double-threaded Japan screw, Meira Corp., Nagoya, Japan) with autogenous particulate cancellous bone from the ipsilateral distal radius. Bone union was achieved twelve months after the operation. The patient underwent a Semmes–Weinstein monofilament examination of dorsal fingertip sensory function and completed a Hand20 questionnaire. His scores on these tests were 3.61 and 0.5, respectively. He was satisfied with the postoperative appearance and function of the reconstructed fingertip (Figure 2(c)).

Discussion

Treatment decisions for a fingertip amputation are based on injury characteristics, amputation level and

CONTACT Katsuyuki Iwatsuki  kiwatsuki@med.nagoya-u.ac.jp  Department of Hand Surgery, Nagoya University Graduate School of Medicine, 65 Tsurumai-cho, Showa-ku, Nagoya 466-8550, Japan

© 2017 The Author(s). Published by Informa UK Limited, trading as Taylor & Francis Group.

This is an Open Access article distributed under the terms of the Creative Commons Attribution-NonCommercial License (<http://creativecommons.org/licenses/by-nc/4.0/>), which permits unrestricted non-commercial use, distribution, and reproduction in any medium, provided the original work is properly cited.

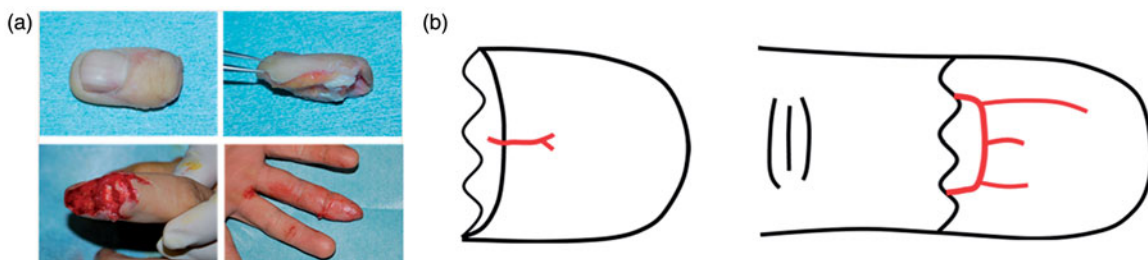


Figure 1. (a) Photograph of the dorsal oblique finger amputation. (b) Diagram showing the three branches of the DTPA. The ulnar branch was intact to the fingertip, and the other two were ruptured.

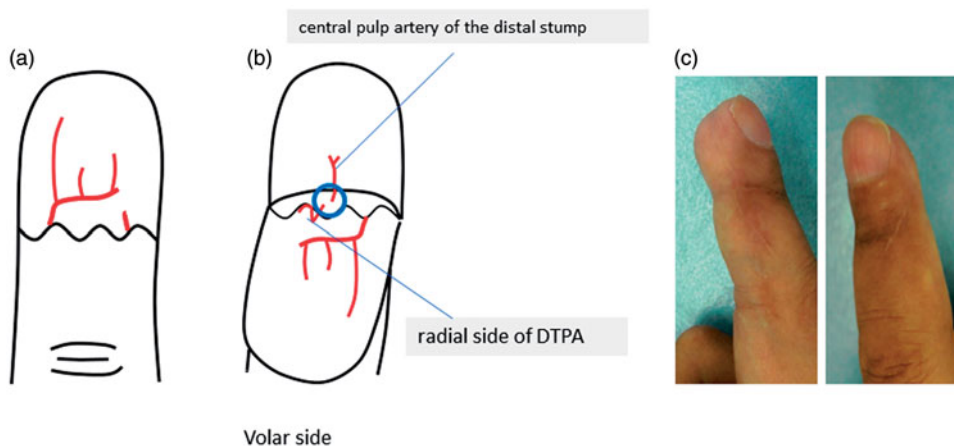


Figure 2. (a) Diagram showing the radial branch of the DTPA after cutting it. (b) The radial branch of the DTPA is anastomosed with the central pulp artery of the distal stump. (c) Photograph of the fingertip six months after replantation.

patient factors. Management techniques include closure of the amputation stump, primary coverage with an appropriate flap, and replantation [1]. Replanting the fingertip is thought to be the best way to preserve the nail and cosmetic appearance by maintaining the original finger length, and most Japanese patients prefer replantation for cultural reasons [2,3]. Further, the fingernail is important not only aesthetically but also to facilitate a powerful pinch. Although there are many ways to repair fingertip defects, very few methods allow preservation of the fingernail, especially in dorsal oblique fingertip amputations like our case. Another technique that may have value is partial toe-tip transfer. Regardless of the method selected, the presence of uninjured vessels for is essential for vascular anastomosis.

Our first bone fixation led to DIP joint non-union. We had excised the articular surface of the distal phalanx with attention to preventing irreversible vessel damage when fixing the DIP joint. This care was necessary as the central pulp artery of the distal stump was close to the volar side of the distal phalanx with little soft tissue. We selected C-wire pinning to avoid injury to the soft tissue and artery. However, using a

stronger fixation method initially may have prevented the non-union.

Tamai's classification [4] is widely used to classify distal amputations. In his classification, distal amputations are divided into two classes based on zone: zone I is distal to the nail fold, and zone II lies between the nail fold and DIP joint. A review of 30 studies representing 2,273 distal replantations, found 21 studies ($n=1107$) reported the success rate of Tamai zone I replantations (87%), while 19 studies ($n=617$) reported the success rate of Tamai zone II replantations (87%). There was no difference in survival between zone I and zone II replantations, and both had a high rate of survival [5]. There are several fingertip amputation classifications, such as the Ishikawa and the Allen, and most define zones based on the remaining vascular and bone anatomy. These are not always suitable for the clinical setting, because, as in this case of oblique amputation that extended over multiple zones, some injuries cannot be accurately classified. The indication for replantation is still controversial. However, the presence of intact vessels is essential for survival. Certainly, the level of difficulty of creating the anastomoses depends on the vascular

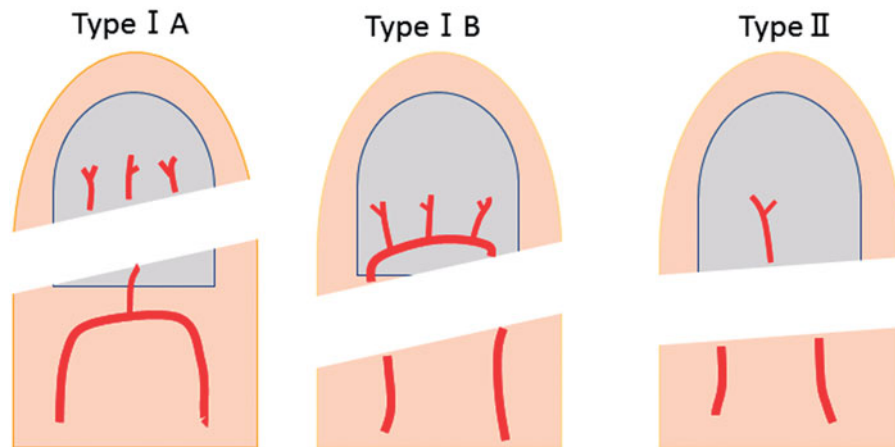


Figure 3. Kasai's classification: survival of the DTPA (type I) and loss of the DTPA (Type II). Type I is divided into two subtypes: the proximal DTPA is intact (Type IA), or the distal DTPA is intact (Type IB).

zone, and in most cases, the injury pattern is more useful for planning the replantation surgery than the anatomical zone.

Kasai's classification [6] based on the extent of DTPA loss is useful in that case (Figure 3). He distinguished fingertip amputations by survival of the DTPA (Type I) and loss of the DTPA (Type II). Type I injuries are further divided into two subtypes: the proximal part of the DTPA is intact (Type IA), or the distal part is intact (type IB). According to Kasai's classification, our case is type IA. Vascular anastomosis can be performed in more than 70% of type I cases while 25% require vascular repair with a vein graft. On the other hand, over 90% of Type II cases require vein grafting due to the absence of the DTPA proximally. We successfully avoided vascular congestion in the replanted fingertip by creating one venous anastomosis [7].

Conclusions

We present our case of successful finger replantation after dorsal oblique fingertip amputation. The vascular anatomy was more informative for planning the replantation than the anatomical zone. We propose that it is useful to consider the anatomic location of the surviving DTPA based on Kasai's classification of fingertip amputations when repairing a dorsal oblique fingertip amputation.

Disclosure statement

The authors report no conflicts of interest.

Funding

We received no funding for this study.

References

- [1] Woo SH, Kim YW, Cheon HJ, et al. Management of complications relating to finger amputation and replantation. *Hand Clin.* 2015;31:319–338.
- [2] Nishizuka T, Shauver MJ, Zhong L, et al. A comparative study of attitudes regarding digit replantation in the United States and Japan. *J Hand Surg.* 2015;40:1646–1656.e1–3.
- [3] Maroukis BL, Shauver MJ, Nishizuka T, et al. Cross-cultural variation in preference for replantation or revision amputation: societal and surgeon views. *Injury.* 2016; 47:818–823.
- [4] Tamai S. Twenty years' experience of limb replantation-review of 293 upper extremity replants. *J Hand Surg Am.* 1982;7:549–556.
- [5] Sebastin SJ, Chung KC. A systematic review of the outcomes of replantation of distal digital amputation. *Plast Reconstr Surg.* 2011;128:723–737.
- [6] Kasai T, Ogawa Y, Ishii S, et al. A new surgical classification and post-operative protocol following very distal replantation. *Orthop Proc.* 2009;91-B (Supp I): 96–97.
- [7] Hattori Y, Doi K, Ikeda K, et al. Significance of venous anastomosis in fingertip replantation. *Plast Reconstr Surg.* 2003;111:1151–1158.