

Claire M. Rice, MRCP,  
PhD  
Agyepong Oware, MRCP  
Sabine Klepsch, MD  
Beth Wright, MRCP  
Nidhi Bhatt, MD,  
FRCPath  
Shelley A. Renowden,  
FRCP, FRCR  
Megan H. Jenkins,  
MRCP  
Suchitra Rajan, MRCP  
Begoña A. Bovill, MRCP

*Neurol Neuroimmunol  
Neuroinflamm*  
2016;3:e236; doi: 10.1212/  
NXI.0000000000000236

## LEPROUS GANGLIONITIS AND MYELITIS

### OPEN

**Case report.** A 27-year-old Brazilian woman presented with a 7-month history of progressive pain, tingling, numbness, and weakness of the left upper limb, and paroxysmal dysesthesia affecting the left foot. On examination, there were erythematous, anesthetic patches of skin overlying the metacarpophalangeal joints and on the palmar surfaces of the hands (figure e-1 at [Neurology.org/nn](http://Neurology.org/nn)). There was congenital, bilateral campylodactyly and new flexion deformity of the fingers of the left hand with an incomplete range of passive extension. The intrinsic muscles of the left hand were wasted, particularly the thenar eminence and the dorsal interossei. Fasciculations were not observed. There was marked tenderness in the antecubital fossa and at the wrist, and the left superficial radial nerve was palpable. There was severe weakness of intrinsic finger movements, wrist flexion, and extension. Left upper limb reflexes were brisk and painful to percuss but tone, power, and reflexes including plantar responses were otherwise normal. Sensation to pinprick was reduced throughout the left hand with loss of temperature, vibration, and proprioceptive sensation distal to the wrist.

Routine laboratory blood tests were unremarkable and screening for *Strongyloides*, hepatitis, human T cell lymphotropic virus, and HIV were negative. MRI of the cervical spine (figure 1) revealed expansion of the cervical cord with an intramedullary, enhancing area of high signal at C5-C7 and ganglionitis. The signal changes were most apparent on short T1-inversion recovery pulse sequences. CSF analysis was not undertaken. There was neurophysiologic evidence of multifocal sensory and motor neuropathy with axonal degeneration and features of segmental demyelination (table e-1). Using sonography, the left ulnar, median at the wrist, and left distal superficial radial nerve were seen to be grossly enlarged (figure e-2, table e-2). Of note, there was focal enlargement of the ulnar nerve above the elbow.<sup>1</sup> No organisms were seen on microscopy or culture following an incisional skin biopsy (figure e-3). The epidermis was hyperkeratotic and mildly hyperplastic. Several well-defined non-necrotizing granulomas were seen in the dermis. These

were composed of epithelioid histiocytes, lymphocytes, and occasional Langhans giant cells. These were seen mainly in a perineural/periadnexal distribution but also involved the papillary dermis in an interstitial pattern. A focal lichenoid reaction was seen but a grenz zone was not present. Ziehl-Neelsen and Wade Fite stains for micro-organisms were negative, but S100 and epithelial membrane antigen antibodies highlighted residual nerve sheath cells and perineurium in among deeper granulomas.

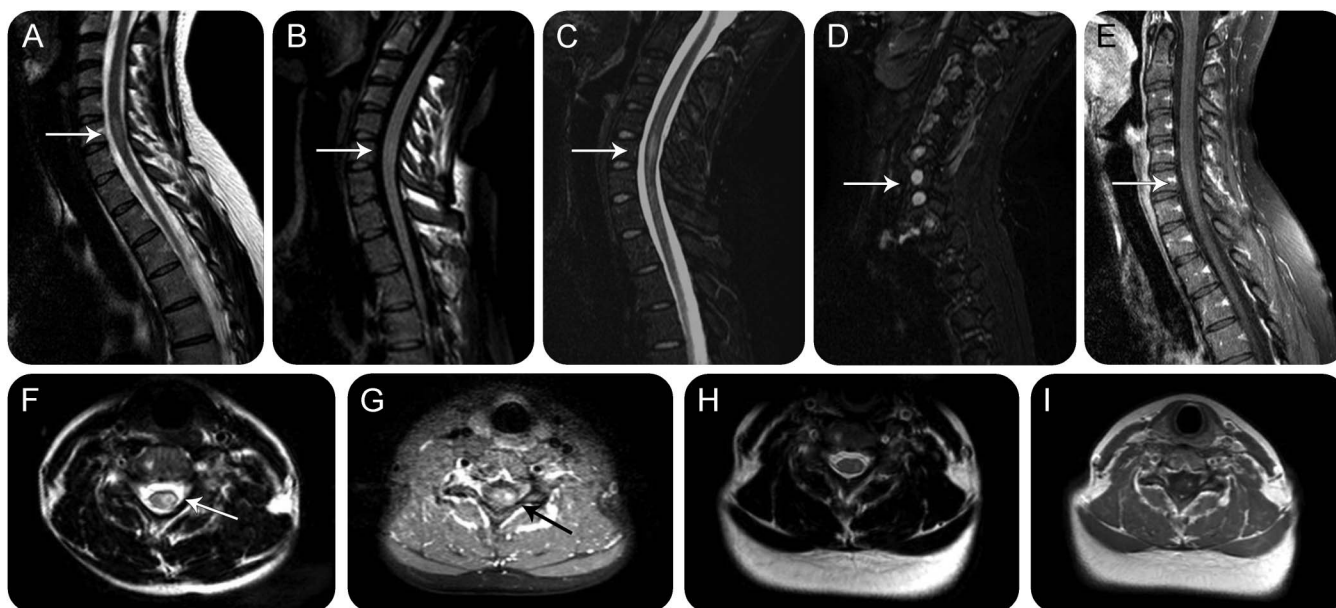
Treatment for borderline tuberculoid leprosy was initiated with prednisolone 40 mg with rapid resolution of pain; rifampicin and dapsone were added subsequently. Reduction in size of the peripheral nerves was confirmed on ultrasound although they remained enlarged (table e-2). Repeat neurophysiologic studies demonstrated resolution of distal left median conduction block. MRI of the cervical spine repeated 3 months after initiation of therapy showed partial resolution of the cervical cord lesion (figure 1). Those changes consistent with ganglionitis were also less marked.

A 6-month course of rifampicin and dapsone was completed and the dose of oral prednisolone gradually reduced over the same period. Hypopigmentation was seen on the hands and there was evidence of severe left ulnar and median neuropathies: clawing and wasting of the hand with well-preserved power in abductor pollicis brevis but paralysis of abductor digiti minimi and first dorsal interosseous. Anesthesia persisted in the distribution of the ulnar and median nerves in the left hand.

**Discussion.** Our patient has 2 of the 3 cardinal manifestations of leprosy—hypopigmented or erythematous hypoanesthetic skin lesions as well as enlarged and impaired peripheral nerves “of predilection.” The absence of acid-fast bacilli in slit skin smears is not unusual. Worldwide, there are few cases with MRI-confirmed leprous ganglionitis and myelitis. We have also demonstrated the utility of peripheral nerve ultrasound for monitoring treatment response.

The advantages of sonography for the detection of peripheral nerve disease are increasingly recognized.<sup>2</sup> Several recent studies have reported the clinical utility of peripheral nerve ultrasound in the diagnosis of leprosy,<sup>1,3–5</sup> but our case also demonstrates that treatment response can be monitored using sonography to document reduction in peripheral nerve size.

**Supplemental data at  
[Neurology.org/nn](http://Neurology.org/nn)**



Sagittal T2 (A), FLAIR (B), STIR (C), parasagittal STIR (D), gadolinium-enhanced T1 with fat saturation (E), and axial T2 (F, H), gadolinium-enhanced T1 with fat saturation (G), and gadolinium-enhanced T1 (I) MRIs. MRI demonstrated expansion of the cervical cord with intramedullary high T2 signal on the left at C5-C7 (A, F, and H). Intrinsic cord changes were poorly visualized on FLAIR (B) and were most marked on STIR (C) sequences. The dorsal root ganglia involving the left lower cervical ganglia were swollen and returned high T2 signal compatible with ganglionitis. The intramedullary cord changes showed a degree of enhancement with gadolinium (E, G, and I). Incomplete resolution of imaging changes was seen on repeat imaging at 3 months (H and I). FLAIR = fluid-attenuated inversion recovery; STIR = short T1-inversion recovery.

There is a paucity of literature on MRI of the spinal cord in leprosy; we found only one published report of MRI demonstration of lepromatous ganglionitis and myelitis not associated with spinal degenerative disease or concomitant infection.<sup>6</sup> We suggest that MRI, particularly with inclusion of short T1-inversion recovery sequences, is a sensitive, noninvasive investigation for the detection of both myelitis and ganglionitis secondary to leprosy although this requires confirmation in larger studies.

From the Departments of Neurology (C.M.R., S.K., B.W.), Neurophysiology (A.O., S.K.), Neuroradiology (S.A.R.), and Infectious Disease (M.H.J., B.A.B.), Southmead Hospital, Bristol; and Departments of Histopathology (N.B.) and Dermatology (S.R.), Bristol Royal Infirmary, Bristol, UK.

**Author contributions:** Claire M. Rice: drafting/revising the manuscript, analysis or interpretation of data, consultant neurologist responsible for investigation and care of patient described. Ageypong Oware: analysis or interpretation of data, acquisition of data. Sabine Klepsch: drafting/revising the manuscript, analysis or interpretation of data, acquisition of data. Beth Wright: drafting/revising the manuscript. Nidhi Bhatt: drafting/revising the manuscript, analysis or interpretation of data, acquisition of data. Shelley A. Renowden: drafting/revising the manuscript, acquisition of data. Megan H. Jenkins: drafting/revising the manuscript. Suchitra Rajan: drafting/revising the manuscript, contribution of vital reagents/tools/patients, obtained the tissue. Begona A. Bovill: drafting/revising the manuscript, clinical management of patient as infectious disease consultant in charge of case, submission and interpretation of clinical laboratory results, and clinical progress.

**Acknowledgment:** The authors are grateful to the patient for her permission to publish the case report. They also acknowledge the support and expertise of Professor Diana Lockwood (London School

of Hygiene and Tropical Health) whose advice regarding treatment and management has been greatly valued. C.M.R. is supported by the Burden Neurological Institute.

**Study funding:** No targeted funding.

**Disclosure:** C.M. Rice is a special edition coeditor for Current Treatment Options in Neurology, received research support from MS Trust. A. Oware reports no disclosures. S. Klepsch received speaker honoraria from Ipsen Pharma. B. Wright, N. Bhatt, S.A. Renowden, M.H. Jenkins, and S. Rajan report no disclosures. B.A. Bovill received travel funding from Gilead Pharmaceuticals. Go to [Neurology.org/nn](http://Neurology.org/nn) for full disclosure forms. The Article Processing Charge was paid by the authors.

This is an open access article distributed under the terms of the Creative Commons Attribution-NonCommercial-NoDerivatives License 4.0 (CC BY-NC-ND), which permits downloading and sharing the work provided it is properly cited. The work cannot be changed in any way or used commercially.

Received December 11, 2015. Accepted in final form March 18, 2016.

Correspondence to Dr. Rice: [c.m.rice@bristol.ac.uk](mailto:c.m.rice@bristol.ac.uk)

1. Bathala L, Kumar K, Pathapati R, Jain S, Visser LH. Ulnar neuropathy in Hansen disease: clinical, high-resolution ultrasound and electrophysiologic correlations. *J Clin Neurophysiol* 2012;29:190–193.
2. Goedee HS, Brekelmans GJ, van Asseldonk JT, Beekman R, Mess WH, Visser LH. High resolution sonography in the evaluation of the peripheral nervous system in polyneuropathy: a review of the literature. *Eur J Neurol* 2013;20:1342–1351.
3. Frade MA, Nogueira-Barbosa MH, Lugao HB, Furini RB, Marques Junior W, Foss NT. New sonographic measures of peripheral nerves: a tool for the diagnosis of peripheral nerve involvement in leprosy. *Mem Inst Oswaldo Cruz* 2013;108:257–262.

4. Elias J Jr, Nogueira-Barbosa MH, Feltrin LT, et al. Role of ulnar nerve sonography in leprosy neuropathy with electrophysiologic correlation. *J Ultrasound Med* 2009;28:1201–1209.
5. Visser LH, Jain S, Lokesh B, Suneetha S, Subbanna J. Morphological changes of the epineurium in leprosy: a new finding detected by high-resolution sonography. *Muscle Nerve* 2012;46:38–41.
6. Khadilkar SV, Kasegaonkar PS, Ursekar M. Spinal cord involvement and ganglionitis in leprosy. *Neurol India* 2007; 55:427–428.