

# An Update on Patent Ductus Arteriosus and What is Coming Next

Ömer Erdeve<sup>1</sup>, Emel Okulu<sup>1</sup>, Yogen Singh<sup>2,3</sup>, Richard Sindelar<sup>4</sup>, Mehmet Yekta Oncel<sup>5,6</sup>, Gianluca Terrin<sup>7</sup>, Giovanni Boscarino<sup>7</sup>, Ali Bülbül<sup>8</sup>, Hannes Sallmon<sup>9</sup>, Begüm Atasay<sup>9</sup>, Fahri Ovalı<sup>10</sup>, Ronald I. Clyman<sup>11</sup>

<sup>1</sup>Division of Neonatology, Department of Pediatrics, Ankara University, Faculty of Medicine, Ankara, Turkey

<sup>2</sup>Division of Neonatology, Loma Linda University School of Medicine, California, USA

<sup>3</sup>Cambridge University Hospitals NHS Foundation Trust, Cambridge, UK

<sup>4</sup>Department of Women's and Children's Health, Uppsala University, Uppsala, Sweden

<sup>5</sup>Division of Neonatology, Buca Seyfi Demirsoy Training and Research Hospital, İzmir, Turkey

<sup>6</sup>Division of Neonatology, Department of Pediatrics, İzmir Katip Çelebi University, Faculty of Medicine, İzmir, Turkey

<sup>7</sup>Department of Maternal and Child Health, University of Roma La Sapienza, Rome, Italy

<sup>8</sup>Division of Neonatology, Department of Pediatrics, University of Health Science, Şişli Hamidiye Etfal Education and Research Hospital, İstanbul, Turkey

<sup>9</sup>Department of Congenital Heart Disease/Pediatric Cardiology, Charité–Universitätsmedizin Berlin and Deutsches Herzzentrum Berlin (DHZB), Berlin, Germany

<sup>10</sup>Division of Neonatology, Department of Pediatrics, İstanbul Medeniyet University, İstanbul, Turkey

<sup>11</sup>Department of Pediatrics and Cardiovascular Research Institute, University of California San Francisco, San Francisco, CA, USA

## ABSTRACT

Patent ductus arteriosus is the most common cardiovascular condition in preterm infants. There is a significant uncertainty about when and how to close ductus arteriosus in preterm infants due to a high spontaneous closure rate even in very immature preterm infants. Diagnosis and management of patent ductus arteriosus remain a challenge for both neonatologists and pediatric cardiologists. Researchers have tried to define a balance between an expectant approach and active treatment in selected infants. This review aimed to focus on the pathophysiology and management of patent ductus arteriosus and to make suggestions about approaches that might eliminate the association of morbidities with patent ductus arteriosus.

**Keywords:** patent ductus arteriosus, preterm, conservative, medical, surgical, treatment

## INTRODUCTION

Although patent ductus arteriosus is the most common cardiovascular condition in preterm infants, it still remains an elusive condition that challenges neonatologists and pediatric cardiologists. Due to a high spontaneous closure rate even in very immature preterm infants, there is significant uncertainty about when and how ductus arteriosus closure in preterm infants should be attempted. Therefore, the management of patent ductus arteriosus in extremely preterm infants remains a topic of debate. Researchers have tried to define a balance between an expectant approach and active treatment in selected infants with hemodynamically significant patent ductus arteriosus.<sup>1-3</sup> Meta-analyses of trials using non-steroidal anti-inflammatory drugs have shown effectiveness in accelerating ductal closure, but no reduction in late neonatal morbidities regardless of the drugs used, indication, timing, gestational age, or route of administration.<sup>2-4</sup>

This updated review focuses on the pathophysiology and management of patent ductus arteriosus and makes suggestions about approaches that might eliminate the association of morbidities with patent ductus arteriosus in the future.

## MOLECULAR AND MECHANICAL MECHANISMS OF DUCTAL CLOSURE

Ductus arteriosus develops from the sixth embryonic arch along with other large vessels but the anatomical structure of the ductus is quite different from the aorta or pulmonary arteries (Figure 1). There is an internal lamina surrounded by a muscular layer. This muscular layer is supplied by vasa vasorum, which are quite scarce in preterm infants and smooth muscle cells (SMC) receive oxygen by diffusion from the lumen. There are many factors that keep

Corresponding author:

Ömer Erdeve

✉ [omererdeve@yahoo.com](mailto:omererdeve@yahoo.com)

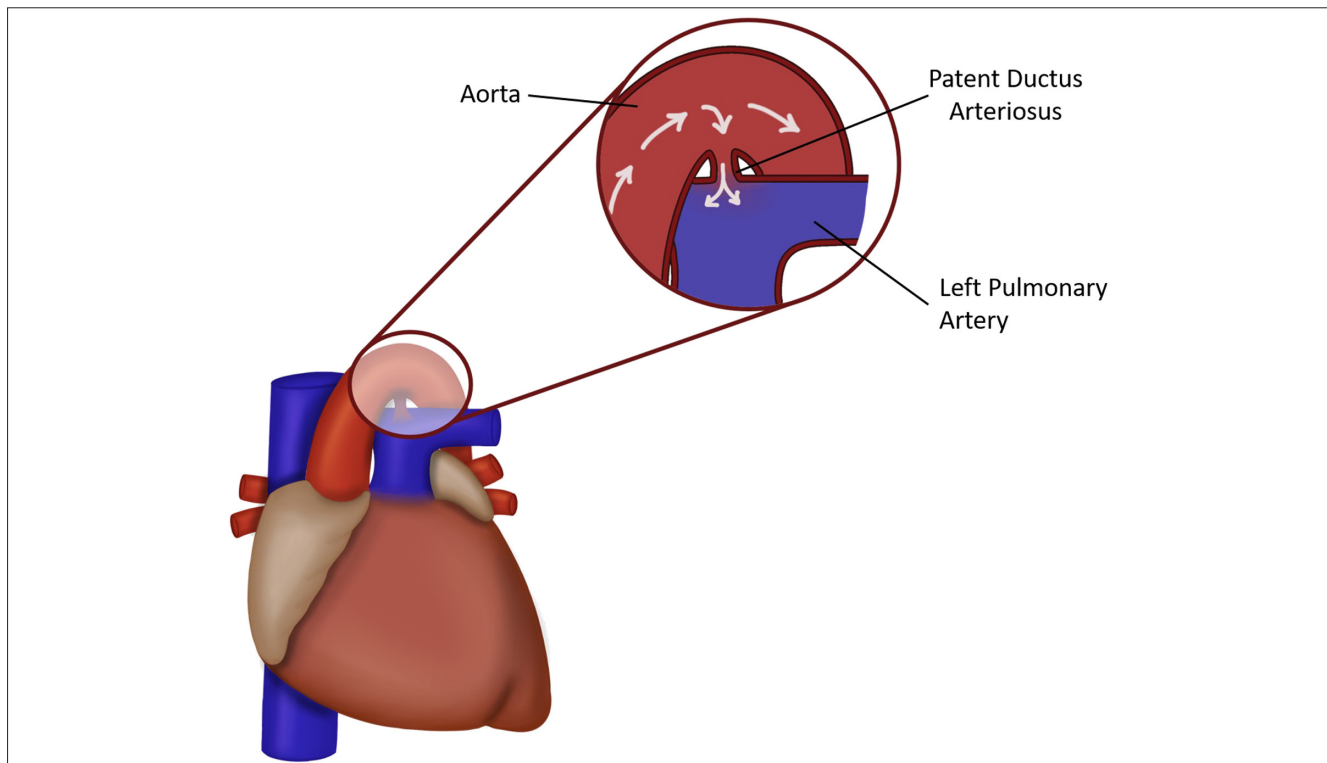
Received: December 23, 2021

Accepted: January 10, 2022

Content of this journal is licensed under a Creative Commons Attribution-NonCommercial 4.0 International License.



**Cite this article as:** Erdeve Ö, Okulu E, Singh Y, et al. An update on patent ductus arteriosus and what is next?. *Turk Arch Pediatri.* 2022;57(2):118–131.



**Figure 1.** Ductus arteriosus is the connecting vessel between the pulmonary trunk and the descending aorta.

the ductus open in fetal life, including low oxygen tension, high levels of prostaglandins, nitric oxide, and carbon monoxide, as well as high levels of adenosine, intracellular cyclic adenosine monophosphate and cyclic guanosine monophosphate, and an atrial natriuretic peptide which exert their effects through activation of potassium channels on the SMC membrane.<sup>5,6</sup>

Ductal closure occurs in 2 steps after the birth. Functional closure occurs by the decrease of prostaglandins which keep it open before birth. Cessation of placental blood flow, which is the production site of prostaglandins and increased lung circulation, where the prostaglandins are metabolized, contributes to the decrease of prostaglandins. Oxygen pressure within the ductal lumen rises sharply after birth, leading to vasoconstriction through the production of reactive oxygen species and oxidative phosphorylation and resultant inhibition of potassium channels and depolarization of the SMC membrane, leading to an influx of calcium into the cells and contraction of myosin elements in the cell. Mechanisms involving the cytochrome P450 enzyme systems, isoprostanes, retinoic acid, and Rho-kinase pathway also contribute to the oxygen-dependent constriction process (Figure 2).<sup>6-8</sup> The second step involves the anatomical closure which is mediated through intimal cushion formation; which takes place after the disassembly of the internal elastic lamina, loss of elastic fibers, migration and proliferation of SMCs, extracellular matrix production, and endothelial cell proliferation. In the term infant, increased intramural pressure leads to vasoconstriction of vasa vasorum and relative hypoxia of the muscular layer with resultant apoptosis. Since the vasa vasorum are not developed in the preterm infant, a greater degree of constriction is needed to achieve a similar

degree of hypoxia, which explains why the preterm ductus is more prone to reopening due to postnatal factors.<sup>7,9</sup> Retinoic acid, transforming growth factor-beta, interleukin-15, extracellular matrix production, and notch signaling also contribute to anatomical closure.<sup>5</sup> On the other hand, during the process of vasoconstriction, detachment of endothelial cells produces an injury site, where a platelet plug begins to form.<sup>10</sup> Genetic factors may be effective at various levels of these mechanisms. Mechanical factors including the pressure generated by the increased blood flow, fluid overload, and inflammatory factors mediated by cortisol levels may also affect the patency of the ductus.<sup>5</sup>

#### The Role of Platelets in Ductus Arteriosus Closure

Platelets are critically involved in murine ductus arteriosus closure.<sup>10</sup> Platelets are directly recruited to the ductal endothelium and promote vessel sealing by platelet plug formation and the release of vasoactive substances. While thrombocytopenia is a frequent finding in preterm infants, the clinical implications of low platelet counts in human preterm infants are still controversially discussed.<sup>11,12</sup> Several investigations have analyzed the role of low platelet counts in failed ductal closure (spontaneous and/or pharmacological).<sup>12-17</sup> The available data exhibit a high degree of heterogeneity in variables such as patient selection, the definition of hemodynamically significant patent ductus arteriosus (hsPDA), the timing of platelet counts and echocardiographic screening, and the treatment approach and have yielded conflicting results. Nonetheless, recent meta-analyses concluded that thrombocytopenia represents a moderate independent risk factor for both delayed spontaneous ductal closure and failed pharmacologic ductus arteriosus closure.<sup>18-20</sup>

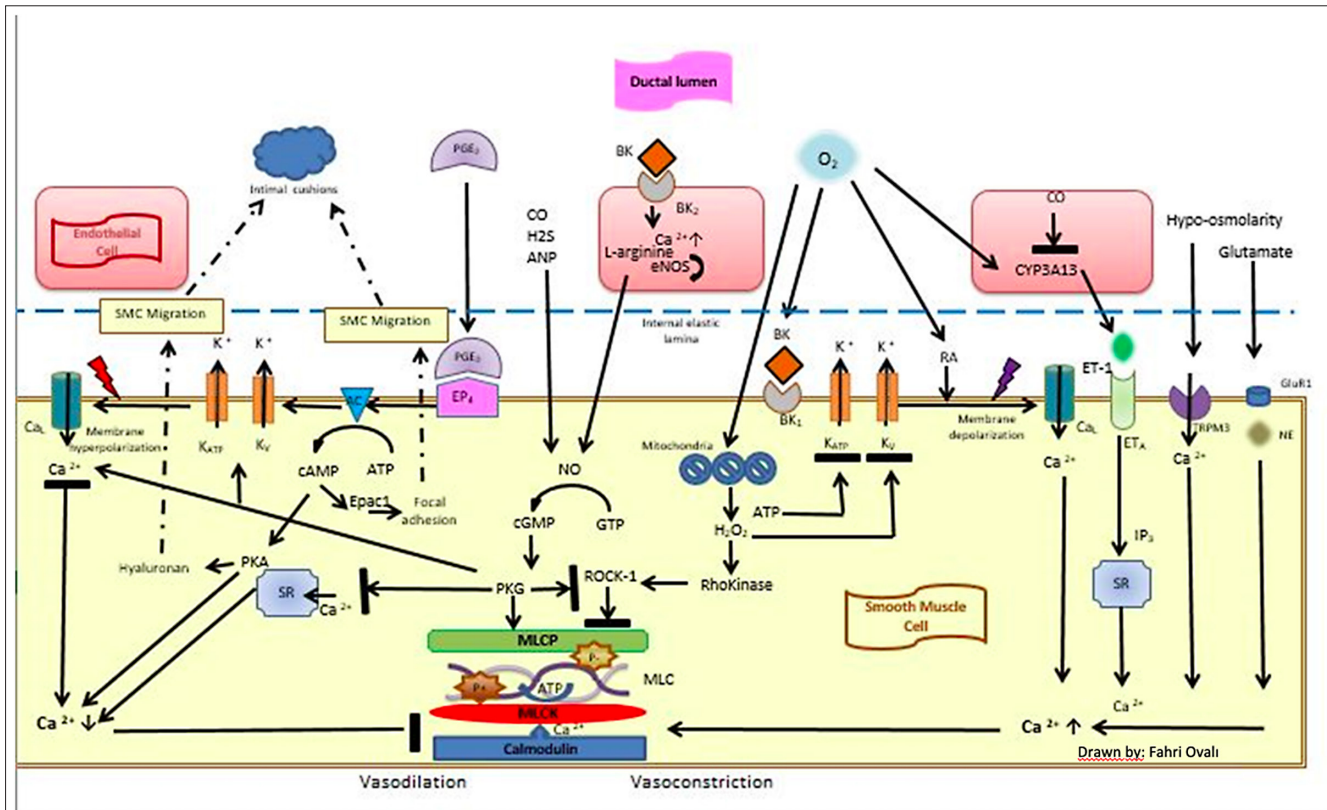


Figure 2. Vasoconstrictive and vasodilatory effects in the ductal smooth muscle cell (drawn by Fahri Ovalı<sup>6</sup>).

Furthermore, several studies suggest that impaired platelet function rather than platelet number is critically involved in the failure of ductus arteriosus closure in preterm infants.<sup>12,21-24</sup> In addition, a randomized-controlled trial on platelet transfusions failed to show any benefit for liberal versus restrictive transfusion thresholds on patent ductus arteriosus (PDA) closure rates in preterm infants, and liberal transfusion thresholds were associated with an increased rate of intraventricular hemorrhage (IVH).<sup>25</sup> Thus, platelet transfusions in thrombocytopenic preterm infants to facilitate PDA closure cannot be recommended.

In conclusion, thrombocytopenia and platelet dysfunction likely contribute to failed PDA closure in preterm infants. However, these effects are of only moderate clinical significance. Furthermore, platelet transfusions in thrombocytopenic preterm infants to facilitate PDA closure should be avoided as they were associated with an increased risk of IVH. Further research on the complex interplay between platelet count and function, other circulating blood cells and the ductal endothelium is warranted in order to understand the developmentally regulated process of ductal closure in preterm infants.<sup>12,21,26</sup>

### CLINICAL IMPACTS OF hsPDA

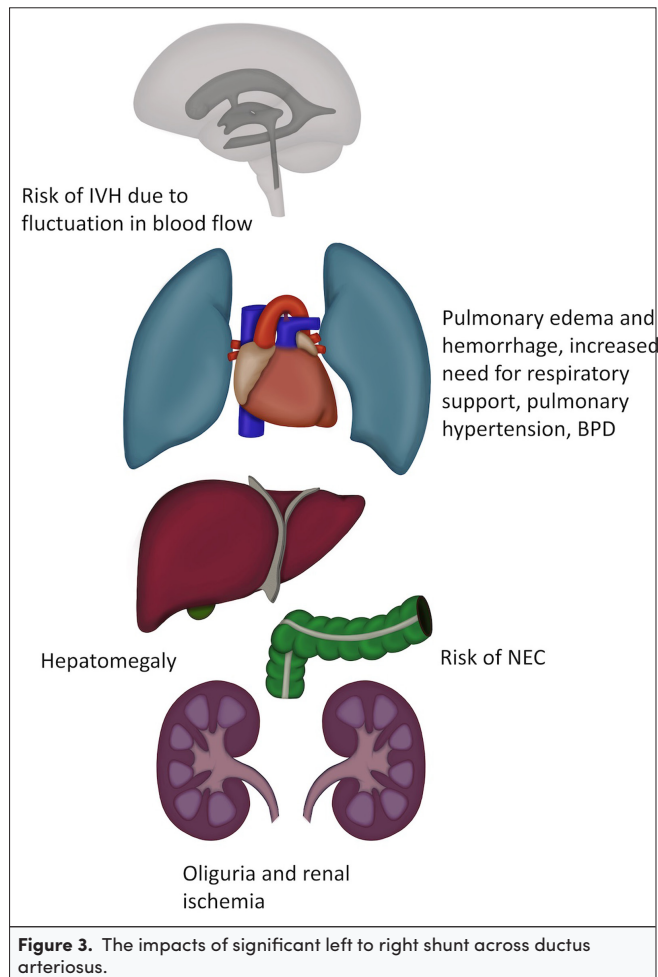
If the DA remains open, the postnatal adaptive decline in pulmonary artery pressure and the increases in left ventricular pressure and systemic vascular resistance result in a left to right shunting of the blood which leads to pulmonary over circulation

and a compromise in systemic blood flow. Besides systemic and pulmonary vascular resistance, the size and shape of the PDA, gestational and postnatal age, underlying medical risk factors, viscosity of the blood, chemical mediators and drugs used are decisive factors for the clinical deterioration that either acutely or chronically contributes to organ damage (Figure 3).<sup>27-29</sup>

Stealing blood flow from systemic to pulmonary circulation especially during the diastolic phase of circulation leads to decreased flow to organs resulting in organ compromise with the failure of autoregulation affecting the brain, myocardial, renal, and gut perfusion.<sup>27,28</sup> Although a hsPDA may have an impact on common neonatal morbidities, such as bronchopulmonary dysplasia (BPD), acute renal failure, necrotizing enterocolitis (NEC), pulmonary and IVH, neurodevelopmental impairment, and eventually mortality, clear evidence for a causal relationship between hsPDA and these conditions is scarce.

The instability between systemic and pulmonary circulation results in hypoxia, hypoventilation, and prolonged respiratory support. Lung injury with impaired alveolarization, infections and pulmonary overcirculation predisposes to chronic lung parenchymal changes. Prolonged intubation and prolonged exposure to moderate-to-large PDA shunt may cause an arrest in alveolar development and are thus considered to be causative factors in the development of BPD.<sup>30</sup>

Starting from the period of pressure passive circulation with the lack of autoregulation the pressure changes through a hsPDA



causes hypo-hyperperfusion and a plausible relationship is addressed for the development of IVH and white matter injury, resulting in neurodevelopmental compromise.<sup>27,28</sup> However, there is no strong evidence through randomized-controlled trials (RCTs) showing improvement by either prophylaxis or treatment.<sup>30,31</sup> Patent ductus arteriosus may cause renal hypoperfusion and renal failure presenting with oliguria and increased blood creatinine and hyponatremia. Brain natriuretic peptide (BNP) increases as a result of left ventricular volume overload and exhibits autoregulation through vasodilator and diuretic effects. Failure of compensation and ongoing exposure leads to renal failure and damage. Being a vasodilatory risk factor for NEC, treatment of hsPDA has not been shown to decrease the incidence.<sup>28</sup> We suggest that understanding the pathophysiologic association rather than causality between the PDA and clinical complications may further be possible through dynamic echocardiography, biochemical and clinical investigations of organ systems.

### ECHOCARDIOGRAPHIC DIAGNOSIS AND CLINICAL SIGNIFICANCE OF PDA IN PRETERM INFANTS

Patent ductus arteriosus of similar size can have varied phenotypic presentations in terms of clinical significance and hence, an echocardiographically large PDA does not equate to a clinically significant PDA. The clinical significance of PDA depends

upon the volume of shunt across the DA which primarily depends upon the systemic and pulmonary vascular resistance, ability of the myocardium to adapt to increased shunt volume, and size of the DA.<sup>32</sup> Hence, evaluation of PDA should include a comprehensive assessment of PDA characteristics and their hemodynamic impact in the clinical context.

Clinical features of a hsPDA include increased respiratory support and oxygen demand, number and severity of apnea and desaturations, feeding intolerance, radiologic evidence of cardiomegaly and pulmonary edema, presence of oliguria, mean or diastolic hypotension with or without metabolic acidosis requiring cardiotropic or vasopressor drugs.<sup>32-34</sup> However, most clinical signs have limited sensitivity in the first days of life and hence, there is a few days lag in clinical diagnosis of PDA as compared to echocardiography, which remains the gold standard investigation to evaluate PDA at the bedside.<sup>32,34</sup>

### Echocardiographic Evaluation in Assessment of Hemodynamic Impact of Shunt Volume

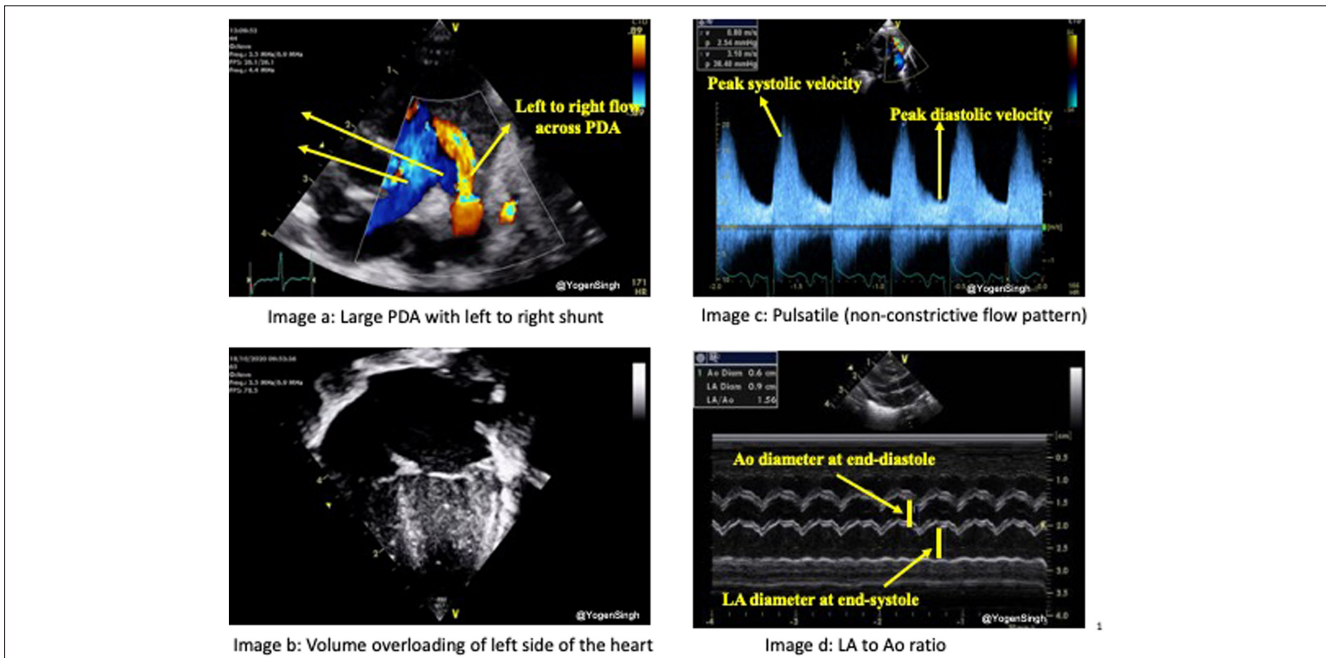
Echocardiography is used to make a confirmative diagnosis of PDA, assessing its hemodynamic significance, and excluding/diagnosing any associated congenital heart defect. It can help in estimating the magnitude of shunt volume and assessing its hemodynamic significance in assessing the hemodynamic impact from pulmonary overcirculation and systemic hypoperfusion due to shunt volume. A comprehensive echocardiographic evaluation should include assessment of (a) ductal characteristics, (b) parameters of pulmonary overcirculation, and (c) signs of systemic hypoperfusion (Figures 4 and 5).<sup>32</sup>

Various echocardiographic parameters have been described in the research setting as well as complex staging/scoring systems.<sup>35</sup> The essential echocardiographic parameters which clinicians can use in making a clinical decision on the bedside have been summarized in Table 1.<sup>32</sup>

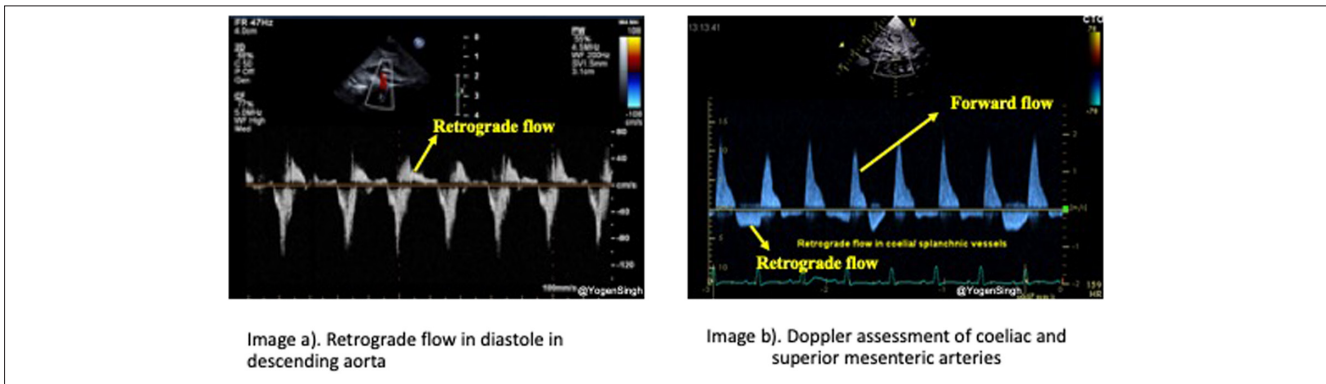
### The Roles of Cardiologist and Neonatologist in Diagnosis

Diagnosis and management of PDA remain a challenge for both neonatologists and pediatric cardiologists, and there is a growing interest worldwide in using the point of care ultrasound (POCUS) to evaluate cardiovascular function performed by a neonatologist in the neonatal intensive care unit (NICU). The use of cardiac ultrasound at the bedside to assess myocardial function, systemic and pulmonary blood flow, and intracardiac and extracardiac shunts is known as functional echocardiography.<sup>36</sup> The use of functional echocardiography in NICUs has been recommended in 3 expert consensus statements issued recently, with varied terms such as neonatologist performed echocardiography (NPE), targeted neonatal echocardiography, and POCUS.<sup>37-39</sup> The practical application of NPE, its availability, the experience of the clinician at performing this evaluation, and access to pediatric cardiologists' support remain diverse. Both neonatologists and pediatric cardiologists have concerns about the level of expertise of users, and the availability of training programs which may result in harm to infants caused by misdiagnosis and inappropriate management.<sup>40</sup>

The purpose of functional echocardiography is not intended to replace the detailed structural assessments provided by



**Figure 4.** Large PDA, volume overloading of heart, pulsatile flow pattern, and increased LA/Ao ratio.



**Figure 5.** Signs of systemic hypoperfusion—retrograde flow in ductus arteriosus and coeliac artery/superior mesenteric artery.

a pediatric cardiologist. NPE is used to diagnose a PDA and confirm normal structural cardiac anatomy. It is also used to identify patients who may benefit from treatment by estimating the hemodynamic consequences of the PDA to predict the spontaneous closure and morbidity risks.<sup>41</sup> According to consensus recommendations, the first echocardiography performed in an infant should include a full cardiac anatomy assessment to rule out severe structural defects. This requires specific training, expertise, and a thorough evaluation of pediatric cardiology. Centers may employ different collaborations depending on the expertise level of the neonatologist performing the scan and the availability of a pediatric cardiologist. If congenital heart disease is suspected, relevant referrals should be made.<sup>42</sup>

**CLINICAL SCORING SYSTEMS FOR PDA**

A number of PDA scoring systems have emerged with 3 fundamental goals. Among those, early prediction of hsPDA before echocardiography remains the main goal. The second

one is to document ductus closure, and the last is to decrease the number of echocardiographic assessments. In 1981, Cotton et al<sup>43</sup> reported a scoring system of 80% accuracy to predict the requirement for treatment that used birth weight, hyaline membrane disease, intrauterine growth retardation, acute perinatal stress, and distending airway pressure. Simultaneously, Yeh et al<sup>44</sup> identified a cardiovascular dysfunction (CVD) scoring which consisted of heart rate, quality of peripheral arterial pulsation, degree of precordial pulsation, duration of murmur, and cardiothoracic ratio on chest x-ray. A significant correlation between CVD score and echocardiographic findings, particularly LA/Ao ratio, was noted. That scoring was stated to be used as a clinical guide for treatment when echocardiography was unavailable. Recently, the New Short Clinical PDA Score was hypothesized to be beneficial for the detection and follow-up of hsPDA by Kindler et al.<sup>45</sup> That scoring system was comprised of precordial pulsations, bounding femoral pulses, apnea/mechanical ventilation, and metabolic acidosis. A sensitivity of 84% and a specificity of 80% were stated for the prediction of hsPDA on day 4 of life. The

| <b>Table 1. Summary of Essential Parameters Used for Echocardiographic Assessment and Hemodynamic Evaluation</b>  |   |
|---|---|
| <b>PDA evaluation criteria</b>  | <b>Essential echocardiographic parameters for assessment of PDA and hemodynamic evaluation</b>  |
| Ductal characteristics  | PDA size (small <1.5 mm, moderate 1.5 to 1-2 mm, large >2 mm) and Flow direction (left to right, right to left, or bi-directional), and Doppler assessment with maximum velocity (Vmax) in systole and end-diastole   |
| Assessment of pulmonary over circulation  | Dilated left side of the heart on visual inspection "eyeballing" and LA/Ao ratio (mild <1.4, moderate 1.41-1.6, severe >1.6) OR LVEDD (correlate with z-scores) OR LPA diastolic velocity—mean velocity >0.42 m/s, end-diastolic velocity >0.2 m/s OR Reversal of mitral E/A ratio*Document presence or absence and magnitude of intra-atrial shunt |
| Assessment of systemic hypoperfusion  | Retrograde or absent blood flow during diastole in: <ul style="list-style-type: none"> <li>- descending aorta OR</li> <li>- coeliac trunk or superior mesenteric artery OR</li> <li>- anterior or middle cerebral artery</li> </ul>   |
| <p>A comprehensive echocardiographic assessment should be performed to rule out any underlying congenital heart defect or pulmonary hypertension and delineate the orientation of arch (left- or right-sidedness) before any intervention to close the PDA.</p> <p>E/A ratio, the ratio of the velocity of the early (E) diastolic phase of ventricular filling vs. the late atrial (A) contraction component; LA/Ao, left atrium/aorta; LPA, left pulmonary artery; LVEDD, left ventricular end-diastolic diameter; PDA, patent ductus arteriosus; OR, operating room.</p> |   |

authors underscored the reduction of stress that the preterm babies are exposed to with fewer echocardiography. The SIMPLE scoring system (14 parameters and 0-3 points range) is the latest one that was designed for the prediction of hsPDA which possessed a sensitivity of 92% and a specificity of 85% in the sixth hour of life (cut-off >8.5), and sensitivity 100% and a specificity of 94% at the 72nd hour of life (cut-off >6).<sup>46</sup> SIMPLE scoring may be used as a screening tool to determine the necessity for echocardiography in extremely preterm infants to minimize the number of pediatric cardiology consultations. However, large-scale studies are warranted to validate these results.

### Echocardiographic Scoring Systems for PDA

Echocardiography remains the gold standard method for the diagnosis of PDA. Nevertheless, the echocardiographic findings have not been standardized for the decision on treatment. From this point of view, 2 PDA severity scoring systems have been created using echocardiographic parameters for the estimation of significant morbidity and mortality in patients with PDA. The first one by El-Khuffash et al<sup>47</sup> assessed the parameters of the ductal diameter, gestational age (GA), left ventricular output,  $V_{max}$  across PDA (m/s), and left ventricular late-diastolic velocity. The Shaare Zedek score proposed another scoring system utilizing the diameter of ductus arteriosus, LA/Ao ratio, retrograde diastolic flow in the abdominal aorta, and pattern of ductus arteriosus shunt flow. Each of these parameters was scored 0-2 giving a composite score ranging between 0 and 8. PDA was categorized as hemodynamically significant ( $\geq 6$  points), borderline significant (3-5 points), and non-hemodynamically significant (0-2 points). These 2 scoring systems seem to have similar and decent predictability for the diagnosis of hsPDA, chronic lung disease, or death.<sup>48</sup>

### METHODS OTHER THAN ECHOCARDIOGRAPHY

Various methods to improve the assessment of physiological variables resulting from hsPDA have been examined in clinical studies beyond echocardiography.

### Platelet Count and Platelet Indices

It has been demonstrated that there is a significant relationship between PDA and thrombocytopenia on the first day of life in a meta-analysis conducted by Simon et al.<sup>49</sup> The recently updated meta-analysis provides stronger evidence of the association between low platelet counts and PDA/hsPDA.<sup>18</sup> However, it is unclear if the low platelet count is secondary to preterm infants' immaturity and clinical stability rather than a contributing factor in the pathogenesis of PDA. Some studies have shown that other platelet indices such as platelet distribution width, mean platelet volume, platelet crit (PCT), platelet mass are probably related to hsPDA, and platelet dysfunction has been found to affect the spontaneous closure of PDA.<sup>23,50,51</sup> In a recent systematic review and meta-analysis, it has been concluded that platelet count, PCT, and platelet mass of the first 3 days of life are potentially helpful in identifying infants at risk for hsPDA.<sup>20</sup>

### Cardiac Peptides

ProBNP is secreted from myocytes in the cardiac ventricles as a result of pressure and volume loading, and then cleaved into the biologically active BNP and the inert N-terminal proBNP (NT-proBNP).<sup>52</sup> These cardiac biomarkers have been studied extensively for early detection and monitoring of hsPDA alone or in combination with echocardiography. The urinary excretion of NT-proBNP levels was found to be higher in infants with moderate-to-severe PDA, and these levels were shown to decrease significantly when PDA was closed after medical treatment.<sup>53</sup> In another study, it was shown that urinary NT-proBNP and NT-proBNP/creatinine ratio was higher in infants treated for hsPDA which indicated that these markers were helpful to show the effects of hsPDA on clinical and cardiac status of the infant.<sup>54</sup>

Cardiac troponin T (cTnT) levels were found to be correlated with echocardiographic markers of PDA.<sup>55</sup> El-Khuffash et al<sup>56</sup> reported that serum cTnT and NT-proBNP levels were found to be higher in babies born before the 32 gestational weeks who died before discharge or who were severely disabled babies at the age of 2 years.

Although these studies support the potential use of biomarkers in assessing ductal significance, there is not enough evidence to recommend their use for routine clinical management of a PDA.<sup>57</sup>

### Near-Infrared Spectroscopy and Perfusion Index

Near-infrared spectroscopy is a non-invasive method that continuously measures regional tissue oxygenation. Near-infrared spectroscopy monitoring can help early detection of hsPDA by identifying impaired renal, cerebral and mesenteric circulation, and continuous monitoring of changing oxygen dynamics in the presence of hsPDA. Near-infrared spectroscopy data may be useful when combined with current clinical and echocardiography findings and biomarkers.<sup>58,59</sup>

Perfusion index (PI) is a simple, continuous parameter provided by pulse oximetry to access peripheral perfusion. A recent study showed that daily assessed PI histograms can predict PDA that requires treatment. PI may be a useful adjunct to help identify preterm infants who are prone to circulatory complications of hsPDA.<sup>59,60</sup>

The data provided by biomarkers and continuous monitoring techniques are encouraging to detect the hemodynamic disturbance due to PDA/hsPDA. Most of these indicators do not have defined reference values in preterm infants, and hence it is necessary to determine if these parameters and subsequent actions lead to improvements in short- or long-term outcomes.

## MANAGEMENT OF PDA

### Conservative Management: What have we Learned from RCTs?

Currently, it is not clear which is preferable, to close the PDA (either pharmacologically or surgically) in the newborn period, or to deal with the PDA-induced pulmonary edema and hypotension more “conservatively” (with inotropes, diuretics, fluid restriction, and increased end-expiratory pressure) while awaiting spontaneous PDA closure.<sup>61-67</sup> Randomized-controlled trials, which compared “prophylactic” PDA treatment (starting within 12 hours of birth) with delayed treatment later in the first postnatal week, reported a decrease in several short-term morbidities (severe early pulmonary hemorrhage, dopamine-dependent hypotension, need for higher levels of ventilator support, and need for surgical PDA ligation) but no difference in the incidence of long-term morbidities like BPD, NEC, or neurodevelopmental impairment.<sup>68-74</sup> In addition, 40-50% of the prophylactically treated infants were treated unnecessarily since their PDA would have closed spontaneously by 7 days.<sup>75</sup>

Several recent RCTs have attempted to determine whether exposures to moderate-large PDA shunt that persist for more than a week affect morbidity.<sup>3,76-78</sup> These trials enrolled infants <28-29 weeks' gestation with moderate-large PDA shunts which were likely to persist for several weeks. Two trials compared early routine treatment starting at 8 days with a conservative, expectant management approach.<sup>3,76</sup> Both trials suffered from having a low rate of PDA closure in the early intervention group resulting in prolonged PDA exposure (>14 days) in both groups. Neither trial observed a difference

in the incidence of BPD, NEC, or mortality. Similar problems (either unexpectedly low rates of drug-induced PDA closure or high rates of spontaneous closure) existed in 2 additional pilot RCTs, that enrolled infants within 72 hours of birth.<sup>77,78</sup> Future RCTs will clearly need more effective PDA closure strategies.

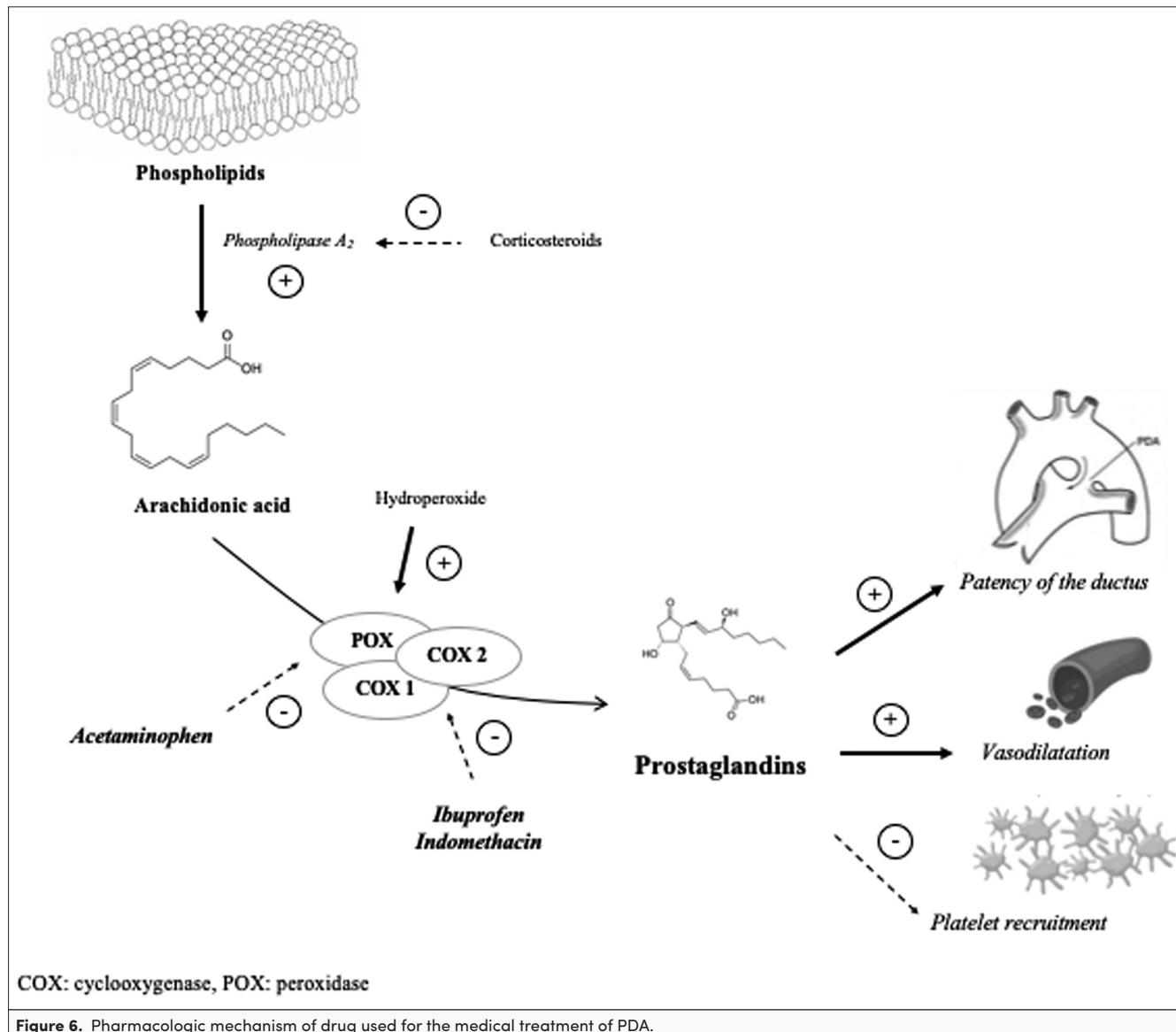
Another challenge for future RCTs is determining who should be enrolled, i.e., who really is at risk for increased morbidity from a PDA. Recent studies have shown that an association between PDA and BPD only exists in infants with moderate-to-large shunts persisting beyond 7-14 days who also require mechanical ventilation/tracheal intubation for  $\geq 10$  days.<sup>79-85</sup> This suggests that routine early PDA closure may be unnecessary for infants requiring intubation for <10 days. None of the RCTs reported to date have focused primarily on infants intubated for  $\geq 10$  days. All RCTs have been diluted with infants for whom persistence of the PDA had little or no consequence. Early screening tools need to be developed to determine which infants should be enrolled in trials and which should be excluded.<sup>47</sup>

What we do know is that neither a delay of 2 to 5 days before starting PDA treatment during the first week nor routine treatment that starts only after infants have been exposed to a moderate-to-large shunt for more than 2 weeks appear to affect the incidence of BPD. Whether exposure to a moderate-to-large PDA shunt for more than the first 7-14 days actually contributes to the development of BPD is a question that awaits testing in appropriately designed RCTs. Future trials should be designed to determine which infants are most likely to benefit from PDA treatment and which infants might best be left untreated.

### Medication Options: Which Drug?

Indomethacin, ibuprofen, and acetaminophen are the most common and effective pharmacologic agents used as a prophylactic or symptomatic treatment of PDA. The pharmacologic action of these drugs is to inhibit the cyclooxygenase and peroxidase, with a consequent inhibition of prostaglandin synthesis (Figure 6). The prostaglandin reduction results in muscular constriction of the ductus with profound hypoxia in the ductal vasa vasorum. Together with platelet recruitment, these phenomena result in obstruction, fibrosis, and anatomic closure of PDA. Prophylactic treatment usually begins within 24 hours after birth, before the PDA becomes clinically or hemodynamically significant. Symptomatic treatment can be further divided in early, when treatment starts as soon as PDA diagnosis is made, even if it is not yet hemodynamically significant, or late when only hemodynamically significant PDA is treated. No major differences in the efficacy between the 3 agents have been described in comparative effectiveness trials as far as closure of the PDA is concerned. However, wide variations in dosage and in the ability of different medical treatments to directly affect cerebral and renal perfusion have been reported.<sup>86</sup>

The RCTs that compare ibuprofen vs. indomethacin, observed a similar efficacy on the rate of PDA closure and reopening.<sup>87</sup> The RCT of Patel et al<sup>88</sup> reported a significant increase in the risk of surgical ligation in newborns treated with ibuprofen in comparison with indomethacin. However, 5 of 13 RCTs comparing non-steroidal anti-inflammatory drugs (NSAIDs), suggested an



improvement of urinary output in newborns treated with ibuprofen<sup>87</sup> and Yadav et al<sup>89</sup> also reported a reduced mortality rate in newborns treated with ibuprofen. RCTs comparing ibuprofen vs. acetaminophen, found a similar efficacy in PDA closure, reopening, and need of surgical ligation.<sup>90,91</sup> Dani et al<sup>92</sup> reported a reduced rate of PDA closure in newborns treated with acetaminophen vs. ibuprofen (52% vs. 78%), but, if we consider PDA constriction, the rate was similar between newborns treated with acetaminophen or ibuprofen. Ghanem et al<sup>93</sup> demonstrated a significant difference in the rate of the PDA closure in newborns treated with ibuprofen (94%) versus placebo (30%), however, Sangstawsin et al<sup>94</sup> found a similar rate of PDA closure or surgical ligation need.

A number of trials comparing indomethacin (0.1-0.3 mg/kg every 12-24 hours for a total of 3 doses) versus placebo were performed in the last 2 decades of the past century.<sup>95</sup> Some out of these trials, reported an increased rate of PDA closure in newborns treated with indomethacin; however, other RCT showed a similar closure rate,<sup>95</sup> while

Gersony et al<sup>96</sup> demonstrated an increased rate of PDA closure in the placebo group compared with the intervention group. Van Overmeire et al<sup>97</sup> compared the efficacy of early versus late treatment with indomethacin, and found a significantly increased rate of PDA closure in newborns who received early treatment. Similar efficacy was observed by Dash et al<sup>98</sup> comparing acetaminophen vs. indomethacin. Finally, a placebo-controlled randomized trial, demonstrated a significant increase in the efficacy of the acetaminophen compared to placebo.<sup>73</sup> Analysis of literature suggested that the effectiveness of medical treatment depends not only on the drug but also on the timing, doses, route of administration and duration of therapy, and most importantly on the maturity of the infant being treated.<sup>99,100</sup> Conflicting data come from studies comparing high doses (15-20 mg/kg followed by 7.5-10 mg/kg every 12-24 hours for a total of 3 doses) with standard doses (10 mg/kg followed by 5 mg/kg every 12-24 hours for a total of 3 doses) of ibuprofen. Three out of 4 studies, comparing the efficacy of intravenous ibuprofen versus oral administration, suggested an increase in



the effectiveness of the oral route.<sup>95</sup> This applies to the first course of treatment, while the rate of closure is similar to the end of the second course of therapy. On the other hand, combined treatment (paracetamol+ibuprofen) has been shown to be effective for monotherapy-resistant hsPDA by Yurttutan et al.<sup>101</sup>

If we consider only the results of studies conducted in the last decade, we can observe that ibuprofen has greater efficacy than paracetamol (15 mg/kg/dose 4 times a day for 3-7 days) and a lower risk of side effects than indomethacin and that treatment with ibuprofen seems to be more effective when carried out early and orally.<sup>95</sup> However, in the vast majority of the clinical trial, no significant difference in mortality and morbidity rate was observed between the main three pharmacologic options.<sup>91</sup>

### Transcatheter Closure of PDA From Bench to Clinical Practice

Recently there has been an increased interest in transcatheter closure of PDA, and whether this approach can be used as an alternative to surgical ligation or even to medical treatment in preterm infants. The procedure has been well-described in preterm infants, including extremely preterm infants as small as 640 g.<sup>102,103</sup>

Several cohort studies have reported promising results from transcatheter closure of PDA in preterm infants, including extremely preterm infants, and they have published their experience using various devices for PDA closure in premature infants.<sup>102-106</sup> Comparison with surgical ligation revealed a positive impact on the post-procedure pulmonary outcome.<sup>102,107</sup> Recently Amplatzer Piccolo Occluder® device has been approved by FDA and CE for transcatheter closure of PDA in premature infants over 700 g and over 3 days old.<sup>107</sup> Prior to the procedure, a comprehensive transthoracic echocardiography should be performed for the ductal parameters described above and its hemodynamic significance (left heart dilation, functional mitral/aortic regurgitation, and ductal morphology). In most centers, transcatheter closure is usually performed in the catheterization laboratory, although in some centers with portable fluoroscopy equipment the procedure can be performed at the bedside, especially in very unstable patients unsafe to move or when there is no access to the cardiac catheterization lab.<sup>102</sup> Transcatheter closure at the bedside under echocardiography guidance only has also been reported.<sup>105</sup> However, bedside procedure under echocardiography guidance only has to be performed via the trans-arterial route (femoral route) without fluoroscopy which carries an increased risk of potentially severe life-threatening complications such as limb ischemia. More worryingly, it has limited management options for device embolization if it occurs.<sup>108,109</sup>

Transcatheter closure is becoming the standard of care when definitive intervention is required to close the PDA. Studies have shown that it is not only possible to close PDA via this route but also has less complications and better outcomes as compared to surgical ligation.<sup>102</sup> Currently, it is still reserved for infants who had a failure of pharmacological therapy or where it was contraindicated.

### Surgical Ligation: Bedside or Operating Theater?

The risks with performing bedside operations on critically ill newborn term and preterm infants have been weighed against the risks of transportation within or between hospitals (extubation, hypothermia, hemodynamic instability, loss of vascular access, etc.), but also against the differences in the management of perioperative ventilation and surveillance between units performing the operative procedures and the NICU.<sup>110-114</sup> Common invasive bedside procedures such as insertion of central lines, umbilical catheters, and chest tubes necessitate rigorous antiseptic measures, wherefore surgical interventions such as peritoneal drainage/dialysis, silastic silo placement in gastroschisis, and other gastro-surgical procedures have been performed in the NICU environment with reasonable high quality and benefit to the critically ill infant.<sup>114-117</sup> Some of the surgical interventions in the NICU have also been motivated by the urgency of these procedures.

Since the first reports from the early 1980s on bedside PDA surgery in the NICU, the strategy of performing PDA ligation close to the infant has been established as one of the most common surgical interventions in NICUs in many parts of the world and has been regarded to be both safe and cost-effective.<sup>117-119</sup> Nevertheless, the assessment of bedside PDA surgery has been driven more by necessity and presumed benefits to the patients than by evaluation in RCTs, where many reports are retrospective and therefore liable to bias. Many albeit small observational retrospective studies on bedside PDA surgery in ventilator-dependent preterm infants (range: 23-32 GA weeks; mean postnatal age 16-32 days on the day of surgery) have reported that there are no additional surgically associated complications.<sup>120-123</sup> The surgical approach applied is usually the posterolateral thoracotomy, but in a small retrospective study mini-sternotomy appeared to be associated with shorter postoperative mechanical ventilation and length of stay.<sup>123</sup> In a recent large multicenter retrospective study comparing PDA ligations in the operating room (OR) and the NICU, no differences in mortality or sepsis could be detected after correcting for differences in GA, besides an increased postoperative hemodynamic instability in the OR group.<sup>124</sup> Similar findings with no differences in mortality or complications after PDA ligation performed either in the OR or the NICU were presented in a 2-center retrospective cohort study from 2021, with a significantly earlier closure in the NICU group by 24 days.<sup>125</sup>

The difficulty to define early hsPDA and the trend toward a less aggressive approach to treat PDA surgically during the last decade, have shown that postponing surgical treatment of late hsPDA in cases of failed medical treatment is both feasible and even safer in terms of reduced severe neurodevelopmental impairment.<sup>126-128</sup> Therefore, if there is a need of closing an hsPDA at a later stage, other less traumatic treatment options might be preferred such as catheter-based PDA closure under fluoroscopic or echocardiographic guidance.<sup>129,130</sup>

### LONG-TERM CONSEQUENCES

In the preterm lung, there is a delicate balance between increased fluid infiltration induced by PDA and lung lymphatic fluid reabsorption. Any increase in pulmonary microvascular pressure can cause a sudden increase in interstitial and

alveolar lung fluid because the premature newborn has low oncotic pressure and high capillary permeability.<sup>72</sup> This inadequate structural development and function of the pulmonary vessels is an important feature of BPD.<sup>131</sup> The existence of a relationship between systemic pulmonary blood flow after birth results in increased blood flow through an immature pulmonary vascular bed that can lead to vascular remodeling with intimal fibrosis and medial hypertrophy. This may result in increased pulmonary vascular resistance and abnormal vaso-reactivity. Similar features are often seen in infants with severe BPD with prolonged oxygen exposure and hsPDA.<sup>132,133</sup> A meta-analysis of cohort studies published in 2018 confirmed previous results of the association between BPD and cognitive outcomes in very preterm infants.<sup>134</sup> In addition, adjustments for potential mediators, postnatal steroids, and BPD in recent studies did not alter the association between PDA treatment and the risk of adverse neurodevelopmental outcomes. Future studies should clarify the role of PDA and how BPD develops and further examine its role in neurodevelopmental outcomes.<sup>134</sup>

It is difficult to distinguish the role of PDA in neurodevelopmental outcomes versus the effect of PDA treatments. A study of indomethacin prophylaxis in preterm infants revealed that IVH rates were reduced after prophylactic indomethacin, but with no long-term benefit.<sup>70</sup> Data for prophylactic ibuprofen or paracetamol are less convincing.<sup>135,136</sup> Prophylactic surgical ligation provides no benefit for IVH and surgical ligation itself may be an independent risk factor for impaired neurodevelopmental outcome.<sup>137-139</sup>

Rheinlaender et al evaluated the long-term outcome parameters in preterm infants with PDA and reported that the use of IV ibuprofen or indomethacin for closure of PDA did not influence 2-year neurodevelopmental outcomes in preterm infants.<sup>140</sup> Similarly, another study in preterm infants who received either oral ibuprofen (n = 30) or intravenous ibuprofen (n = 27) for PDA demonstrated that the long-term outcomes of the treatment regimens did not significantly differ at the age of 2 years.<sup>141</sup> Infants treated with paracetamol were found to have similar neurodevelopmental outcomes at adjusted ages of 18-24 months compared with infants receiving ibuprofen.<sup>142</sup> This cohort was planned to be evaluated in terms of autism as a continuation of the study because there is speculation that paracetamol may be associated with autism and autism spectrum disorder. A 5-year follow-up study of a placebo-controlled paracetamol trial on very preterm infants was conducted in Finland.<sup>143</sup> The questionnaire included children's cardiac and respiratory symptoms, allergies, neurodevelopment, infections, medications, and hospitalizations. It was detected that paracetamol use in premature infants did not increase long-term respiratory morbidities. Since there were 19 cases in the paracetamol group in this study, large-scale studies with more cases are needed to evaluate them in terms of adverse outcomes, such as autism spectrum disorders and attention-deficit/hyperactive disorder.

In 2020, Gudmundsdottir et al<sup>128</sup> investigated PDA treatment with NSAIDs and neurodevelopmental outcomes when 435 extremely preterm infants reached age 6.5 years. PDA surgery at up to 10 days of life was associated with a significantly increased risk of moderate-to-severe NDI and lower full-scale

intelligence quotient than surgery after 20 days. This trial suggested that initial drug treatment followed by deferred surgery appeared to be a safer option for extremely preterm infants with severe PDA.

**Peer-review:** Externally peer-reviewed.

**Author Contributions:** Concept – Ö.E.; Design – Ö.E., E.O.; Supervision – Y.S., R.S., H.S., G.T., R.I.C.; Resources – Ö.E., E.O., Y.S., R.S., M.Y.Ö., G.T., G.B., A.B., H.S., B.A., F.O., R.I.C.; Materials – Y.S., F.O., H.S., G.T., G.B.; Data Collection and/or Processing – Ö.E., E.O., B.A.; Analysis and/or Interpretation – Ö.E., E.O., Y.S., R.S., M.Y.Ö., G.T., G.B., A.B., H.S., B.A., F.O., R.I.C.; Literature Search – Ö.E., E.O., Y.S., R.S., M.Y.Ö., G.T., G.B., A.B., H.S., B.A., F.O., R.I.C.; Writing Manuscript – Ö.E., E.O., Y.S., R.S., M.Y.Ö., G.T., G.B., A.B., H.S., B.A., F.O., R.I.C.; Critical Review – Y.S., R.S., H.S., R.I.C.

**Acknowledgments:** The authors thank Int Dr. Ayşe Berra Okumuş for her contributions as the illustrator of the images used in this article.

**Conflict of Interest:** The authors have no conflict of interest to declare.

**Financial Disclosure:** The authors declared that this study has received no financial support.

## REFERENCES

- Atasay B, Erdeve Ö, Sallmon H, Singh Y [editorial]. Editorial: Management of patent ductus arteriosus in preterm infants. *Front Pediatr*. 2021;9:681393. [CrossRef]
- Okulu E, Erdeve O, Arslan Z, et al. An observational, prospective, multicenter, registry-based cohort study comparing conservative and medical management for patent ductus arteriosus. *Front Pediatr*. 2020;8:434. [CrossRef]
- Clyman RI, Liebowitz M, Kaempf J, et al. PDA-TOLERATE trial: an exploratory randomized controlled trial of treatment of moderate-to-large patent ductus arteriosus at 1 week of age. *J Pediatr*. 2019;205:41-48.e6. [CrossRef]
- Smith A, El-Khuffash A. Patent ductus arteriosus clinical trials: lessons learned and future directions. *Children (Basel, Switzerland)*. 2021;8(1):47. [CrossRef]
- Reese J. Towards a greater understanding of the ductus arteriosus. *Semin Perinatol*. 2018;42(4):199-202. [CrossRef]
- Ovalı F. Molecular and mechanical mechanisms regulating ductus arteriosus closure in preterm infants. *Front Pediatr*. 2020;8:516. [CrossRef]
- Nomura T, Lu R, Pucci ML, Schuster VL. The two-step model of prostaglandin signal termination: in vitro reconstitution with the prostaglandin transporter and prostaglandin 15 dehydrogenase. *Mol Pharmacol*. 2004;65(4):973-978. [CrossRef]
- Hung YC, Yeh JL, Hsu JH. Molecular mechanisms for regulating postnatal ductus arteriosus closure. *Int J Mol Sci*. 2018;19(7). [CrossRef]
- Hu Y, Jin H, Jiang Y, Du J. Prediction of therapeutic response to cyclooxygenase inhibitors in preterm infants with patent ductus arteriosus. *Pediatr Cardiol*. 2018;39(4):647-652. [CrossRef]
- Echtler K, Stark K, Lorenz M, et al. Platelets contribute to postnatal occlusion of the ductus arteriosus. *Nat Med*. 2010;16(1):75-82. [CrossRef]
- Hamrick SEG, Sallmon H, Rose AT, et al. Patent ductus arteriosus of the preterm infant. *Pediatrics*. 2020;146(5). [CrossRef]
- Sallmon H, Timme N, Atasay B, et al. Current controversy on platelets and patent ductus arteriosus closure in preterm infants. *Front Pediatr*. 2021;9:612242. [CrossRef]

13. Sallmon H, Weber SC, Hüning B, et al. Thrombocytopenia in the first 24 hours after birth and incidence of patent ductus arteriosus. *Pediatrics*. 2012;130(3):e623-e630. [CrossRef]
14. Kulkarni VV, Dutta S, Sundaram V, Saini SS. Preterm thrombocytopenia and delay of ductus arteriosus closure. *Pediatrics*. 2016;138(4). [CrossRef]
15. Sallmon H, Weber SC, Dirks J, et al. Association between platelet counts before and during pharmacological therapy for patent ductus arteriosus and treatment failure in preterm infants. *Front Pediatr*. 2018;6:41. [CrossRef]
16. Sallmon H, Metze B, Koehne P, et al. Mature and immature platelets during the first week after birth and incidence of patent ductus arteriosus. *Cardiol Young*. 2020;30(6):769-773. [CrossRef]
17. Alyamac Dizdar E, Ozdemir R, Sari FN, et al. Low platelet count is associated with ductus arteriosus patency in preterm newborns. *Early Hum Dev*. 2012;88(10):813-816. [CrossRef]
18. González-Luis G, Ghiradello S, Bas-Suárez P, et al. Platelet counts and patent ductus arteriosus in preterm infants: an updated systematic review and meta-analysis. *Front Pediatr*. 2020;8:613766. [CrossRef]
19. Mitra S, Chan AK, Paes BA, Thrombosis and Hemostasis in Newborns (THIN) Group. The association of platelets with failed patent ductus arteriosus closure after a primary course of indomethacin or ibuprofen: a systematic review and meta-analysis. *J Matern Fetal Neonatal Med. J Matern Fetal Neonatal Med*. 2017;30(2):127-133. [CrossRef]
20. Ding R, Zhang Q, Duan Y, Wang D, Sun Q, Shan R. The relationship between platelet indices and patent ductus arteriosus in preterm infants: a systematic review and meta-analysis. *Eur J Pediatr*. 2021;180(3):699-708. [CrossRef]
21. Sallmon H, Weber SC, von Gise A, Koehne P, Hansmann G. Ductal closure in neonates: a developmental perspective on platelet-endothelial interactions. *Blood Coagul Fibrinolysis*. 2011;22(3):242-244. [CrossRef]
22. Meinarde L, Hillman M, Rizzotti A, Basquiera AL, Tabares A, Cuestas E. C-reactive protein, platelets, and patent ductus arteriosus. *Platelets*. 2016;27(8):821-823. [CrossRef]
23. Kahvecioglu D, Erdeve O, Akduman H, et al. Influence of platelet count, platelet mass index, and platelet function on the spontaneous closure of ductus arteriosus in the prematurity. *Pediatr Neonatol*. 2018;59(1):53-57. [CrossRef]
24. Engür D, Kaynak-Türkmen M, Deveci M, Yenisey Ç. Platelets and platelet-derived growth factor in closure of the ductus arteriosus. *Turk J Pediatr*. 2015;57(3):242-247.
25. Kumar J, Dutta S, Sundaram V, Saini SS, Sharma RR, Varma N. Platelet transfusion for PDA closure in preterm infants: a randomized controlled trial. *Pediatrics*. 2019;143(5): e20182565. [CrossRef]
26. Hou HT, Xi-Zhang WJ, Wang J, et al. Altered plasma proteins released from platelets and endothelial cells are associated with human patent ductus arteriosus. *J Cell Physiol*. 2019;234(5):6842-6853. [CrossRef]
27. Kluckow M, Lemmers P. Hemodynamic assessment of the patent ductus arteriosus: Beyond ultrasound. *Semin Fetal Neonatal Med*. 2018;23(4):239-244. [CrossRef]
28. Elsayed YN, Fraser D. Patent ductus arteriosus in preterm infants, Part 1: Understanding the pathophysiologic link Between the patent ductus arteriosus and clinical complications. *Neonatal Netw*. 2017;36(5):265-272. [CrossRef]
29. Liu C, Zhu X, Li D, Shi Y. Related factors of patent ductus arteriosus in preterm infants: a systematic review and meta-analysis. *Front Pediatr*. 2020;8:605879. [CrossRef]
30. Liebowitz M, Kaempff J, Erdeve O, et al. Comparative effectiveness of drugs used to constrict the patent ductus arteriosus: a secondary analysis of the PDA-TOLERATE trial (NCT01958320). *J Perinatol*. 2019;39(5):599-607. [CrossRef]
31. Sankar MN, Bhombal S, Benitz WE. PDA: to treat or not to treat. *Congenit Heart Dis*. 2019;14(1):46-51. [CrossRef]
32. Singh Y, Fraisse A, Erdeve O, Atasay B. Echocardiographic diagnosis and hemodynamic evaluation of patent ductus arteriosus in extremely low gestational age newborn (ELGAN) infants. *Front Pediatr*. 2020;8:573627. [CrossRef]
33. van Laere D, van Overmeire B, Gupta S, et al. Application of NPE in the assessment of a patent ductus arteriosus. *Pediatr Res*. 2018;84(Suppl 1):46-56. [CrossRef]
34. Singh Y, Katheria A, Tissot C. Functional echocardiography in the Neonatal Intensive Care Unit. *Indian Pediatr*. 2018;55(5):417-424. [CrossRef]
35. McNamara PJ, Sehgal A. Towards rational management of the patent ductus arteriosus: the need for disease staging. *Arch Dis Child Fetal Neonatal Ed*. 2007;92(6):F424-F427. [CrossRef]
36. Tissot C, Singh Y. Neonatal functional echocardiography. *Curr Opin Pediatr*. 2020;32(2):235-244. [CrossRef]
37. Singh Y, Gupta S, Groves AM, et al. Expert consensus statement 'Neonatologist-performed Echocardiography (NoPE)-training and accreditation in UK. *Eur J Pediatr*. 2016;175(2):281-287. [CrossRef]
38. Mertens L, Seri I, Marek J, et al. Targeted neonatal echocardiography in the neonatal intensive care unit: practice guidelines and recommendations for training. *Eur J Echocardiogr*. 2011;12(10):715-736. [CrossRef]
39. de Boode WP, Singh Y, Gupta S, et al. Recommendations for neonatologist performed echocardiography in Europe: consensus Statement endorsed by European Society for Paediatric Research (ESPR) and European Society for Neonatology (ESN). *Pediatr Res*. 2016;80(4):465-471. [CrossRef]
40. Singh Y, Roehr CC, Tissot C, et al. Education, training, and accreditation of neonatologist performed echocardiography in Europe: framework for practice. *Pediatr Res*. 2018;84(Suppl 1):13-17. [CrossRef]
41. de Boode WP, Kluckow M, McNamara PJ, Gupta S. Role of neonatologist-performed echocardiography in the assessment and management of patent ductus arteriosus physiology in the newborn. *Semin Fetal Neonatal Med*. 2018;23(4):292-297. [CrossRef]
42. Groves AM, Singh Y, Dempsey E, et al. Introduction to neonatologist-performed echocardiography. *Pediatr Res*. 2018;84(Suppl 1):1-12. [CrossRef]
43. Cotton RB, Lindstrom DP, Stahlman MT. Early prediction of symptomatic patent ductus arteriosus from perinatal risk factors: a discriminant analysis model. *Acta Paediatr Scand*. 1981;70(5):723-727. [CrossRef]
44. Yeh TF, Raval D, Luken J, Thalji A, Lilien L, Pildes RS. Clinical evaluation of premature infants with patent ductus arteriosus: a scoring system with echocardiogram, acid-base, and blood gas correlations. *Crit Care Med*. 1981;9(9):655-657. [CrossRef]
45. Kindler A, Seipolt B, Heilmann A, Range U, Rüdiger M, Hofmann SR. Development of a diagnostic clinical score for hemodynamically significant patent ductus arteriosus. *Front Pediatr*. 2017;5:280. [CrossRef]
46. Gonen I, Babayigit A, Bornau H, et al. SIMPLE: A novel scoring system for predicting hemodynamically significant patent ductus arteriosus without echocardiographic evaluation in extremely low birth weight infants. *Front Pediatr*. 2021;9:649515. [CrossRef]
47. El-Khuffash A, James AT, Corcoran JD, et al. A patent ductus arteriosus severity score predicts chronic lung disease or death before discharge. *J Pediatr*. 2015;167(6):1354-1361.e2. [CrossRef]
48. Fink D, El-Khuffash A, McNamara PJ, Nitzan I, Hammerman C. Tale of two patent ductus arteriosus severity scores: similarities and differences. *Am J Perinatol*. 2018;35(1):55-58. [CrossRef]
49. Simon SR, van Zogchel L, Bas-Suárez MP, Cavallaro G, Clyman RI, Villamor E. Platelet counts and patent ductus arteriosus in preterm infants: a systematic review and meta-analysis. *Neonatology*. 2015;108(2):143-151. [CrossRef]

50. Demirel G, Yilmaz A, Vatansever B, Tastekin A. Is high platelet distribution width in the first hours of life can predict hemodynamically significant patent ductus arteriosus in preterm newborns? *J Matern Fetal Neonatal Med.* 2020;33(12):2049-2053.
51. Karabulut B, Arcagök BC, Simsek A. Utility of the platelet-to-lymphocyte ratio in diagnosing and predicting treatment success in preterm neonates with patent ductus arteriosus. *Fetal Pediatr Pathol.* 2021;40(2):103-112. [\[CrossRef\]](#)
52. Costello JM, Goodman DM, Green TP. A review of the natriuretic hormone system's diagnostic and therapeutic potential in critically ill children. *Pediatr Crit Care Med.* 2006;7(4):308-318. [\[CrossRef\]](#)
53. Khan SS, Sithisarn T, Bada HS, Vranicar M, Westgate PM, Hanna M. Urinary NT-proBNP levels and echocardiographic parameters for patent ductus arteriosus. *J Perinatol.* 2017;37(12):1319-1324. [\[CrossRef\]](#)
54. Celik IH, Erdeve O, Demirel G, Canpolat FE, Dilmen U. Elevated urinary NT-proBNP after pharmacological closure of patent ductus arteriosus in very low birth weight infants. *Early Hum Dev.* 2013;89(3):187-189. [\[CrossRef\]](#)
55. El-Khuffash AF, Molloy EJ. Influence of a patent ductus arteriosus on cardiac troponin T levels in preterm infants. *J Pediatr.* 2008;153(3):350-353. [\[CrossRef\]](#)
56. El-Khuffash AF, Slevin M, McNamara PJ, Molloy EJ. Troponin T, N-terminal pro natriuretic peptide and a patent ductus arteriosus scoring system predict death before discharge or neurodevelopmental outcome at 2 years in preterm infants. *Arch Dis Child Fetal Neonatal Ed.* 2011;96(2):F133-F137. [\[CrossRef\]](#)
57. Weisz DE, McNamara PJ, El-Khuffash A. Cardiac biomarkers and haemodynamically significant patent ductus arteriosus in preterm infants. *Early Hum Dev.* 2017;105:41-47. [\[CrossRef\]](#)
58. Smith A, El-Khuffash AF. Defining "haemodynamic significance" of the patent ductus arteriosus: do we have all the answers? *Neonatology.* 2020;117(2):225-232. [\[CrossRef\]](#)
59. Patra A, Thakkar PS, Makhoul M, Bada HS. Objective assessment of physiologic alterations associated With hemodynamically significant patent ductus arteriosus in extremely premature neonates. *Front Pediatr.* 2021;9:648584. [\[CrossRef\]](#)
60. Osman AA, Albalawi M, Dakshinamurti S, et al. The perfusion index histograms predict patent ductus arteriosus requiring treatment in preterm infants. *Eur J Pediatr.* 2021;180(6):1747-1754. [\[CrossRef\]](#)
61. Bell EF, Acarregui MJ. Restricted versus liberal water intake for preventing morbidity and mortality in preterm infants. *Cochrane Database Syst Rev.* 2008;1:CD000503. [\[CrossRef\]](#)
62. Bouissou A, Rakza T, Klosowski S, Tourneux P, Vanderborght M, Storme L. Hypotension in preterm infants with significant patent ductus arteriosus: effects of dopamine. *J Pediatr.* 2008;153(6):790-794. [\[CrossRef\]](#)
63. De Buyst J, Rakza T, Pennaforte T, Johansson AB, Storme L. Hemodynamic effects of fluid restriction in preterm infants with significant patent ductus arteriosus. *J Pediatr.* 2012;161(3):404-408. [\[CrossRef\]](#)
64. Seo ES, Sung SI, Ahn SY, Chang YS, Park WS. Changes in serum creatinine levels and natural evolution of acute kidney injury with conservative management of hemodynamically significant patent ductus arteriosus in extremely preterm infants at 23-26 weeks of gestation. *J Clin Med.* 2020;9(3):699. [\[CrossRef\]](#)
65. Thompson EJ, Greenberg RG, Kumar K, et al. Association between furosemide exposure and patent ductus arteriosus in hospitalized infants of very low birth weight. *J Pediatr.* 2018;199:231-236. [\[CrossRef\]](#)
66. Stewart A, Brion LP, Soll R. Diuretics for respiratory distress syndrome in preterm infants. *Cochrane Database Syst Rev.* 2011;2011(12):CD001454. [\[CrossRef\]](#)
67. Fajardo MF, Claire N, Swaminathan S, et al. Effect of positive end-expiratory pressure on ductal shunting and systemic blood flow in preterm infants with patent ductus arteriosus. *Neonatology.* 2014;105(1):9-13. [\[CrossRef\]](#)
68. Fowlie PW, Davis PG. Prophylactic indomethacin for preterm infants: a systematic review and meta-analysis. *Arch Dis Child Fetal Neonatal Ed.* 2003;88(6):F464-F466. [\[CrossRef\]](#)
69. Ment LR, Oh W, Ehrenkranz RA, et al. Low-dose indomethacin and prevention of intraventricular hemorrhage: a multicenter randomized trial. *Pediatrics.* 1994;93(4):543-550. [\[CrossRef\]](#)
70. Schmidt B, Davis P, Moddemann D, et al. Long-term effects of indomethacin prophylaxis in extremely-low-birth-weight infants. *N Engl J Med.* 2001;344(26):1966-1972. [\[CrossRef\]](#)
71. Bandstra ES, Montalvo BM, Goldberg RN, et al. Prophylactic indomethacin for prevention of intraventricular hemorrhage in premature infants. *Pediatrics.* 1988;82(4):533-542. [\[CrossRef\]](#)
72. Alfaleh K, Smyth JA, Roberts RS, et al. Prevention and 18-month outcomes of serious pulmonary hemorrhage in extremely low birth weight infants: results from the trial of indomethacin prophylaxis in preterms. *Pediatrics.* 2008;121(2):e233-e238. [\[CrossRef\]](#)
73. Kluckow M, Jeffery M, Gill A, Evans N. A randomised placebo-controlled trial of early treatment of the patent ductus arteriosus. *Arch Dis Child Fetal Neonatal Ed.* 2014;99(2):F99-F104. [\[CrossRef\]](#)
74. Rozé JC, Cambonie G, Le Thuaud A, et al. Effect of early targeted treatment of ductus arteriosus with ibuprofen on survival Without cerebral palsy at 2 years in infants with extreme prematurity: a randomized clinical trial. *J Pediatr.* 2021;233:33-42.e2. [\[CrossRef\]](#)
75. Koch J, Hensley G, Roy L, Brown S, Ramaciotti C, Rosenfeld CR. Prevalence of spontaneous closure of the ductus arteriosus in neonates at a birth weight of 1000 grams or less. *Pediatrics.* 2006;117(4):1113-1121. [\[CrossRef\]](#)
76. Sung SI, Lee MH, Ahn SY, Chang YS, Park WS. Effect of nonintervention vs oral ibuprofen in patent ductus arteriosus in preterm infants: a randomized clinical trial. *JAMA Pediatr.* 2020;174(8):755-763. [\[CrossRef\]](#)
77. El-Khuffash A, Bussmann N, Breatnach CR, et al. A pilot randomized controlled trial of early targeted patent ductus arteriosus treatment using a risk based severity score (the PDA RCT). *J Pediatr.* 2021;229:127-133. [\[CrossRef\]](#)
78. de Waal K, Phad N, Stubbs M, Chen Y, Kluckow M. A randomized placebo-controlled pilot trial of early targeted nonsteroidal anti-inflammatory drugs in preterm infants with a patent ductus arteriosus. *J Pediatr.* 2021;228:82-86.e2. [\[CrossRef\]](#)
79. Schena F, Francescato G, Cappelleri A, et al. Association between hemodynamically significant patent ductus arteriosus and bronchopulmonary dysplasia. *J Pediatr.* 2015;166(6):1488-1492. [\[CrossRef\]](#)
80. Sellmer A, Bjerre JV, Schmidt MR, et al. Morbidity and mortality in preterm neonates with patent ductus arteriosus on day 3. *Arch Dis Child Fetal Neonatal Ed.* 2013;98(6):F505-F510. [\[CrossRef\]](#)
81. Clyman RI, Hills NK, Liebowitz M, Johng S. Relationship between duration of infant exposure to a moderate-to-large patent ductus arteriosus shunt and the risk of developing bronchopulmonary dysplasia or death Before 36 weeks. *Am J Perinatol.* 2020;37(2):216-223. [\[CrossRef\]](#)
82. Mirza H, Garcia J, McKinley G, et al. Duration of significant patent ductus arteriosus and bronchopulmonary dysplasia in extremely preterm infants. *J Perinatol.* 2019;39(12):1648-1655. [\[CrossRef\]](#)
83. Clyman RI, Hills NK. The effect of prolonged tracheal intubation on the association between patent ductus arteriosus and bronchopulmonary dysplasia (grades 2 and 3). *J Perinatol.* 2020;40(9):1358-1365. [\[CrossRef\]](#)
84. Clyman RI, Hills NK, Cambonie G, et al. Patent ductus arteriosus, tracheal ventilation, and the risk of bronchopulmonary dysplasia. *Pediatr Res.* 2021. [\[CrossRef\]](#)
85. Clyman RI, Kaempf J, Liebowitz M, et al. Prolonged tracheal intubation and the association between patent ductus arteriosus and bronchopulmonary dysplasia: a secondary analysis of the PDA-TOLERATE trial. *J Pediatr.* 2021;229:283-288.e2. [\[CrossRef\]](#)
86. Sekar KC, Corff KE. Treatment of patent ductus arteriosus: indomethacin or ibuprofen? *J Perinatol.* 2008;28(1):S60-S62. [\[CrossRef\]](#)

87. Ohlsson A, Walia R, Shah SS. Ibuprofen for the treatment of patent ductus arteriosus in preterm or low birth weight (or both) infants. *Cochrane Database Syst Rev.* 2020;2(2):CD003481.
88. Patel J, Roberts I, Azzopardi D, Hamilton P, Edwards AD. Randomized double-blind controlled trial comparing the effects of ibuprofen with indomethacin on cerebral hemodynamics in preterm infants with patent ductus arteriosus. *Pediatr Res.* 2000;47(1):36-42. [CrossRef]
89. Yadav S, Agarwal S, Maria A, et al. Comparison of oral ibuprofen with oral indomethacin for PDA closure in Indian preterm neonates: a randomized controlled trial. *Pediatr Cardiol.* 2014;35(5):824-830. [CrossRef]
90. Terrin G, Conte F, Oncel MY, et al. Paracetamol for the treatment of patent ductus arteriosus in preterm neonates: a systematic review and meta-analysis. *Arch Dis Child Fetal Neonatal Ed.* 2016;101(2):F127-F136. [CrossRef]
91. Oncel MY, Yurttutan S, Erdeve O, et al. Oral paracetamol versus oral ibuprofen in the management of patent ductus arteriosus in preterm infants: a randomized controlled trial. *J Pediatr.* 2014;164(3):510-4.e1. [CrossRef]
92. Dani C, Lista G, Bianchi S, et al. Intravenous paracetamol in comparison with ibuprofen for the treatment of patent ductus arteriosus in preterm infants: a randomized controlled trial. *Eur J Pediatr.* 2021;180(3):807-816. [CrossRef]
93. Ghanem S, Mostafa M, Shafee M. Effect of oral ibuprofen on patent ductus arteriosus in premature newborns. *J Saudi Heart Assoc.* 2010;22(1):7-12. [CrossRef]
94. Sangtawesin C, Sangtawesin V, Lertsutthiwong W, Kanjanapattanakul W, Khorana M, Ayudhaya JKN. Prophylaxis of symptomatic patent ductus arteriosus with oral ibuprofen in very low birth weight infants. *J Med Assoc Thai.* 2008;91(suppl 3):S28-S34.
95. Mitra S, Florez ID, Tamayo ME, et al. Association of Placebo, Indomethacin, Ibuprofen, and acetaminophen with closure of hemodynamically significant patent ductus arteriosus in preterm infants: a systematic review and meta-analysis. *JAMA.* 2018;319(12):1221-1238. [CrossRef]
96. Gersony WM, Peckham GJ, Ellison RC, Miettinen OS, Nadas AS. Effects of indomethacin in premature infants with patent ductus arteriosus: results of a national collaborative study. *J Pediatr.* 1983;102(6):895-906. [CrossRef]
97. Van Overmeire B, Van de Broek H, Van Laer P, Weyler J, Vanhaesebrouck P. Early versus late indomethacin treatment for patent ductus arteriosus in premature infants with respiratory distress syndrome. *J Pediatr.* 2001;138(2):205-211. [CrossRef]
98. Dash SK, Kabra NS, Avasthi BS, Sharma SR, Padhi P, Ahmed J. Enteral paracetamol or intravenous indomethacin for closure of patent ductus arteriosus in preterm neonates: a randomized controlled trial. *Indian Pediatr.* 2015;52(7):573-578. [CrossRef]
99. Oncel MY, Erdeve O. Safety of therapeutics used in management of patent ductus arteriosus in preterm infants. *Curr Drug Saf.* 2015;10(2):106-112. [CrossRef]
100. Oncel MY, Erdeve O. Oral medications regarding their safety and efficacy in the management of patent ductus arteriosus. *World J Clin Pediatr.* 2016;5(1):75-81. [CrossRef]
101. Yurttutan S, Bozkaya A, Hüdayioğlu F, Oncel MY. The effect of combined therapy for treatment of monotherapy-resistant PDA in preterm infants. *J Matern Fetal Neonatal Med. J Matern Fetal Neonatal Med.* 2019;32(21):3662-3665. [CrossRef]
102. Fraisse A, Bautista-Rodríguez C, Burmester M, Lane M, Singh Y. Transcatheter closure of patent ductus arteriosus in infants with weight Under 1,500 grams. *Front Pediatr.* 2020;8:558256. [CrossRef]
103. Sathanandam S, Balduf K, Chilakala S, et al. Role of transcatheter patent ductus arteriosus closure in extremely low birth weight infants. *Catheter Cardiovasc Interv.* 2019;93(1):89-96. [CrossRef]
104. Francis E, Singhi AK, Lakshmvikenkateshaiah S, Kumar RK. Transcatheter occlusion of patent ductus arteriosus in pre-term infants. *JACC Cardiovasc Interv.* 2010;3(5):550-555. [CrossRef]
105. Bentham J, Meur S, Hudsmith L, Archer N, Wilson N. Echocardiographically guided catheter closure of arterial ducts in small preterm infants on the neonatal intensive care unit. *Catheter Cardiovasc Interv.* 2011;77(3):409-415. [CrossRef]
106. Zahn EM, Nevin P, Simmons C, Garg R. A novel technique for transcatheter patent ductus arteriosus closure in extremely preterm infants using commercially available technology. *Catheter Cardiovasc Interv.* 2015;85(2):240-248. [CrossRef]
107. Rodríguez Ogando A, Planelles Asensio I, de la Blanca ARS, et al. Surgical ligation versus percutaneous closure of patent ductus arteriosus in very low-weight preterm infants: which are the real benefits of the percutaneous approach? *Pediatr Cardiol.* 2018;39(2):398-410. [CrossRef]
108. AMPLATZER duct occluder II additional sizes (ADO II AS). NCT03055858 @clinicaltrials.gov. Available at: <https://clinicaltrials.gov/ct2/show/NCT03055858>
109. Philip R, Waller BR 3rd, Agrawal V, et al. Morphologic characterization of the patent ductus arteriosus in the premature infant and the choice of transcatheter occlusion device. *Catheter Cardiovasc Interv.* 2016;87(2):310-317. [CrossRef]
110. Frid I, Ågren J, Kjellberg M, Normann E, Sindelar R. Critically ill neonates displayed stable vital parameters and reduced metabolic acidosis during neonatal emergency airborne transport in Sweden. *Acta Paediatr.* 2018;107(8):1357-1361. [CrossRef]
111. Meberg A, Hansen TWR. Quality evaluation of neonatal transports. *Tidsskr Nor Lægeforen.* 2005;125(18):2474-2476.
112. Beckmann U, Gillies DM, Berenholtz SM, Wu AW, Pronovost P. Incidents relating to the intra-hospital transfer of critically ill patients. An analysis of the reports submitted to the Australian Incident Monitoring Study in intensive care. *Intensive Care Med.* 2004;30(8):1579-1585. [CrossRef]
113. Karlsson V, Sporre B, Ågren J. Transcutaneous PCO<sub>2</sub> monitoring in newborn infants during general anesthesia is technically feasible. *Anesth Analg.* 2016;123(4):1004-1007. [CrossRef]
114. McKee M. Operating on critically ill neonates: the OR or the NICU. *Semin Perinatol.* 2004;28(3):234-239. [CrossRef]
115. Finer NN, Woo BC, Hayashi A, Hayes B. Neonatal surgery: intensive care unit versus operating room. *J Pediatr Surg.* 1993;28(5):645-649. [CrossRef]
116. Hall NJ, Stanton MP, Kitteringham LJ, et al. Scope and feasibility of operating on the neonatal intensive care unit: 312 cases in 10 years. *Pediatr Surg Int.* 2012;28(10):1001-1005. [CrossRef]
117. Kumar Sinha S, Neogi S. Bedside neonatal intensive care unit surgery- myth or reality! *J Neonatal Surg.* 2013;2(2):20. [CrossRef]
118. Eggert LD, Jung AJ, MCGough EC, Ruttenberg HD. MCGough EC, Ruttenberg HD. Surgical treatment of patent ductus arteriosus in preterm infants. Four-year experience with ligation in the newborn intensive care unit. *Pediatr Cardiol.* 1982;2(1):15-18. [CrossRef]
119. Gould DS, Montenegro LM, Gaynor JW, et al. A comparison of on-site and off-site patent ductus arteriosus ligation in premature infants. *Pediatrics.* 2003;112(6 Pt 1):1298-1301. [CrossRef]
120. Ko YC, Chang CI, Chiu IS, Chen YS, Huang SC, Hsieh WS. Surgical ligation of patent ductus arteriosus in very-low-birth-weight premature infants in the neonatal intensive care unit. *J Formos Med Assoc.* 2009;108(1):69-71. [CrossRef]
121. Metin K, Maltepe F, Kir M, et al. Ligation of patent ductus arteriosus in low birth weight premature infants: timing for intervention and effectiveness of bed-side surgery. *J Cardiothorac Surg.* 2012;7:129. [CrossRef]
122. Avsar MK, Demir T, Celiksular C, Zeybek C. Bedside PDA ligation in premature infants less than 28 weeks and 1000 grams. *J Cardiothorac Surg.* 2016;11(1):146. [CrossRef]

123. Akyuz M, Isik O, Mercan I, Cakmak M. Bedside surgical ligation of the patent ductus arteriosus in very-low-birth-weight premature infants: limited upper ministernotomy as an alternative approach. *J Card Surg.* 2021;36(2):436-441. [\[CrossRef\]](#)
124. Lee LK, Woodfin MY, Vadi MG, et al. A comparison of postoperative outcomes with PDA ligation in the OR versus the NICU: a retrospective cohort study on the risks of transport. *BMC Anesthesiol.* 2018;18(1):199. [\[CrossRef\]](#)
125. Martini S, Galletti S, Kelsall W, et al. Ductal ligation timing and neonatal outcomes: a 12-year bicentric comparison. *Eur J Pediatr.* 2021;180(7):2261-2270. [\[CrossRef\]](#)
126. Olsson KW, Jonzon A, Sindelar R. Early haemodynamically significant patent ductus arteriosus does not predict future persistence in extremely preterm infants. *Acta Paediatr.* 2019;108(9):1590-1596. [\[CrossRef\]](#)
127. Olsson KW, Youssef S, Kjellberg M, Raaijmakers R, Sindelar R. A matched case control study of surgically and non-surgically treated patent ductus arteriosus in extremely pre-term infants. *Front Pediatr.* 2021;9:648372. [\[CrossRef\]](#)
128. Gudmundsdottir A, Broström L, Skiöld B, et al. The type and timing of patent ductus arteriosus treatment was associated with neurodevelopment when extremely preterm infants reached 6.5 years. *Acta Paediatr.* 2021;110(2):510-520. [\[CrossRef\]](#)
129. Pavlek LR, Slaughter JL, Berman DP, Backes CH. Catheter-based closure of the patent ductus arteriosus in lower weight infants. *Semin Perinatol.* 2018;42(4):262-268. [\[CrossRef\]](#)
130. Wang JN, Lin YC, Hsieh ML, Wei YJ, Ju YT, Wu JM. Transcatheter closure of patent ductus arteriosus in premature infants with very low birth weight. *Front Pediatr.* 2020;8:615919. [\[CrossRef\]](#)
131. Bancalari E. Patent ductus arteriosus and short- and long-term respiratory outcomes. *Am J Perinatol.* 2016;33(11):1055-1057. [\[CrossRef\]](#)
132. Herget J, Hampl V, Povýsilová V, Slavík Z. Long-term effects of prenatal indomethacin administration on the pulmonary circulation in rats. *Eur Respir J.* 1995;8(2):209-215. [\[CrossRef\]](#)
133. Broccard AF, Hotchkiss JR, Kuwayama N, et al. Consequences of vascular flow on lung injury induced by mechanical ventilation. *Am J Respir Crit Care Med.* 1998;157(6 Pt 1):1935-1942. [\[CrossRef\]](#)
134. Twilhaar ES, Wade RM, de Kieviet JF, van Goudoever JB, van Elburg RM, Oosterlaan J. Cognitive outcomes of children born extremely or very preterm Since the 1990s and associated risk factors: a meta-analysis and meta-regression. *JAMA Pediatr.* 2018;172(4):361-367. [\[CrossRef\]](#)
135. Ohlsson A, Shah PS. Paracetamol (acetaminophen) for patent ductus arteriosus in preterm or low birth weight infants. *Cochrane Database Syst Rev.* 2020;1(1):CD010061.
136. Ohlsson A, Shah SS. Ibuprofen for the prevention of patent ductus arteriosus in preterm and/or low birth weight infants. *Cochrane Database Syst Rev.* 2020;1(1):CD004213.
137. Cassady G, Crouse DT, Kirklin JW, et al. A randomized, controlled trial of very early prophylactic ligation of the ductus arteriosus in babies who weighed 1000 g or less at birth. *N Engl J Med.* 1989;320(23):1511-1516. [\[CrossRef\]](#)
138. Jhaveri N, Moon-Grady A, Clyman RI. Early surgical ligation versus a conservative approach for management of patent ductus arteriosus that fails to close after indomethacin treatment. *J Pediatr.* 2010;157(3):381-387.e1. [\[CrossRef\]](#)
139. Wickremasinghe AC, Rogers EE, Piecuch RE, et al. Neurodevelopmental outcomes following two different treatment approaches (early ligation and selective ligation) for patent ductus arteriosus. *J Pediatr.* 2012;161(6):1065-1072. [\[CrossRef\]](#)
140. Rheinlaender C, Helfenstein D, Pees C, et al. Neurodevelopmental outcome after COX inhibitor treatment for patent ductus arteriosus. *Early Hum Dev.* 2010;86(2):87-92. [\[CrossRef\]](#)
141. Eras Z, Gokmen T, Erdeve O, Ozyurt BM, Saridas B, Dilmen U. Impact of oral versus intravenous ibuprofen on neurodevelopmental outcome: a randomized controlled parallel study. *Am J Perinatol.* 2013;30(10):857-862. [\[CrossRef\]](#)
142. Onel MY, Eras Z, Uras N, Canpolat FE, Erdeve O, Oguz SS. Neurodevelopmental outcomes of preterm infants treated with oral paracetamol versus ibuprofen for patent ductus arteriosus. *Am J Perinatol.* 2017;34(12):1185-1189. [\[CrossRef\]](#)
143. Juujärvi S, Saarela T, Hallman M, Aikio O. Trial of paracetamol for premature newborns: five-year follow-up. *J Matern Fetal Neonatal Med.* January 2021. *J Matern Fetal Neonatal Med.* 2021:1-3. [\[CrossRef\]](#)