

Early Marjolin's Ulcer after Minimal Superficial Burn

Dear Editor,

Marjolin's ulcer is a rare, well-defined, uncommon, and often aggressive malignant transformation,¹ secondary to burn injuries and other inflammatory changes such as venous insufficiency ulcers, pressure ulcers, traumatic wounds, cystostomy sites, scarring from lupus, amputation stumps, chronic lymphedema, chronic pilonidal sinuses, hidradenitis suppurativa, chronic ulcers of leprosy, necrobiosis lipoidica, and chronic osteomyelitic fistulae.²

The incidence of burn scars undergoing malignant transformation has been reported to be 0.77 to 2%.³ The incidence of Marjolin's ulcer in lower extremities is more frequent than that in upper extremities. Marjolin's ulcer occurs at any age and in all races, and men are more commonly affected than women (3:1).⁴ Over 90% of all Marjolin's ulcers degenerate into malignancies of epidermoid organs such as squamous cell carcinoma, basal cell carcinoma, and malignant melanomas. Sarcomas can occur but they are uncommon.³ The usual histological finding is squamous cell carcinoma,⁵ and it is thought that basal cell carcinoma occurs when the burn is more superficial and the hair follicles and sebaceous glands are spared.¹ Basal cell carcinoma is generally deemed a very aggressive tumor with higher rates of regional metastasis.

The usual presentation of Marjolin's ulcer is a non-healing ulcer arising after traumatized or chronically inflamed skin.⁵

The exact causes of this malignant transformation are unknown,^{4,6} with various etiological factors having been implicated such as

- 1 Genetic factors like mutation of the FAS- APO-YCD,
- 2 Low T cell counts,
- 3 Lymphatic obliteration and poor lymphatic regeneration,
- 4 Toxins released from damaged tissues,
- 5 Decreased vascularity of the scar, and
- 6 Miscellaneous factors such as irritation, antibodies, DNA mutations, local toxins, and infection.

Marjolin's ulcer is classified into acute and chronic subgroups. Acute scar carcinoma, which is rarely seen, occurs sooner than one year after injury.⁷ Acute Marjolin's ulcer is more often basal cell carcinoma and is associated with more superficial burn scars.⁵ The latency period is inversely proportional to the patient's age at the time of burn injury.¹ The mean average period of chronic carcinoma development, more frequent type, is 35.5 years.⁷

We herein present an otherwise healthy 54-year-old Jewish man, who developed Marjolin's ulcer only 6 weeks after his burn injury. The patient had superficial scald burn injuries, about 3% of the body surface area, on his right foot and right hand, which healed with conservative management after 3 weeks. Two weeks later, a 10-mm exophytic fragile nodule, which bled with minor manipulation, was noted in the dorsal aspect of his right hand. The nodule was excised completely, the wound was closed primarily, and the tissue was sent for histopathologic evaluations. The histopathology of the lesion was well-differentiated squamous cell carcinoma (figures 1 and 2). Consequently, re-excision with a 10-mm margin was done, and full-thickness skin graft was

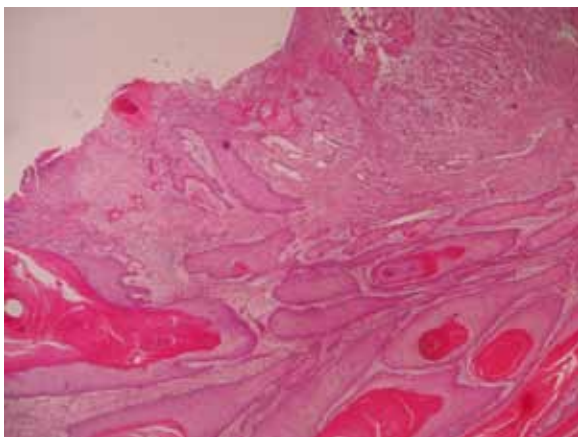


Figure 1: Ulceration with invasion of malignant keratinizing squamous cells through the dermis (H&E ×100).

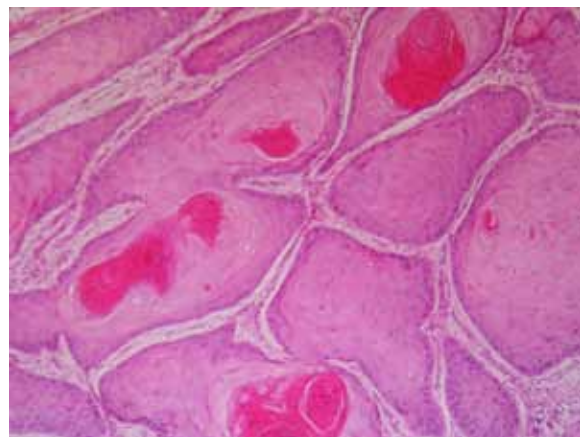


Figure 2: Nests of well-differentiated squamous cells, producing keratin pearls (H&E ×100).

performed. The confirmation of complete excision was done by the pathologist. Now 2 years on since the excision, the patient is systemically well, with no evidence of local recurrence.

Marjolin's ulcer is a potentially aggressive malignant tumor, which has a typically long latency period. Although acute Marjolin's ulcer (latent period less than one year) is very uncommon, we believe that the appearance of any nodules or ulceration on a healed burn area at any age or site and with any latent period should be excised and evaluated histologically.

Conflict of Interest: None declared.

Please cite this article as: Mohammadi AA, Seyed Jafari SM, Hosseinzadeh M. Early Marjolin's Ulcer after Minimal Superficial Burn. *Iran J Med Sci.* 2013;38(1): 69-70.

Ali Akbar Mohammadi¹, MD; Seyed Morteza Seyed Jafari¹, MD; Masoud Hosseinzadeh², MD

¹Shiraz Burn Research Center, Division of Plastic and Reconstructive Surgery, Department of Surgery, Ghotbedin Burn Hospital, Shiraz University of Medical Sciences, Shiraz, Iran;

²Department of Pathology, School of Medicine, Shiraz University of Medical Sciences, Shiraz, Iran

Correspondence:

Ali Akbar Mohammadi, MD;

Shiraz Burn Research Center, Ghotbedin Burn Hospital, Fakhrrabad street, Shiraz, Iran

Tel: +98 711 8219640-2

Fax: +98 711 8217090

Email: mohamadiaa@sums.ac.ir

Received: 5 September 2012

Revised: 20 October 2012

Accepted: 21 October 2012

References

- 1 Copcu E, Aktas A, Sişman N, Oztan Y. Thirty-one cases of Marjolin's ulcer. *Clin Exp Dermatol.* 2003;28:138-41. doi: 10.1046/j.1365-2230.2003.01210.x. PubMed PMID: 12653697.
- 2 Shahla A. An overview of heel Marjolin's ulcers in the Orthopedic Department of Urmia University of Medical Sciences. *Arch Iran Med.* 2009;12:405-8. PubMed PMID: 19566359.
- 3 Fleming MD, Hunt JL, Purdue GF, Sandstad J. Marjolin's ulcer: a review and reevaluation of a difficult problem. *J Burn Care Rehabil.* 1990;11:460-9. PubMed PMID: 2246317.
- 4 Er-Fan X, Li AO, Shi-ling W, Shao-Yu K, Guang-Xiu C. Burn scar carcinoma: Case reports and review of the literature. *Annals of the MBC.* 1992;5:2.
- 5 Love RL, Bredahl AF. Acute squamous cell carcinoma arising within a recent burn scar in a 14-year-old boy. *Plast Reconstr Surg.* 2000;106:1069-71. doi: 10.1097/00006534-200010000-00017. PubMed PMID: 11039378.
- 6 Thio D, Clarkson JH, Misra A, Srivastava S. Malignant change after 18 months in a lower limb ulcer: acute Marjolin's revisited. *Br J Plast Surg.* 2003;56:825-8. doi: 10.1016/j.bjps.2003.08.016. PubMed PMID: 14615262.
- 7 Guenther N, Menenakos C, Braumann C, Buettemeyer R. Squamous cell carcinoma arising on a skin graft 64 years after primary injury. *Dermatol Online J.* 2007;13:27. PubMed PMID: 17498446.