

# EXPERIMENTAL HYPERTHYROIDISM AND ITS EFFECT UPON THE MYOCARDIUM IN GUINEA PIGS AND RABBITS

BY GEOFFREY RAKE, M.B., B.S., AND DONALD McEACHERN,\* M.D.

*(From the Department of Pathology and the Cardiographic Laboratory of the Johns Hopkins Hospital and University, Baltimore)*

(Received for publication, March 11, 1931)

## PLATE 1

It has been known for some years that the administration of preparations of the thyroid gland gives rise to an hypertrophy of several organs including the heart. Iscovesco (1, 2), using rabbits, produced these changes by daily injections of a "lipoid" extract. Hoskins (3), Herring (4), Hewitt (5), and others fed rats daily on various preparations of the gland and noted that, even when the doses used were "non-toxic" (*i.e.*, failed to produce evidences of hyperthyroidism), cardiac hypertrophy resulted. Cameron and Carmichael (6) studied rats and rabbits with similar results; Simonds and Brandes (7) fed dogs large quantities of dried thyroid (10 gm. and more) daily, so that definite hyperthyroidism was produced, and found considerable increase in the size and weight of the hearts. Observers agree that hypertrophy so produced involves all chambers of the heart with a slightly greater proportional increase in size of the left ventricle; it tends to disappear when the thyroid preparation is discontinued.

The histological changes in the heart resulting from induced hyperthyroidism have not been studied so thoroughly and the results are conflicting. Farrant (8) examined the hearts from cats and rabbits that had been fed various thyroid preparations and described wasting of the muscle fibres or an hyaline appearance of individual fibres; there was no cell infiltration. On the whole, his meagre histological account fails to show convincingly that any pathological changes were produced. Cameron and Carmichael found no histological changes in the hearts of their rats. Hashimoto (9) made an extensive study of the changes in rats' hearts. Thirty-eight animals were fed on large doses of thyroid (0.1 to 0.5 gm. daily). Of these, ten died and the rest were killed with chloroform (see Goodpasture below). 90 per cent of those fed 0.5 gm. daily and 50 per cent of those fed 0.3 daily showed diffuse myocardial changes characterized by swelling and separation of the fibres, and dense patches of small round cells, monocytes, and a few fibroblasts. These lesions appeared for the most part close to blood vessels and

\* Jacques Loeb Fellow in Medicine.

under the pericardium; they were said to resemble Aschoff bodies. Four of eleven animals given 0.03 gm. every other day showed similar lesions. Nothing comparable was found in any one of the thirty-six control animals. Hashimoto believed that he had produced in his rats lesions similar to those described by Fahr (10) in hyperthyroidism in man.

In the same year, and entirely independently, Goodpasture (11) published the results of a similar study on rabbits. Seven animals were fed dried thyroid gland (1 gm. daily for 15 to 26 days), and a like number were injected intravenously with thyroxine (1 mg. every 2nd or 3rd day for 9 to 23 days). The animals were killed by a blow on the head. The auricles showed no changes. Small "definite but insignificant" changes were found in the ventricles, consisting in perivascular fibrosis and slight destruction of fibres about the small vessels in the wall of the right ventricle, with fibrosis in the wall of the left ventricle and papillary muscles. One animal, which died as a result of the hyperthyroid state, showed small fresh necroses. Fifteen animals treated in the same manner were, in addition, subjected to chloroform inhalation for 1 hour and killed 24 to 72 hours later. Twelve of these animals showed areas of necrosis in the left ventricle, mononuclear infiltration, and later the appearance of fibroblasts. Goodpasture concluded that large doses of thyroid products produced the symptoms of hyperthyroidism, but caused only insignificant histological changes in the heart. On the other hand, he believed that these products rendered the myocardium more susceptible to injury, since chloroform inhalation, which in ten control animals had failed to produce any myocardial lesions, produced necroses in the hyperthyroid animals.

Takane (12) fed thyreiodin to rats, guinea pigs, and rabbits. He found that when large quantities were avoided (*i.e.*, 0.08 gm., which caused too rapid death), an acute myocarditis was produced with changes in the muscle fibres, and a diffuse or localized infiltration of cells in the wall of the left ventricle. The changes appeared about the 7th day. Sodium and potassium iodides produced similar changes. From the figures of von Furth (13) and Riesenfeld (14), Takane assumed that the heart contained more lactic acid than any other organ, and that this substance liberated free iodine which produced the myocarditis. This explanation is often accepted and frequently quoted, but the figures themselves are open to question. Von Furth's estimations were made on tissues 48 hours post mortem, Riesenfeld's following sudden death in one individual. Subsequent work on animals, with more rapid and careful technique, has shown that the lactic acid values of resting mammalian skeletal muscle are more than double those of the myocardium (15, 16).

The lack of uniformity in the microscopical findings of induced hyperthyroidism is striking. Hence we have undertaken to determine what these are. Cameron and Carmichael found no changes. Those described by Farrant and Goodpasture are insignificant, while those of Hashimoto and Takane are apparently well marked and extensive.

Hashimoto's use of chloroform to kill twenty-eight of his thirty-eight rats suggests, upon first thought, that he may have accidentally reproduced Goodpasture's experiments. Since however, considerable time would be required for the appearance of the small round cells, monocytes, and fibroblasts found in the lesions such an inference seems improbable.

### *Material*

In the present work both rabbits and guinea pigs were used. The weight, temperature, and heart rate of each animal was recorded every other day during the experiment. The injections of thyroxine were made intramuscularly on alternate days; the quantities varied slightly. Guinea pigs received thyroxine in doses of 0.10 to 0.17 mg. per day over 4 to 83 days. Rabbits received doses of 0.10 to 0.35 mg. per day over 2 to 13 days. Thyroxine ("Roche") was used throughout. The degree of hyperthyroidism produced was judged by the loss of weight, the increase in heart and respiratory rate, diarrhea, apprehensiveness, and, in more extreme instances, by the great muscular weakness. It was observed that the animals showed great individual variation in susceptibility to thyroxine. Evidences of hyperthyroidism appeared as a rule within 36 to 48 hours after the first injection, and progressed with succeeding doses. Of the animals which died, all were discarded except those that were still warm when found. The majority of animals were killed by a sharp blow on the head. The tissues were fixed almost immediately in either Zenker-formol solution or in formalin. Sections were made from both auricles and ventricles and in practically every instance from the lungs and adrenals also.

In the case of both rabbits and guinea pigs, a series of control (normal) hearts were examined, in order to ascertain the variety and extent of changes present in normal animals.

### *The Findings in Guinea Pigs*

The hearts from twenty normal guinea pigs were carefully studied. These animals were taken from stock, weight and temperature were recorded on alternate days over periods of time corresponding to the experiment, and if any animal showed signs of ill health it was discarded.

In the majority of control hearts, there were vacuolated muscle fibres which were more plentiful beneath the epicardium and endocardium. Beneath the endocardium, especially close to the point of attachment of the valve cusps, cells were abundant, either scattered or in small groups. These cells were for the most part monocytes or lymphocytes, but there were also occasional pseudo-eosinophil leucocytes. Less conspicuous were small groups of monocytes and lym-

phocytes close under the pericardium and in association with the smaller branches of the coronary arteries. Finally, occasional collections of similar cells were seen between the muscle fibres. The fibres themselves showed no changes apart from the vacuoles already mentioned. There was no necrosis nor any scarring.

Complete autopsies were performed on seventeen guinea pigs, which had received thyroxine. Eight of these showed evidence, either macroscopic or microscopic or both, of spontaneous pneumonia apparently with *B. bronchisepticus*; the other nine showed no infection. For reasons which will shortly be obvious, these two groups will be discussed separately.

In the nine uninfected animals no myocardial changes whatever were found save in No. 17. In one place in the wall of the left ventricle of this animal there was found a small area of dead muscle fibres surrounded by a large number of lymphocytes; there was no other abnormality. These nine animals received injections of thyroxine varying from 0.07 to 0.17 mg. daily over periods up to 10½ weeks, and in six of them very severe hyperthyroidism was produced. Singularly enough, the one animal to show a lesion was the one with the least evidence of hyperthyroidism. It was noted in both guinea pigs and rabbits that the hearts of hyperthyroid animals were considerably larger than the normal. This appeared to be due largely to dilatation, though doubtless some hypertrophy was present also. The heart invariably stopped in diastole, leaving the chambers dilated and the auricles filled with dark blood.

Rigor mortis of the skeletal muscles occurred much sooner after death in the hyperthyroid than in the normal animals, though neither were allowed to struggle. Hashimoto (9) noted this phenomenon in the cardiac muscle of his animals.

Of the eight infected guinea pigs (*bronchisepticus*), five showed definite myocardial damage. The changes were variable. In places there were small masses of necrotic, granular, and pink staining tissue surrounded by monocytes and pseudo-eosinophil leucocytes (Fig. 1). In other places a few cells were collected around one or two dead and granular muscle fibres. At a later stage, there were seen occasionally areas of vacuolated and shrunken fibres with collapsed stroma, a few lymphocytes, and some fibroblasts. Another lesion was char-

acterized by the accumulation of large clear elongated cells, with clear nuclei, which surrounded degenerated muscle fibres, often in association with small vessels. On more detailed examination these cells showed a very close resemblance to the cells of the sarcolemma, and it is believed that they represented a proliferation of those cells, perhaps in an attempt at repair. An extreme example of such accumulation of large clear cells is seen in Fig. 2. Finally, in two cases there was extreme vacuolation of the muscle fibres so that they appeared to be "blown out" (Fig. 1). These vacuoles did not stain with fat stains.

It seems certain that these lesions are not due to the hyperthyroidism alone, but it is conceivable that, as in Goodpasture's chloroform experiment, the hyperthyroidism may have had an adjuvant action. From the meagre literature on spontaneous *bronchisepticus* infection it is difficult to ascertain what damage this disease can produce in the myocardium. The most definite statement on the subject is in the paper by Strada and Traina (17), describing an epidemic of pneumonia in guinea pigs, caused by an organism which subsequent investigators (18) have recognized as *B. bronchisepticus*. They say that the organ next most affected after the lung itself is the heart, which often shows well marked areas of "degeneration."\*

#### *The Findings in Rabbits*

Forty-three control "normal" rabbits were taken from stock and killed after a period of observation similar to that of the guinea pigs. In each case a complete autopsy was performed and the myocardium examined with especial care. As in the guinea pigs, the majority of normal hearts showed vacuolated muscle fibres. Occasionally this change was extensive and well marked. Groups of lymphocytes and monocytes were present close to the small vessels and between the muscle fibres. Most striking were the occasional areas of fibrocytes and lymphocytes associated with vacuolated and collapsed muscle fibres (Fig. 3). In other cases there were less conspicuous areas in which

\* Oskar Seifried (in Jaffé's recently published Anatomy and pathology of spontaneous diseases of small laboratory animals, Berlin, 1931, 584) says of pleuropneumonia due to *B. bronchisepticus*, "moreover degeneration of the myocardium, congestion, and cloudy swelling of the parenchyma are often demonstrable."

a few lymphocytes were accumulated around disintegrating fibres and collapsed stroma. Areas of scarring were sometimes found, most frequently in the base of the papillary muscles, and in one case there was a collection of large clear cells, resembling those of the sarcolemma, close to a small vessel. In all, six out of the forty-three normal controls showed the definite abnormalities described—focal destruction of muscle fibres and cell infiltration.

Forty-four rabbits, which received intramuscular injections of varying amounts of thyroxine every other day, were killed and complete autopsies performed. Of these forty-four rabbits, fifteen showed lesions in the myocardium. Some of these lesions were obviously fresh; small groups of necrotic and disintegrating fibres were surrounded by lymphocytes, monocytes, or more rarely pseudo-eosinophils (Fig. 4). At a later stage there were areas from which the fibres had largely disappeared, the stroma had collapsed, and fibroblasts were present. Finally there were distinct and dense scars. Apart from this type of lesion, three of the cases showed greatly vacuolated or blown out muscle fibres similar to those noted in the guinea pigs, and, in two cases, areas of what were apparently proliferated sarcolemma cells were seen. On the whole the lesions in the myocardium of these rabbits differed only in degree, and that slightly, from those seen in the control series.

#### DISCUSSION

In the case both of guinea pigs and rabbits the administration of thyroxine alone has produced, at most, only insignificant morphological changes in the myocardium. In the series of uninfected guinea pigs, only one out of nine showed a myocardial lesion, and it is possible that this animal, No. 17, may in reality have had an early infection in one lung which the single routine section failed to show. The relation of this single lesion to the hyperthyroidism seems improbable, since, as has already been pointed out, this guinea pig showed the least evidence of hyperthyroidism of any animal in the series. It is obvious that the frequent occurrence of myocardial lesions in the animals with pulmonary infection is of considerable importance in the interpretation of results. Inasmuch as previous investigators have not dealt, specifically, with this point, it is difficult to evaluate the

significance of the myocardial changes which they have described. In the present study, animals placed in the control group and given no thyroxine were discarded if infections occurred. It is not known therefore whether cardiac lesions, similar to those described above, occur as a result of infections in the absence of hyperthyroidism.

The lesions produced in the rabbits were different only in degree, and not in quality, from those seen in the controls. This latter point is interesting, and indeed may serve as a clue towards the solution of the problem. As has been pointed out elsewhere (19), the lesions in the myocardium of human cases of hyperthyroidism differ in degree only from the changes found in a control group of "normal"\* hearts of the same age period. It would seem probable, on the basis of this evidence, together with that presented in the present paper, that the hyperthyroidism itself produces no specific lesion. It is conceivable that damage produced, on the one hand, by the wear and tear and on the other, by any associated infection or other disease, tends to be more accentuated in the individual with hyperthyroidism than in the normal individual. This point is however far from settled.

It is certain that in the past too much emphasis has been laid upon the morphological changes in the myocardium, with a consequent neglect of important alterations in the metabolism and function of the cardiac muscle. It would seem probable that physiological studies may bring us to a better understanding of the cardiac abnormalities in hyperthyroidism.

#### SUMMARY

A study has been made of the pathological changes in the hearts and other tissues of animals rendered hyperthyroid with thyroxine. Forty-four rabbits and seventeen guinea pigs were given intramuscular injections of thyroxine every other day and sacrificed at varying intervals. Tissues from a series of normal animals (twenty guinea pigs and forty-three rabbits) were examined as a control. The changes in the heart and other tissues of hyperthyroid animals were insignificant and varied but little from changes seen in normal control animals. Of eight thyrotoxic guinea pigs that developed coincidental infection

\* These normal hearts were chosen from individuals who had no cardiac disease nor evidence of any specific or unspecific infection.

(*bronchisepticus*) all showed myocardial lesions. Of nine thyrotoxic guinea pigs, free of infection, only one gave evidence of myocardial change. It is pointed out that hyperthyroidism, *per se*, cannot be held responsible for these lesions, which would appear to have been associated with the infection.

It was noted that rigor mortis of the skeletal muscles occurred much sooner in the bodies of hyperthyroid animals than in normal animals.

#### BIBLIOGRAPHY

1. Iscovesco, M. H., *Bull. et mêm. Soc. méd. Hôp. Paris*, 1912, **34**, 758.
2. Iscovesco, M. H., *Compt. rend Soc. biol.*, 1913, **75**, 361.
3. Hoskins, E. R., *J. Exp. Zool.*, 1916, **21**, 295.
4. Herring, P. T., *Quart. J. Exp. Physiol.*, 1917, **11**, 231.
5. Hewitt, J. A., *Quart. J. Exp. Physiol.*, 1920, **12**, 347.
6. Cameron, A. T., and Carmichael, J., *J. Physiol.*, 1920-21, **54**, p. lxxiv.
7. Simonds, J. P., and Brandes, W. W., *Arch. Int. Med.*, 1930, **45**, 503.
8. Farrant, R., *Brit. Med. J.*, 1913, **2**, 1363.
9. Hashimoto, H., *Endocrinology*, 1921, **5**, 579.
10. Fahr, T., *Centr. allg. Path. u. path. Anat.*, 1916, **27**, 1.
11. Goodpasture, E. W., *J. Exp. Med.*, 1921, **34**, 407.
12. Takane, K., *Virchows Arch. path. Anat.*, 1926, **259**, 1, 737.
13. von Furth, O., *Biochem. Z.*, 1915, **69**, 199.
14. Riesenfeld, G., *Biochem. Z.*, 1920, **109**, 249.
15. Katz, L. N., and Long, C. N. H., *Proc. Roy. Soc. London, Series B*, 1925-26, **99**, 8.
16. Andrus, E. C., McEachern, D., Perlzweig, W., and Herman, S., *J. Clin. Inv.*, 1930, **9**, 16.
17. Strada, F., and Traina, R., *Centr. Bakt., 1. Abt.*, 1900, **28**, 653.
18. Smith, T., *J. Med. Research.*, 1914, **29**, 291.
19. McEachern, D., and Rake, G. W., *Bull. Johns Hopkins Hosp.*, 1931, **48**, 273.

#### EXPLANATION OF PLATE 1

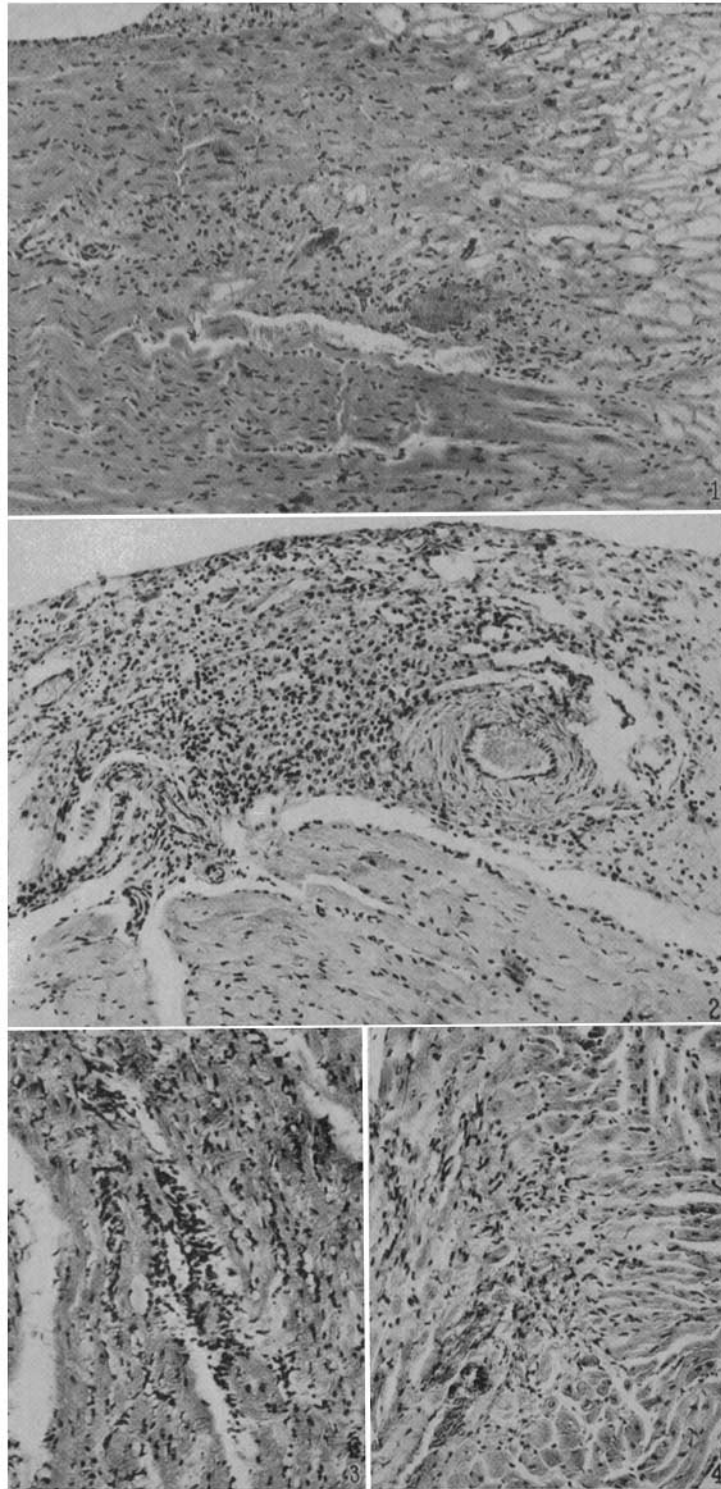
FIG. 1. Section of myocardium from hyperthyroid guinea pig infected by *bronchisepticus*. Area of necrotic fibres surrounded by leucocytes. Vacuolation of muscle fibres.  $\times 94$ .

FIG. 2. Section of myocardium from infected, hyperthyroid guinea pig. Accumulation of large clear cells and of leucocytes.  $\times 94$ .

FIG. 3. Section of myocardium from a normal rabbit. Muscle fibres replaced by area of fibroblasts and lymphocytes.  $\times 112$ .

FIG. 4. Section of myocardium from an hyperthyroid rabbit. Area of disintegration of fibres with small round cells.  $\times 112$ .





(Rake and McEachern: Effect of hyperthyroidism on myocardium)