

CASE REPORT

INTERMEDIATE

CLINICAL CASE

The Case of the Migrating Loop Recorder



Ali A. Hasnie, MD,^a Ammar A. Hasnie, BA,^b Ragheb A. Assaly, MD^a

ABSTRACT

The role of ambulatory electrocardiographic monitoring has changed considerably in recent years with the increased use of implantable loop recorders with their shrinking size. With an excellent safety profile from previous studies, their use is generally seen as a low-risk procedure. Despite this, unexpected complications can occur, including unexpected migration. (**Level of Difficulty: Intermediate.**) (J Am Coll Cardiol Case Rep 2019;1:156-60) © 2019 The Authors. Published by Elsevier on behalf of the American College of Cardiology Foundation. This is an open access article under the CC BY-NC-ND license (<http://creativecommons.org/licenses/by-nc-nd/4.0/>).

HISTORY OF PRESENTATION

A 36-year-old man with a history of unexplained recurrent syncopal episodes was referred to his cardiologist. A decision to implant an implantable loop recorder (ILR) was made, and the loop recorder was inserted according to standard protocol. The Medtronic LINQ loop recorder (Medtronic, Minneapolis, Minnesota) was injected at the left fourth medial intercostal space at a 45-degree angle parallel to the sternum, under local anesthesia. The wound was closed with Dermabond (Johnson & Johnson, New Brunswick, New Jersey). The patient was discharged home with no immediate complications noted and

was advised to follow-up with his cardiologist in 1 week.

He presented to the emergency department 5 days after implantation and stated that while lying in bed he began to have some left-sided chest pain. He reported the chest pain worsened with respiration, as well as with movement of his shoulders and torso, and improved with rest, as well as laying on his right side. The pain was well localized to the area of the incision and did not radiate to his neck, back, shoulders, or jaw. It was described as a sharp chest pain that was reproducible with palpation of the chest wall. He denied fevers, chills, or redness around the incision site. Upon further history taking, he reported that he had experienced some minimal intermittent chest discomfort around the insertion site following implantation but thought that the pain would resolve over the next few days. The patient denied any intentional or unintentional manipulation of the loop recorder following implantation. Because of his atypical chest pain, he was observed for 24 h for acute coronary syndrome. His laboratory workup, including troponins, were negative $\times 3$. Chest x-ray performed at that time was reportedly negative for any acute pathology (**Figure 1**). He was evaluated by the inpatient cardiology team and was advised to be discharged home.

LEARNING OBJECTIVES

- Recognize the risk of loop recorder migration with the increasing use and implantation of ILRs.
- Review the common complications of ILR implantation, as well as some rare complications of implantation.
- Avoid underestimating patient symptoms and have a high index of suspicion of rare complications, even following minor procedures, such as loop recorder implantation.

From the ^aDepartment of Internal Medicine, University of Toledo, Toledo, Ohio; and the ^bDepartment of Internal Medicine, University of Missouri-Kansas City School of Medicine, Kansas City, Missouri. The authors have reported that they have no relationships relevant to the contents of this paper to disclose.

Manuscript received May 7, 2019; revised manuscript received June 8, 2019, accepted June 13, 2019.

He presented again to his cardiologist the following day due to persistent complaints of chest and upper abdominal pain. An attempt was made to evaluate the loop recorder at the time of presentation but was unsuccessful. He was referred for an outpatient chest x-ray. The repeat chest x-ray noted what appeared to be a loop recorder present near the upper quadrant of the abdomen (**Figure 2**).

The patient was urged to present to the emergency department for further evaluation. Further imaging was performed, including computed tomography of the chest and abdomen, which revealed a loop recorder located posterior to the left eighth rib and inferior to the diaphragm abutting the anterolateral abdominal wall (**Figures 3A to 3D**).

He was admitted to the inpatient service and was taken to the operating room by general surgery for removal of the loop recorder. The patient's chest pain and flank pain resolved, and he was ultimately discharged home with scheduled follow-up with his cardiologist.

MEDICAL HISTORY

The patient had medical history significant for recurrent unexplained syncope. He had no medical history of psychiatric disorders.

DIFFERENTIAL DIAGNOSIS

In this case, the primary diagnosis was of an atypical presentation of acute coronary syndrome. Other differentials that arose in this case included the possibilities of pneumonia and pulmonary embolism, and the remote possibility of migration of the ILR.

INVESTIGATIONS

In this case, the primary investigation initiated at the initial presentation was a chest x-ray to rule out any acute cardiopulmonary process and measurement of troponin biomarkers to rule out the possibility of an acute coronary syndrome. With both of these initial results negative, the patient was deemed stable and discharged home. His persistent complaint of pain and the inability to locate the ILR at the site of insertion prompted a more thorough investigation, including a chest x-ray that included a portion of the abdomen that allowed visualization of the ILR in the anterior abdominal wall. This prompted further investigation with computed tomography of the chest, abdomen, and pelvis, which allowed clear visualization of the ILR.

MANAGEMENT

The patient was admitted to the inpatient service and underwent surgical removal of the ILR by dissection of the muscular layer to allow access to the pro-peritoneal space. Without violating the peritoneal cavity, the ILR was visualized, mobilized, and explanted without complication. The patient was subsequently discharged home.

DISCUSSION

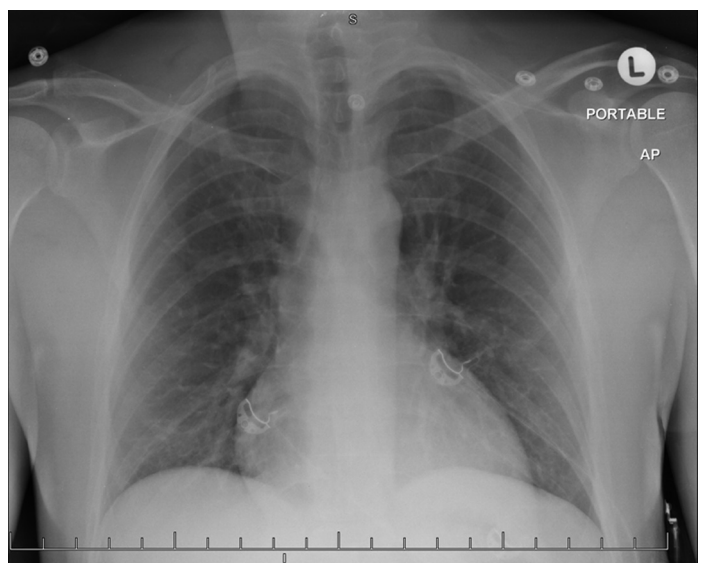
The role of ambulatory electrocardiographic monitoring has changed considerably in recent years. There are a myriad of devices available to cardiologists for short-term monitoring, including Holter monitors, event recorders (both external and internal), as well as real-time continuous cardiac monitoring systems (1). ILRs have been gaining significant interest in recent years for outpatient cardiac monitoring because of their small size, lack of external leads, and long battery life (1), and their ability to be implanted by a general cardiologist. ILRs are most commonly used to evaluate unexplained recurrent syncope, palpitations, or episodes of suspected atrial fibrillation (2). To date, the Medtronic Reveal LINQ is the most commonly used ILR (2). Originally, the devices were quite large. The first approved device

ABBREVIATIONS AND ACRONYMS

ECG = electrocardiogram

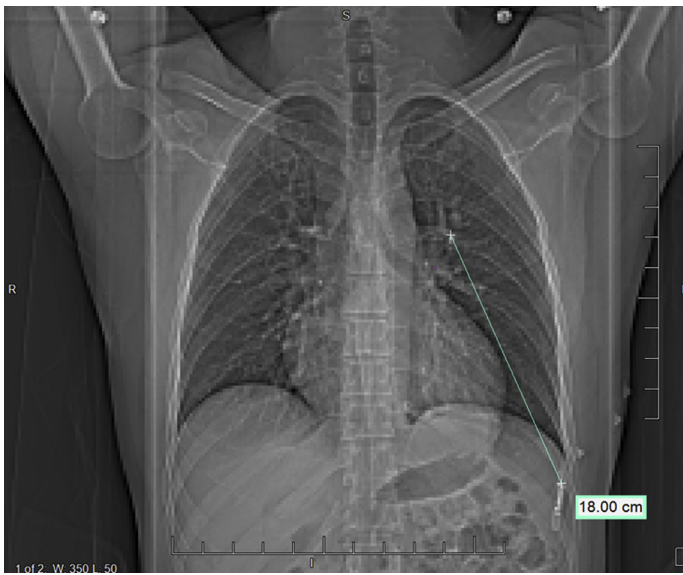ILR = implantable loop recorder

FIGURE 1 Chest X-Ray Demonstrating Absence of Implanted Loop Recorder



This image demonstrates the absence of the loop recorder at the fourth intercostal space on the initial imaging performed on the patient.

FIGURE 2 Migration of the Implanted Loop Recorder

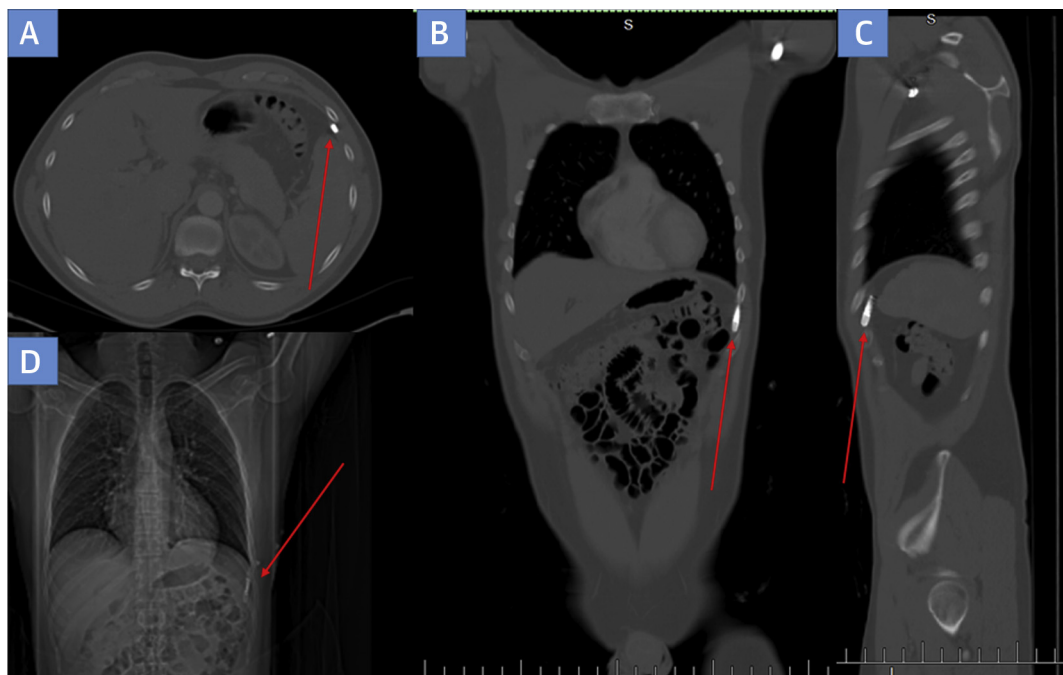


The distance of migration of the loop recorder from the approximated site of insertion to the site of recovery.


was the Medtronic Reveal, which was $19 \times 61 \times 8$ mm and required suturing to prevent migration of the device (3). The newest devices, including the Medtronic LINQ, are only $7 \times 44 \times 4$ mm in size (Figure 4) and are estimated to be 87% smaller than its predecessors (4). The insertion technique has been greatly simplified as well; the ILR is pre-loaded in an insertion tool (Figure 4) and is delivered subcutaneously through a small incision, which is then closed with suture, surgical glue, or staples (5). Despite the admirable safety profile associated with the implantation of these devices, there have been rare cases of complications occurring.

Loop recorders were first studied for implantation in 1995 by Krahn et al. (6), who found they identified causes of unexplained syncope in 96% of the patients who had the device implanted. Causes for the syncope varied, but the groundwork was laid out for their use in future evaluations (6). The safety of ILRs were studied previously. One study found that of 154 patients who received a Medtronic LINQ, only 1 required explantation due to skin erosion (7). Another study looking at 2 different populations of patients implanted with a loop recorder found infection rates

FIGURE 3 Various Imaging Demonstrating Migration of the ILR From the Original Site of Implantation



Imaging performed on initial emergency room encounter demonstrating lack of loop recorder in the chest. Loop recorder demonstrated on (A) cross-sectional, (B) frontal, and (C) sagittal computed tomographic scans, as well as on (D) chest x-ray.



between 1% and 2% and serious adverse event rates between 0.7% and 1.6%; however, none of those reported events required surgical intervention (8). Despite this strong safety profile, other adverse events were rarely reported, with 1 case requiring surgical intervention.

Besides causing local site reactions and infections, loop recorders were found to have unintended displacements beyond the site of implantation (9). One case found an ILR in the left pleural cavity nearly 35 days after implantation. The investigators suspected the tip of the insertion tool penetrated the pectoralis major and external intercostal muscles, which allowed the tip of the ILR to be deeper than anticipated (2). Device erosion was also previously reported in the pediatric population; in one instance, the loop recorder was lost and was suspected to have been pulled out by the child (10).

In this case, we suspected a multitude of factors contributing to the migration of the loop recorder from the original insertion site. The loop recorder operator likely applied additional unnecessary pressure in the initial implantation of the loop recorder, which resulted in partial penetration of the pectoralis major muscle. This allowed further migration of the loop recorder from the initial implantation over time. Lack of experience was unlikely to have contributed to this complication because the procedure operator had >20 years of experience as an electrophysiologist, which suggested that this

complication could occur with even the most experienced cardiologists.

FOLLOW-UP

The patient subsequently followed up with his cardiologist for his recurrent unexplained syncope. He was advised to consider re-implantation of a loop recorder for further evaluation but ultimately did not undergo the procedure again, citing concerns with the initial migration.

CONCLUSIONS

With the increasing use of ILRs, there will likely be an increase in rare reported complications. Migration of an ILR to the anterior abdominal wall requiring surgical exploration and removal has not previously been reported in the literature. Because of the rarity of this complication, it is important to be aware and cognizant of the potential for migration of loop recorders to unintended locations. It is especially important to recognize the atypical presentations of ILR migration and to consider the diagnosis for patients presenting with seemingly unrelated symptoms.

ADDRESS FOR CORRESPONDENCE: Dr. Ali A. Hasnie, Department of Internal Medicine, College of Medicine and Life Sciences, University of Toledo, 3000 Arlington Avenue, MS# 1150, Toledo, Ohio 43614. E-mail: ali.hasnie@utoledo.edu.

REFERENCES

1. Zimetbaum P, Goldman A. Ambulatory arrhythmia monitoring: choosing the right device. *Circulation* 2010;122:1629-36.
2. Preminger MW, Musat DL, Sichrovsky T, Bhatt AG, Mittal S. Migration of an implantable loop recorder into the pleural space. *Heart Rhythm Case Rep* 2017;3:539-41.
3. Krahn AD, Klein GJ, Yee R, Takle-Newhouse T, Norris C. Use of an extended monitoring strategy in patients with problematic syncope. *Reveal Investigators. Circulation* 1999;99:406-10.
4. Tomson TT, Passman R. The Reveal LINQ insertable cardiac monitor. *Expert Rev Med Devices* 2015;12:7-18.
5. Purerfellner H, Sanders P, Pokushalov E, et al. Miniaturized Reveal LINQ insertable cardiac monitoring system: first-in-human experience. *Heart Rhythm* 2015;12:1113-9.
6. Krahn AD, Klein GJ, Norris C, Yee R. The etiology of syncope in patients with negative tilt table and electrophysiological testing. *Circulation* 1995;92:1819-24.
7. Maines M, Zorzi A, Tomasi G, et al. Clinical impact, safety, and accuracy of the remotely monitored implantable loop recorder Medtronic Reveal LINQTM. *Europace* 2017;20:1050-7.
8. Mittal S, Sanders P, Pokushalov E, et al. Safety Profile of a miniaturized insertable cardiac monitor: results from two prospective trials. *Pacing Clin Electrophysiol* 2015;38:1464-9.
9. Brignole M, Donato P, Oddone D. Migration of an 'injectable' loop recorder in the dorsal pleural cavity. *Europace* 2017;20:24.
10. Chaouki AS, Czosek RJ, Spar DS. Missing LINQ: extrusion of a new-generation implantable loop recorder in a child. *Cardiol Young* 2016;26:1445-7.

KEY WORDS chest pain, complication, electrophysiology