

Long-term reversibility of renal dysfunction associated to light chain deposition disease with bortezomib and dexamethasone and high dose therapy and autologous stem cell transplantation

Tomás J. González-López,¹
 Lourdes Vázquez,¹ Teresa Flores,²
 Jesus Fernando San Miguel,¹
 Ramon García-Sanz¹

¹Hematology Department; ²Pathology Service, University Hospital of Salamanca, Salamanca, Spain

Abstract

A 63-year-old woman presented with progressive renal insufficiency, until a glomerular filtration rate (GFR) of 12 mL/min. A renal biopsy demonstrated glomerular deposition of immunoglobulin κ light chain. The presence of a small population of monoclonal plasmacytes producing an only light κ monoclonal component was demonstrated and Bortezomib and Dexamethasone (BD) was provided as initial therapy. After seven courses of therapy, renal function improved without dialysis requirements up to a GFR 31 mL/min. Under hematological complete response (HCR) the patient underwent high dose of melphalan (HDM) and autologous peripheral blood stem cell transplant. Fifty-four months later the patient remains in HCR and the GFR has progressively improved up to 48 mL/min. This report describes a notably renal function improvement in a patient with Light Chain Deposition Disease after therapy with BD followed by HDM, which can support this treatment as a future option for these patients.

Introduction

Light Chain Deposition Disease (LCDD) is a rare plasma cell dyscrasia characterized by deposition of monoclonal immunoglobulin light chains (LCs) in various organs.¹ LCs are physiologically filtered by glomeruli, reabsorbed in proximal tubules and degraded in tubular cells, which makes kidney a prominent target for LC deposition.^{2,3} In this disease, monoclonal component is κ in virtually 100% of cases,¹ which contrasts with the higher lambda frequency that is present in primary amyloidosis (AL). LCDD can be a primary disorder, although it is usually described associat-

ed to lymphoproliferative disorders or plasma cells dyscrasias (~50% with concurrent multiple myeloma). From the clinical point of view, most patients with LCDD present with nephrotic range proteinuria and rapid deteriorating renal function.⁴ Pathogenic background for nephrotic syndrome usually is predominant glomerular deposition (similar to AL amyloidosis), but some have predominant tubular deposition resulting in renal insufficiency with not very high proteinuria.⁴

There is no standard treatment for patients with LCDD. Traditionally, specific treatment of LCDD has been considered to be ineffective in altering the course of the severe or end-stage renal failure.^{1,2,5} High dose therapy (HDT) and autologous peripheral blood stem cell transplantation APBSCT have been demonstrated to be efficient, even providing the possibility of renal disease reversibility in LCDD.⁶⁻¹⁰ However, the use of this strategy in patients with end-stage renal disease is of very high risk.¹¹ Some reports have demonstrated that bortezomib and dexamethasone (BD) can be very effective in AL.¹² Taking into account the similarities between AL and LCDD, some experiences have also shown that BD can be an option in LCDD.¹³ Accordingly, the combination of both strategies, BD and HDT, results very attractive, but no experience has been reported up to now in this specific situation.

Here we present a patient with an end-stage renal failure associated to LCDD in whom BD followed by HDT and APBSCT resulted in HCR and renal function recovery, allowing the patient to be treatment and dialysis independent for more than four years.

Case Report

ACF, female, was diagnosed in January 2006 at 63 of age, as having a renal impairment. The Nephrology Dept. of our hospital observed a progressive increase in the creatinine levels from 2.2 mg/dL to 5.2 mg/dL (creatinine clearance: from 33 mL/min to 17 mL/min) in only 10 months. Since no clear explanation for the disorder was initially found, in November 2006 a renal biopsy was performed to elucidate the origin of the renal chronic failure, and a κ light chain deposition disease (kLCDD) diagnosed.

The patient was then admitted to Hematology for refining the diagnosis and to initiate appropriate treatment. The bone marrow aspirate demonstrated 9% of Bone marrow plasma cells (BMPC). Flow cytometry demonstrated a 6% bone marrow plasmacytosis with κ restriction in cytoplasmic immunoglobulins, as well as an aberrant immunophenotype (CD138+, CD38+++, CD56+, CD19-, CD45-) and a non-hyperdiploid DNA cell content. Among the plasma cell compartment, 90% of

Correspondence: Ramón García-Sanz, Hematology Department, University Hospital of Salamanca, Paseo San Vicente 58-182, 37007 Salamanca, Spain.
 Tel: +34.923.291.629 - Fax: +34.923.294.624
 E-mail: rgarcias@usal.es

Key words: light chain deposition disease; free light chain; monoclonal gammopathy; bortezomib; transplant.

Received for publication: 19 September 2011.
 Accepted for publication: 11 October 2011.

This work is licensed under a Creative Commons Attribution NonCommercial 3.0 License (CC BY-NC 3.0).

©Copyright T.J. González-López et al., 2011
 Licensee PAGEPress, Italy
 Clinics and Practice 2011; 1:e95
 doi:10.4081/cp.2011.e95

cells were aberrant, but 10% displayed normal immunophenotype (Figure 1). Conventional karyotype and FISH analysis for IgH translocations, Rb deletion and P53 deletion were normal either. Radiologic bone survey did not show any lytic lesion and serum calcium was normal. The serum creatinine at the moment was 6.4 mg/dL. Conventional serum electrophoresis and immunofixation failed to detect any monoclonal protein (Figure 2 and 3). Within a high amount of urinary proteins, a minimum peak was observed, and the immunofixation demonstrated a very weak monoclonal-like band in the anti- κ line and was scored as possible positive. In addition, the serum free light chain determination was highly favorable for κ , rendering a κ/λ ratio of 64.4, typically monoclonal. Accordingly, she was diagnosed as suffering Primary Light Chain Deposition Disease with renal impairment. Since the serum creatinine was higher than 5 mg/dL from the beginning, autologous stem cell transplantation (ASCT) was rejected as a first line therapy for the patient. Accordingly, after informed consent signing and legal authorization, patient started to receive bortezomib (1.3 mg/m² on days 1, 4, 8 and 11) and dexamethasone (20 mg on days 1, 2, 4, 5, 8, 9, 11 and 12) in cycles every 21 days. After four courses, complete response (CR) according to the EBMT criteria¹⁴ was achieved. Then, a peripheral blood stem cell (PBSC) collection was performed after G-CSF mobilization (5 μ g/Kg/12 h for 4 days). One successful apheresis procedure was carried out yielding a total of 2.55·10⁶/Kg CD34⁺ cells. Two additional consolidation cycles of BD were administered and the transplant procedure was undergone with melphalan 140 mg/m², since the filtration glomerular rate was below 25 mL/min. Pre-

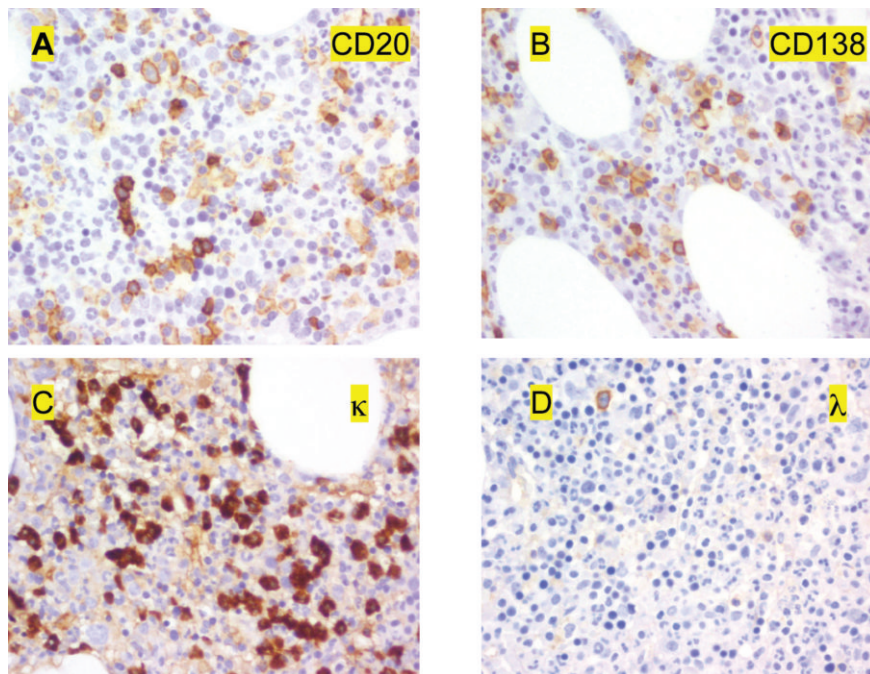
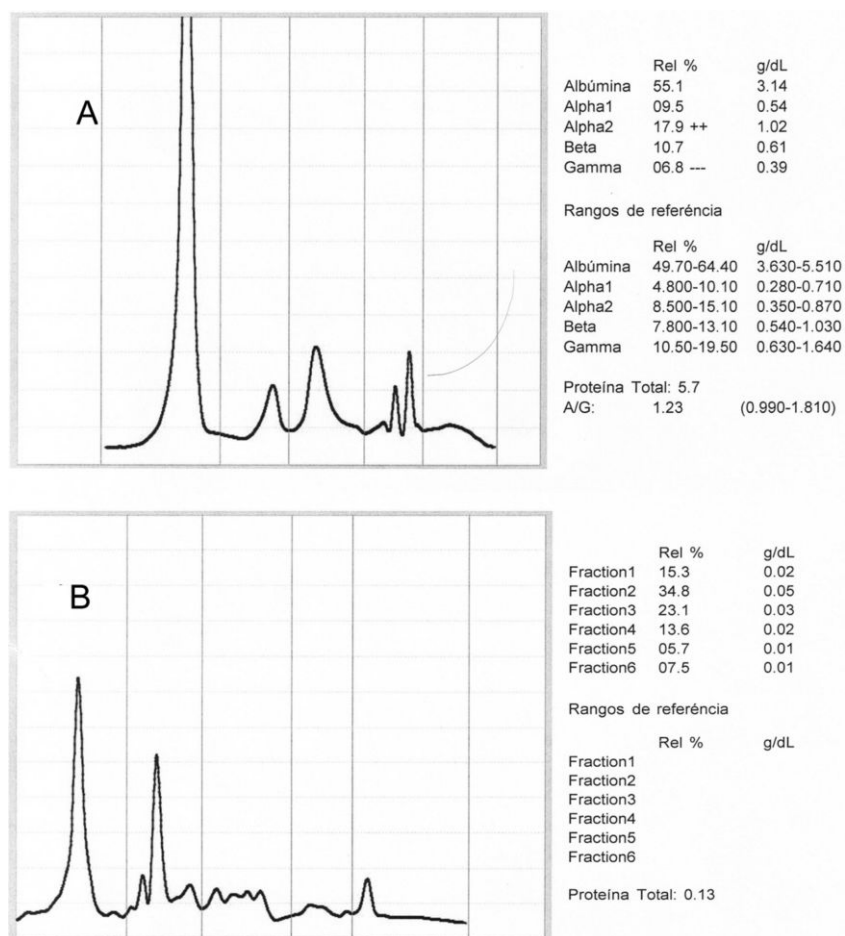


Figure 1. Immunohistochemistry images of the bone marrow: positive dye for CD20 (A), CD138 (B), κ light chains (C) and negative dye for λ light chains (D).

transplant evaluation demonstrated that patient was in stringent CR according to the recently published criteria of the international myeloma working group (IMWG):¹⁵ negative serum and urine immunofixation, normal serum free light κ /lambda ratio, less than 5% of BMPC by morphology and no monoclonal plasma cells by flow cytometry (0.14% of plasma cells, but all with normal immunophenotype). At this moment, the serum creatinine was 3.93 mg/dL, and no one dialytic procedure had been required at this point (Figure 4). The transplant was carried out without major complications with the exception of fluid overload on day +1, which required one peritoneal dialysis and intensive diuretic therapy. The patient was discharged on day +23 with normal peripheral blood counts. An evaluation performed at day +100, demonstrated a sustained stringent CR, an improvement in the clearance creatinine to 28 mL/min and a serum creatinine of 3.05 mg/dL. Serial determinations demonstrated a progressive decrease of creatinine levels below 2.50 mg/dL and FGRs beyond 30 mL/min; more importantly, no hydroelectrolytic disturbances or fluid overloads have been noted and the arteriovenous fistula, initially created at diagnosis in 2006 as a preparation for chronic hemodialysis, has never been used. At this moment, almost five years after diagnosis, the LCDD is in sCR, the patient is free of dialysis, the creatinine level is of 2.31 mg/dL, and the FGR is 38 mL/min, with a creatinine clearance around 50 mL/min.



Discussion

The case here reported represents a success of the applicability of the new available strategies for both diagnosis and therapy of multiple myeloma (MM) to other monoclonal gammopathy related diseases, such it is Light Chain Deposition Diseases (LCDD). As far as the diagnosis is concerned, the use of the test for serum Free Light Chain assessment allowed confirming the presence of a monoclonal component in this patient. Without this assay, this patient would not have had an unequivocal assessment of systemic monoclonality. First, the monoclonal nature of the light chain deposition in the involved tissues (kidney in this case) is frequently very difficult to be assessed due to technical reasons.¹⁶⁻¹⁹ Second, the presence of a monoclonal light chain deposition in the kidney does not necessarily mean the presence of a systemic disease. This is the reason of why up to 32% of these cases are traditionally considered as idiopathic,² and why renal transplantation was considered in the past as a possible therapy for such patients.²⁰ However, the recurrence of the light chain deposition in the transplanted kid-

Figure 2. Electrophoresis of serum (A) and of urine (B) sample of the patient.

ney is the rule,²⁰⁻²⁶ probably because of the absence of a correct accompanying systemic therapy against the clone responsible for the light chain production which is presumed to be sited at the bone marrow.¹ Our patient would have been probably considered as a candidate for kidney transplantation if the absence of the FLC test, because of the lack of a definitive proof of systemic disease. In addition, flow cytometry (FCM) demonstrated the presence of a monoclonal plasma cell population in the bone marrow, a heavy argument favoring the existence of a systemic disease, although FCM is not yet considered in the criteria for initial diagnosis in monoclonal gammopathies.

In contrast, the use of APBSCT has demonstrated some good results in LCDD,^{6,7,10,27,28} which has also allowed the use of therapies using sequential stem cell and kidney transplants.²⁹ Many treatments have been used for this disease with poor results (Alkylating agents with steroids) or increased mortality and significant toxicity (High-dose melphalan (HDM) with autologous stem cell transplantation (ASCT)). However, a serum creatinine >5 mg/dL is a very poor prognostic indicator for APBSCT,¹¹ so this strategy should be done after some organic response of the disease is achieved. Bortezomib has shown significant activity and can be safely administered to MM

patients with renal failure,^{30,31,31-33} which has prompted to develop combined strategies using bortezomib prior to APBSCT.^{31,34} In addition, bortezomib is also capable to provide hematologic and organ responses in primary amyloidosis.^{12,35-37} However, there is little experience with bortezomib in the treatment of LCDD, although the bortezomib mechanism of action seems to be targeted directed³⁸ and there are some experiences that have indicated that bortezomib is able to reverse the renal failure linked to light chain deposition in myeloma.³⁹ Actually, in some few cases Bortezomib has showed rapid hematologic responses, rapid decrease of proteinuria and some improvement of renal function,^{13,40,41} although duration of responses longer year and a half have not been demonstrated yet.

The use of the combined strategy with an induction to response with Bortezomib followed by a consolidation with high dose therapy and APBSCT has not been evaluated yet, especially in long-term follow-up. Our patient initially received 6 cycles of Bortezomib and Dexamethasone with an excellent hematological response and a partial recovery of renal function. This condition allowed allocating the patient in a program of APBSCT with the patient in hematological CR and good renal condition to tolerate the procedure. Thus, the

use of high dose melphalan and APBSCT consolidated the response for a very long time, so the patient is in continuous stringent CR for more than 4 years after its initial achievement.

In summary, this case illustrates that very efficient new therapeutic strategies developed for MM, such it is the BD followed by APBSCT, can be an option for other rarer monoclonal gammopathy related disorders, such it is LCDD.

References

- Merlini G, Stone MJ. Dangerous small B-cell clones. *Blood* 2006;108:2520-30.
- Pozzi C, D'Amico M, Fogazzi GB, et al. Light chain deposition disease with renal involvement: clinical characteristics and prognostic factors. *Am J Kidney Dis* 2003;42:1154-63.
- Ronco P, Plaisier E, Mougnot B+, Aucouturier P. Immunoglobulin Light (Heavy)-Chain Deposition Disease: From Molecular Medicine to Pathophysiology-Driven Therapy. *Ci J Am Soc Nephrol* 2006;1:1342-50.
- Buxbaum JN, Chuba JV, Hellman GC, et al. Monoclonal immunoglobulin deposition disease: light chain and light and heavy chain deposition diseases and their relation to light chain amyloidosis. Clinical features, immunopathology, and molecular analysis. *Ann Intern Med* 1990;112:455-64.
- Heilman RL, Velosa JA, Holley KE, et al. Long-term follow-up and response to chemotherapy in patients with light-chain deposition disease. *Am J Kidney Dis* 1992;20:34-41.
- Lorenz EC, Gertz MA, Fervenza FC, et al. Long-term outcome of autologous stem cell transplantation in light chain deposition disease. *Nephrol Dialysis Transpl* 2008;23:2052-7.
- Firkin F, Hill PA, Dwyer K, Gock H. Reversal of dialysis-dependent renal failure in light-chain deposition disease by autologous peripheral blood stem cell transplantation. *Am J Kidney Dis* 2004;44:551-5.
- Weichman K, Dember LM, Prokaeva T, et al. Clinical and molecular characteristics of patients with non-amyloid light chain deposition disorders, and outcome following treatment with high-dose melphalan and autologous stem cell transplantation. *Bone Marrow Transplant* 2006;38:339-43.
- Adam Z, Krejci M, Pour L, et al. [Complete remission of nephrotic syndrome and improvement of renal function in a patient with light chain deposition disease following high dose chemotherapy with transplantation of autologous haematopoietic stem cells. A case study and review of liter-

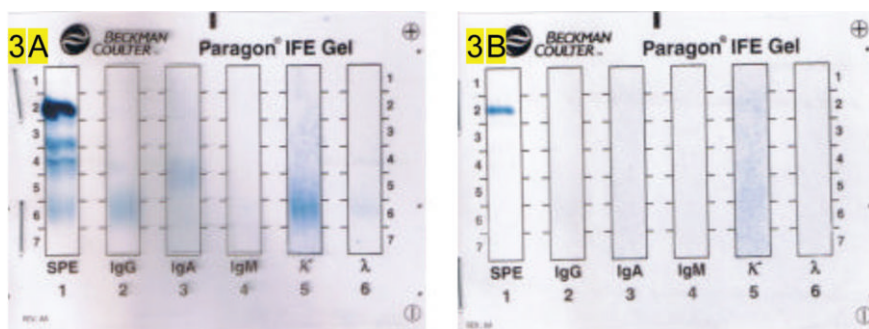

Figure 3. Immunofixation negative in serum (A) and slightly positive in urine (B) of the patient.

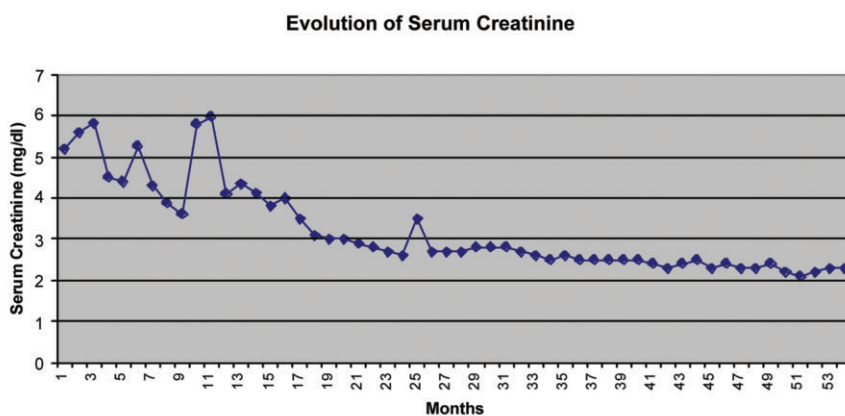


Figure 4. Graphic representing the evolution of serum creatinine of the patient.

- ature J. *Vnitr Lek* 2009;55:1089-96.
10. Matsuzaki K, Ohsawa I, Nishitani T, et al. Marked improvement by high-dose chemotherapy and autologous stem cell transplantation in a case of light chain deposition disease. *J Nephrol* 2011;24:246-9.
 11. San Miguel JF, Lahuerta JJ, Garcia-Sanz R, et al. Are myeloma patients with renal failure candidates for autologous stem cell transplantation? *Hematol J* 2000;1:28-36.
 12. Kastritis E, Wechalekar AD, Dimopoulos MA, et al. Bortezomib With or Without Dexamethasone in Primary Systemic (Light Chain) Amyloidosis. *J Clin Oncol* 2010;28:1031-7.
 13. Kaposztas Z, Kahan BD, Katz SM, et al. Bortezomib successfully reverses early recurrence of light-chain deposition disease in a renal allograft: a case report. *Transplant Proc* 2009;41:4407-10.
 14. Blade J, Samson D, Reece D, et al. Criteria for evaluating disease response and progression in patients with multiple myeloma treated by high-dose therapy and haemopoietic stem cell transplantation. Myeloma Subcommittee of the EBMT. European Group for Blood and Marrow Transplant. *Br J Haematol* 1998;102:1115-23.
 15. Durie BG, Harousseau JL, Miguel JS, et al. International uniform response criteria for multiple myeloma. *Leukemia* 2006;20:1467-73.
 16. Leers MPG, Theunissen PHMH, Ramaekers FCS, et al. Clonality assessment of lymphoproliferative disorders by multiparameter flow cytometry of paraffin-embedded tissue: an additional diagnostic tool in surgical pathology. *Hum Pathol* 2000;31:422-7.
 17. Inagaki H, Nonaka M, Nagaya S, et al. Monoclonality in gastric lymphoma detected in formalin-fixed, paraffin-embedded endoscopic biopsy specimens using immunohistochemistry, in situ hybridization, and polymerase chain reaction. *Diagn Mol Pathol* 1995;4:32-8.
 18. Mendes S, Dreno B. Diagnosis of primary cutaneous B-cell lymphoma by immunohistochemical and in situ hybridization methods. *Acta Derm Venereol* 2003;83:167-70.
 19. Dey P. Role of ancillary techniques in diagnosing and subclassifying non-Hodgkin's lymphomas on fine needle aspiration cytology. *Cytopathology* 2006;17:275-87.
 20. Leung N, Lager DJ, Gertz MA, et al. Long-term outcome of renal transplantation in light-chain deposition disease. *Am J Kidney Dis* 2004;43:147-53.
 21. Alpers CE, Marchioro TL, Johnson RJ. Monoclonal immunoglobulin deposition disease in a renal allograft: probable recurrent disease in a patient without myeloma. *Am J Kidney Dis* 1989;13:418-23.
 22. Short AK, O'Donoghue DJ, Riad HN et al. Recurrence of light chain nephropathy in a renal allograft. A case report and review of the literature. *Am J Nephrol* 2001;21:237-40.
 23. Tanenbaum ND, Howell DN, Middleton JP, et al. Lambda light chain deposition disease in a renal allograft. *Transplant Proc* 2005;37:4289-92.
 24. Alchi B, Nishi S, Iguchi S, et al. Recurrent light and heavy chain deposition disease after renal transplantation. *Nephrol Dial Transplant* 2005;20:1487-91.
 25. Kuypers DR, Lerut E, Claes K, et al. Recurrence of light chain deposit disease after renal allograft transplantation: potential role of rituximab? *Transpl Int* 2007;20:381-5.
 26. Larsen T, Hammer A, Jorgensen KA. Recurrence of light-chain deposition disease after renal transplantation. *Scand J Urol Nephrol* 2008;42:187-8.
 27. Harada K, Akai Y, Sakan H, et al. Resolution of mesangial light chain deposits 3 years after high-dose melphalan with autologous peripheral blood stem cell transplantation. *Clin Nephrol* 2010;74:384-8.
 28. Petrakis I, Stylianou K, Mavroeidi V, et al. Biopsy-proven resolution of renal light-chain deposition disease after autologous stem cell transplantation. *Nephrol Dial Transplant* 2010;25:2020-3.
 29. Barraclough KA, Dowling JP, Schwarzer AP, Perry GJ. Sequential autologous peripheral blood stem cell transplantation and kidney transplantation of light chain deposition disease. *Nephrol Dial Transplant* 2007;22:1268-9.
 30. Mateos MV, San Miguel JF. Bortezomib in multiple myeloma. *Best Pract Res Clin Haematol* 2007;20:701-15.
 31. Dimopoulos MA, Terpos E, Chanan-Khan A, et al. Renal impairment in patients with multiple myeloma: a consensus statement on behalf of the International Myeloma Working Group. *J Clin Oncol* 2010;28:4976-84.
 32. Li J, Zhou DB, Jiao L, et al. Bortezomib and dexamethasone therapy for newly diagnosed patients with multiple myeloma complicated by renal impairment. *Clin Lymph Myeloma* 2009;9:394-8.
 33. Dimopoulos MA, Roussou M, Gavriatopoulou M, et al. Reversibility of renal impairment in patients with multiple myeloma treated with bortezomib-based regimens: identification of predictive factors. *Clin Lymph Myeloma* 2009;9:302-6.
 34. Siniscalchi A, Dentamaro T, Perrotti A, et al. Bortezomib-based therapy as induction regimen of an autograft program in front-line treatment of multiple myeloma with end-stage renal disease. *Ann Hematol* 2010;89:821-2.
 35. Buadi F, Lacy MQ, Dispenzieri A, et al. Retrospective Study of the Efficacy of Bortezomib in Primary Systemic Amyloidosis. *Blood (ASH Annual Meeting Abstracts)* 2009;114:4953.
 36. Lamm W, Willenbacher W, Zojer N, et al. Efficacy of the Combination of Bortezomib and Dexamethasone in Systemic AL Amyloidosis. *Blood (ASH Annual Meeting Abstracts)* 2009;114:2871.
 37. Reece DE, Sanchorawala V, Hegenbart U, et al. Weekly and twice-weekly bortezomib in patients with systemic AL amyloidosis: results of a phase I dose-escalation study. *Blood* 2009;114:1489-97.
 38. Ying WZ, Wang PX, Aaron KJ, et al. Immunoglobulin light chains activate nuclear factor- κ B in renal epithelial cells through a Src-dependent mechanism. *Blood* 2011;117:1301-7.
 39. Ludwig H, Adam Z, Hajek R, et al. Light chain-induced acute renal failure can be reversed by bortezomib-doxorubicin-dexamethasone in multiple myeloma: results of a phase II study. *J Clin Oncol* 2010;28:4635-41.
 40. Kastritis E, Migkou M, Gavriatopoulou M, et al. Treatment of light chain deposition disease with bortezomib and dexamethasone. *Haematologica* 2009;94:300-2.
 41. Gharwan H, Truica CI. Bortezomib-based chemotherapy for light chain deposition disease presenting as acute renal failure. *Med Oncol* 2011. [Epub ahead of print]