

# A new option for treatment of postoperative pancreaticojejunal anastomosis leakage in pancreaticoduodenectomy: Easy and safe

Sir,

Among the tumors affecting gastrointestinal tract pancreatic head and peri-ampullary cancer may show remarkable morbidity and mortality because of its significant structure and function. Obstructive jaundice is a common symptom of patients suffering from peri-ampullary and pancreatic head tumors. The best procedure for treatment of these patients is pancreaticoduodenectomy (PD). Several complications may occur after this procedure including the anastomosis leakage, especially pancreaticojejunostomy-intestinal complications. The only appropriate option for controlling the pancreatic leakage is surgical intervention but the controversy is how to manage this complication. In this manuscript we will explain a safe and easy method to treat the pancreatic leakage after pancreaticoduodenectomy. After operating 42 patients suffering from pancreatic head malignancy with Whipple procedure, pancreaticojejunal anastomosis leakage were reported in 4 cases. For 2 cases the pancreas and adjacent jejunum was debrided and pancreatic stamp as well as jejunal stamp were closed by interrupted sutures. Both the patients were discharged from the hospital by satisfactory general condition. Expected complication of this approach to the pancreatic leak is to inability to maintain the pancreatic exocrine function. It can simply be resolved by long life administration of oral pancreatic enzymes.

Among the tumors affecting gastrointestinal tract pancreatic head and peri-ampullary cancer may show remarkable morbidity and mortality because of its significant structure and function.<sup>[1]</sup> This tumor causes near 150,000 deaths all over the world in a year and between the malignancies ranked as 5<sup>th</sup> leading cause of death.<sup>[2]</sup> Obstructive jaundice is a common symptom of the patients suffering from peri-ampullary and pancreatic head tumors. The best procedure for treatment of these patients is pancreaticoduodenectomy

(PD) which defined by Whipple *et al* in 1935.<sup>[3-7]</sup> Previous studies showed that in some situations this procedure should not be performed for example: Distant tissues affecting with tumoral metastasis, mesenteric and portal vessels affecting and also invasion of tumoral mass to small bowel.<sup>[8]</sup>

In the past 20 years significant improvement in reducing the mortality rate of the procedure in high technology centers occurred. But high morbidity rate of the procedure perioperatively is still a major devastating issue.<sup>[8,9]</sup>

Several complications may occur after this procedure including the anastomosis leakage, especially pancreaticojejunostomy-intestinal complications, infection and delayed massive hemorrhage with unknown prevention.<sup>[10,11]</sup>

The most complicating situation occurring after the Whipple operation refers to pancreaticojejunal anastomosis leakage. It should be considered as the most important factor impresses the morbidity and mortality rate in the patients undergone the procedure. Previous studies showed that the occurrence of this complication is relatively high and can cause up to 13% mortality. Another important issue is other complications caused by leakage which directly affect on the patient's condition and make it worse such as intra abdominal abscess, peritonitis and subsequent sepsis.<sup>[12]</sup> The only appropriate option for controlling the pancreatic leakage is surgical intervention but the controversy is how to manage this complication.

Previous articles present some novel techniques answering this argument: Which operative procedure is more reliable and less-complicated among lots of suggested techniques. Duct to mucosa end-to-side pancreaticojejunostomy, invaginating pancreaticogastrostomy, end-to-side pancreaticogastrostomy, open pancreaticogastrostomy, indwelling pancreaticojejunal anastomosis, reinforcement of anastomosis with fibrin glue or omentum, and placement of internal stent are described by authors in recent years.<sup>[13-15]</sup> In this manuscript we will explain a safe and easy method to treat the pancreatic leakage after pancreaticoduodenectomy.

After operating 42 patients suffering from pancreatic head malignancy with Whipple procedure in Al-Zahra hospital, department of surgery, pancreaticojejunal anastomosis leakage were reported in 4 cases including 3 men and a woman. In 2 cases (a man and a woman) 5-7 days postoperatively, after peritoneal washing,

pancreas debridement is done and it was anastomosed to the stomach. One of the patients was expired and the other was discharged without any major complication. For remained cases (two 70-year-old men) pancreas and adjacent jejunum was debrided and pancreatic stamp as well as jejunal stamp were closed by interrupted sutures [Figure 1]. Both the patients were discharged from the hospital by satisfactory general condition. One of them showed no blood glucose abnormality during the one year period of follow-up. But the other affected by diabetes controlled by oral hypoglycemic agent.

Expected complication of this approach to the pancreatic leak is to inability to maintain the pancreatic exocrine function. It can simply be resolved by long life administration of oral pancreatic enzymes as we did for the patients without any clinically important side effects. In addition due to preservation of pancreatic blood supply it can be conclude than endocrine pancreatic hormones probably remain intact after pancreatic closure. Despite this techniques could not preserved pancreatic exocrine function, however, instead the patient's life may saved by scarifying pancreatojejunal anastomosis. Further studies should be performed to evaluate the short term and long term outcomes of this technique.

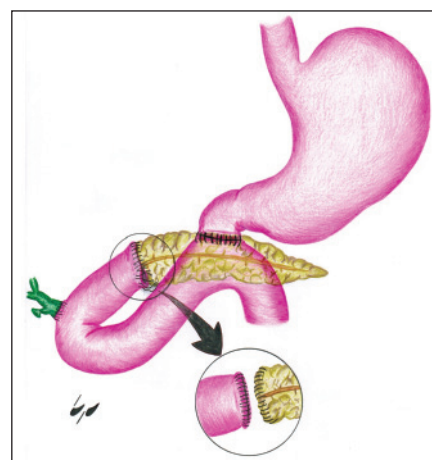
**Sayyed Abbas Tabatabaee, Sayyed Mozaffar Hashemi, Mohamadreza Fazel<sup>1</sup>, Soraya Dadkhah<sup>1</sup>, Amirhosein Davarpanah Jazi<sup>2</sup>**

Department of Surgery, <sup>1</sup>Medical Student Research Center, <sup>2</sup>Medical Education Research Center, Isfahan University of Medical Sciences, Isfahan, Iran

**Address for correspondence:** Dr. Hashemi SM, Department of Surgery, Al Zahra Hospital, Shohadaye Soffeh St, Isfahan, Iran.  
E-mail: mozaffar\_hashemi@med.mui.ac.ir

## REFERENCES

1. Kim SC. Surgical management of pancreatic cancer. *Korean J Gastroenterol* 2008;51:89-100.
2. Friess H, Kleeff J, Fischer L, Müller M, Büchler MW. Surgical standard therapy for cancer of the pancreas. *Chirurg* 2003;74:183-90.
3. Shrikhande SV, Qureshi SS, Rajneesh N, Shukla PJ. Pancreatic anastomoses after pancreaticoduodenectomy: Do we need further studies. *World J Surg* 2005;29:1642-9.
4. Sung JP, Stewart RD, O'Hara VS, Westphal KF, Wilkinson JE, Hill J. A study of forty-nine consecutive Whipple resections for periampullary adenocarcinoma. *Am J Surg* 1997;174:6-10.
5. Andersen DK, Frey CF. The evolution of the surgical treatment of chronic pancreatitis. *Ann Surg* 2010;251:18-32.
6. Whipple AO, Parsons WB, Mullins CR. Treatment of carcinoma of the ampulla of Vater. *Ann Surg* 1935;102:763-9.
7. van der Gaag NA, Rauws EA, van Eijck CH, Bruno MJ, van der Harst E, Kubben FJ, *et al.* Preoperative biliary drainage for cancer of the head of the pancreas. *N Engl J Med* 2010;362:129-37.
8. Smeenk HG, Tran TC, Erdmann J, van Eijck CH, Jeekel J. Survival after surgical management of pancreatic adenocarcinoma: Does curative and radical surgery truly exist? *Langenbecks Arch Surg* 2005;390:94-103.
9. Winter JM, Cameron JL, Campbell KA, Arnold MA, Chang DC, Coleman J, *et al.* 1423 pancreaticoduodenectomies for pancreatic cancer: A single-institution experience. *J Gastrointest Surg* 2006;10:1199-210.
10. Zhu ZY, He JK, Wang YF, Liang X, Yu H, Wang XF, *et al.* Multivariable analysis of factors associated with hospital readmission following pancreaticoduodenectomy for malignant diseases. *Chin Med J (Engl)* 2011;124:1022-5.
11. Wang ZJ, Wang MQ, Liu FY, Duan F, Song P, Fan QS. Role of interventional endovascular therapy for delayed hemorrhage after pancreaticoduodenectomy. *Chin Med J (Engl)* 2010;123:3110-7.
12. Adams DB. The pancreatic anastomosis: The danger of leak, which anastomosis technique is better? *J Gastrointest Surg* 2009;13:1182-3.
13. Poon RT, Fan ST, Lo CM, Ng KK, Yuen WK, Yeung C, *et al.* External drainage of pancreatic duct with a stent to reduce leakage rate of pancreatojejunostomy after pancreaticoduodenectomy: A prospective randomized trial. *Ann Surg* 2007;246:425-33.
14. Adams DB. The pancreatic anastomosis: The danger of a leak, which anastomotic technique is better? *J Gastrointest Surg* 2009;13:1182-3.
15. Rao AC, Gabriel G, Serrano J, Benedicto R. Inkwell pancreatojejunal anastomosis after pancreaticoduodenectomy. *Am J Surg* 2004;187:410-2.



**Figure 1:** Pancreas and adjacent jejunum was debrided and pancreatic stamp, as well as jejunal stamp were closed by interrupted sutures