



Use of Cyclophosphamide in a Child With Fulminant Acute Disseminated Encephalomyelitis

Hana Ayed, MD¹, Mohammed W. Chaudhary, MD¹,
 Raidah AlBaradie, MD¹, and Ali Mir, MD¹

Abstract

Acute disseminated encephalomyelitis is an immune-mediated inflammatory demyelinating disorder of the central nervous system. The first-line treatment is usually high-dose intravenous methylprednisolone. Intravenous immunoglobulin and plasmapheresis have also shown to be beneficial. Immunosuppressive agents like cyclophosphamide have been used in adults with fulminant acute disseminated encephalomyelitis. We report a case of a 3-year-old boy with fulminant acute disseminated encephalomyelitis. Minimal improvement was seen with high-dose intravenous methylprednisolone, intravenous immunoglobulin, and plasmapheresis. Based on the reports of cyclophosphamide being used successfully to treat adult patients with fulminant acute disseminated encephalomyelitis, we used it in our patient who then showed dramatic and quick improvement. We suggest that if conventional treatment fails, cyclophosphamide could be tried in pediatric patients with fulminant acute disseminated encephalomyelitis.

Keywords

fulminant ADEM, acute disseminated encephalomyelitis, cyclophosphamide, plasmapheresis, methylprednisolone

Received January 1, 2017. Received revised November 13, 2017. Accepted for publication November 28, 2017.

Acute disseminated encephalomyelitis is an immune-mediated inflammatory demyelinating disorder of the central nervous system. It can affect both the brain and the spinal cord. It can occur at any age, but it is more common in children. The clinical manifestations initially could be nonspecific such as a headache, fever, and myalgia, which is usually followed by encephalopathy, seizures, focal neurological deficits, and ataxia. Demyelinating lesions are often seen on the magnetic resonance imaging (MRI) of the brain. First-line treatment usually consists of intravenous methylprednisolone along with supportive therapy. Intravenous immunoglobulin is often considered a second-line treatment for patients who do not respond to initial intravenous corticosteroid therapy. Plasmapheresis is used in patients who do not respond to corticosteroids and intravenous immunoglobulin or considered early in fulminant cases. We report a case of a young boy with fulminant acute disseminated encephalomyelitis who was treated with high-dose corticosteroids and intravenous immunoglobulin followed by plasmapheresis. Since there was only a slight and prolonged

improvement, cyclophosphamide (CYC) was used, and the patient showed dramatic and complete recovery.

Case Presentation

Three-year 8-month-old previously healthy boy presented to a local hospital's emergency department complaining of fever, abdominal pain, vomiting, and inability to walk for few hours. Later that day, he also developed a seizure. Septic workup was done, and he was admitted for observation and antibiotics were started to treat possible meningoencephalitis. His parents

¹ Neuroscience department, King Fahad Special Hospital–Dammam, Al-Khobar, Dammam, Saudi Arabia

Corresponding Author:

Hana Ayed, MD, Neuroscience Department, King Fahad Specialist Hospital–Dammam, Ammar Bin Thabit St, Al Muraikabat, Dammam 32253, Saudi Arabia. Emails: hana.ayedh@kfsh.med.sa; hnayed@gmail.com



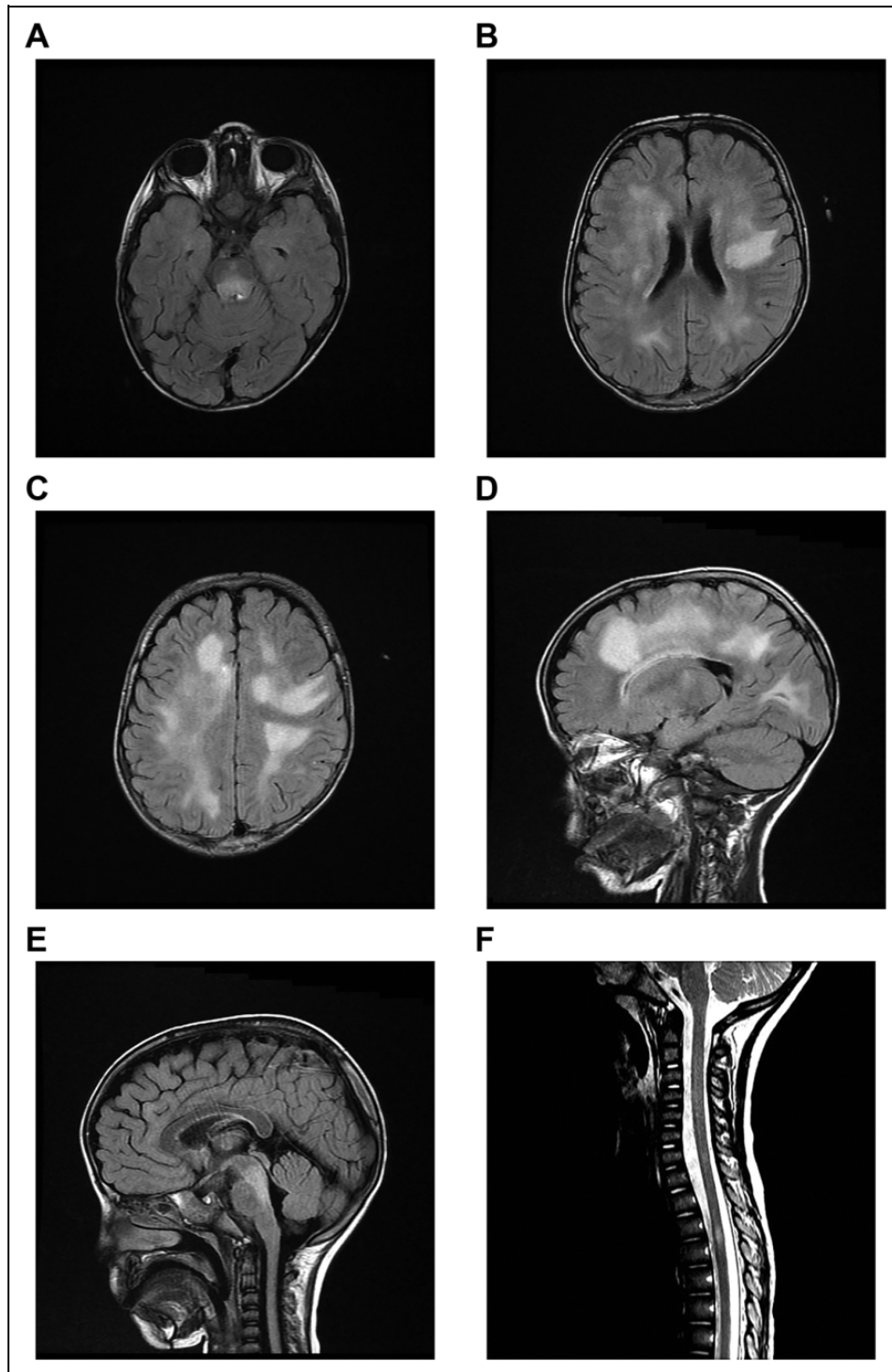


Figure 1. MRI Brain and Spine. (A) Axial FLAIR sequence showing hyper intensity in the posterior aspect of the pons. (B) And (C) Axial FLAIR sequences showing confluent bilateral non-enhancing deep and sub-cortical white matter hyper intensities seen in the frontal and parietal lobes. (D) Sagittal FLAIR sequence showing confluent periventricular and subcortical white matter hyper intensity seen in the frontal and parietal lobes. (E) Sagittal FLAIR sequence showing hyper intensity in the posterior aspect of the pons. (F) Sagittal T2 sequence of MRI spine showing hyper intensity at the level of T3 and T4 vertebrae.

refused a lumbar puncture. The next day his level of consciousness deteriorated rapidly, ultimately leading to coma. Magnetic resonance imaging of the brain was done which showed

more than 3 nonenhancing hyperintense patchy confluent lesions in the deep white matter and subcortical areas suggestive of acute disseminated encephalomyelitis (Figure 1A-D).

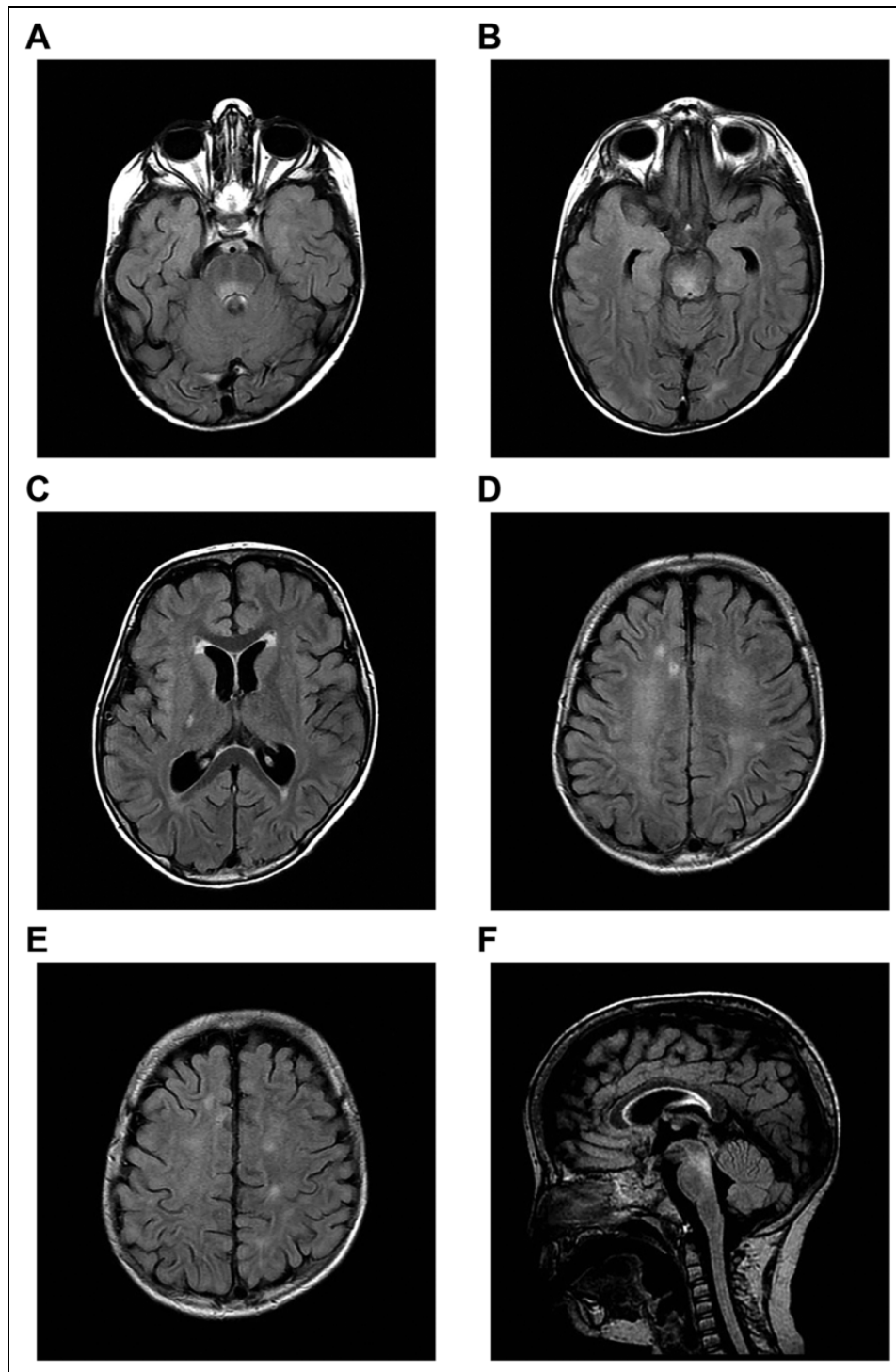


Figure 2. MRI Brain showing interval regression of the white matter hyper intensities on FLAIR sequences with unchanged brainstem hyper intense signal. No new lesions are seen.

The patient was immediately started on pulse corticosteroid therapy, methylprednisolone 20 mg/kg/dose daily for 5 days, and intravenous immunoglobulin 2 g/kg over 5 days. The patient's level of consciousness improved slightly, but 2 days later, he started to become hypertonic and developed intermittent decerebrate posturing.

He was born as first of twins at term, from an uneventful pregnancy weighing 3.5 kg, to consanguineous parents. His developmental history was normal, and past history was unremarkable. Immunizations were up-to-date, and he hadn't received any vaccines in the past 6 months. There was no family history of neurological, genetic, or developmental problems.

He was managed for 12 days at the outside hospital before being transferred to our hospital. When we received the patient, he was intubated and on a mechanical ventilator. Vital signs were within the normal range, and growth parameters were normal. He did not respond to verbal stimuli or blink to bright lights, but he withdrew his extremities to painful stimuli. He had pinpoint pupils, absent oculocephalic reflex, but corneal reflexes were present bilaterally. There was no visible facial asymmetry, and the gag reflex was intact. He had generalized hypertonia, upper limbs greater than lower limbs. He had intermittent decerebrate posturing and appeared not to move his left leg as much as the other extremities upon painful stimuli. He had brisk reflexes all over, positive cross-adductor response, no clonus, and an upgoing plantar response bilaterally. Systemic examination was unremarkable.

On the day of admission to our hospital, he was started on pulse methylprednisolone, 30 mg/kg/dose daily for 5 days and plasma exchange was initiated on the next day for a total of 10 exchanges on alternate days. His routine blood tests were normal. Virology studies including adenovirus, rotavirus, cytomegalovirus, Epstein-Barr virus, enterovirus, influenza A and B, herpes simplex virus, and measles were all negative. Cerebral spinal fluid analysis including cultures was normal. Immunoglobulin G (IgG) index, oligoclonal bands, and neuromyelitis optica IgG (NMO-IgG) were also negative. (Patient was given intravenous immunoglobulin at the outside hospital)

He developed a few tonic seizures confirmed by the video electroencephalography, which were controlled with levetiracetam. The patient was successfully extubated after 8 days and shifted to the general pediatric ward. He started to show minimal improvement, mainly in his mental status. He began to show minimal interaction with his parents by smiling when talked to as well as crying purposefully. His muscle tone improved with no more decerebrate posturing, but he was unable to follow objects and did not blink to a visual threat. The repeat MRI brain at this point showed significant regression of the hyperintense lesions seen before. There was persistent but decreased T2 fluid attenuation inversion recovery hyperintense signal within the posterior aspect of the midbrain and pons (Figure 1E).

Since the patient had only a minimal improvement and a prolonged recovery, during the fifth week of his illness, he was given a second course of intravenous immunoglobulin followed by 1 dose of intravenous CYC, 750 mg/m² body surface area. The very next day, the patient showed a dramatic improvement and became much more alert, was interested in his surroundings, and started to say a couple of words. He then continued to improve further and was able to follow and fixate. His muscle tone continued to improve, and he was able to sit with minimal support. He was discharged later on a 6-week steroid tapering regimen and given an intensive rehabilitation and physiotherapy program. At the 3-month follow-up visit, he was walking by himself and had a normal neurological examination. However, his parents reported that he was irritable, but we attributed that to the corticosteroids and the levetiracetam. At 6-month follow-up appointment, he was

Table 1. 2012 IPMSSG Criteria for Pediatric ADEM.^a

- A first polyfocal, clinical CNS event with presumed inflammatory demyelinating cause
- Encephalopathy that cannot be explained by fever
- No new clinical and MRI findings emerge 3 months or more after the onset
- Brain MRI is abnormal during the acute (3-month) phase.
- Typically on brain MRI:
 - Diffuse, poorly demarcated, large (>1-2 cm) lesions involving predominantly the cerebral white matter
 - T1 hypointense lesions in the white matter are rare
 - Deep gray matter lesions (eg, thalamus or basal ganglia) can be present

Abbreviations: ADEM, acute disseminated encephalomyelitis; CNS, central nervous system; IPMSSG, International Pediatric Multiple Sclerosis Study Group; MRI, magnetic resonance imaging.

^aAdapted from Krupp et al.³

completely back to normal. Repeat MRI brain scan showed even further interval decrease in size and signal intensity of the lesions (Figure 2). At 1-year follow-up visit, he continued to do well with no relapse (Figure 3).

Discussion

Acute disseminated encephalomyelitis is a rare inflammatory, demyelinating disorder of the central nervous system. It can occur at any age, but it is more common in children. Torisu et al¹ reported the incidence rate of childhood acute disseminated encephalomyelitis under the age of 15 years in Japan was 0.64 per 100 000 person-years, mean age at onset was 5.7 years, and male–female ratio was 2.3:1. The diagnosis remains clinical, aided by neuroimaging confirmation due to the lack of specific biological markers.² Clinical presentation is usually characterized by an acute onset of encephalopathy and seizures and associated with multifocal neurologic deficits. There is often a prodromal phase with fever, malaise, headaches, nausea, and vomiting. The presentation is typically monophasic, although recurrent and multiphasic forms have been reported. The cerebrospinal fluid is usually normal or may show a mild lymphocytic pleocytosis. Brain MRI usually shows lesions that are large and multifocal and involve subcortical and deep white matter.

The 2012 International Pediatric Multiple Sclerosis Study Group published revised consensus criteria for diagnosing pediatric acute disseminated encephalomyelitis (Table 1). Our patient met this criterion for pediatric acute disseminated encephalomyelitis.

Pathologically, acute disseminated encephalomyelitis is characterized by the perivenular infiltrates of T cells and macrophages associated with perivenular demyelination with limited sleeves of demyelination.⁴ In the earliest stages of inflammation, T-helper (Th) cells are sensitized to autoantigens such as myelin proteins and class-switched IgG autoantibodies may be found.⁵ The complex ensuing inflammatory cascade entails the local action of cytokines and chemokines as well

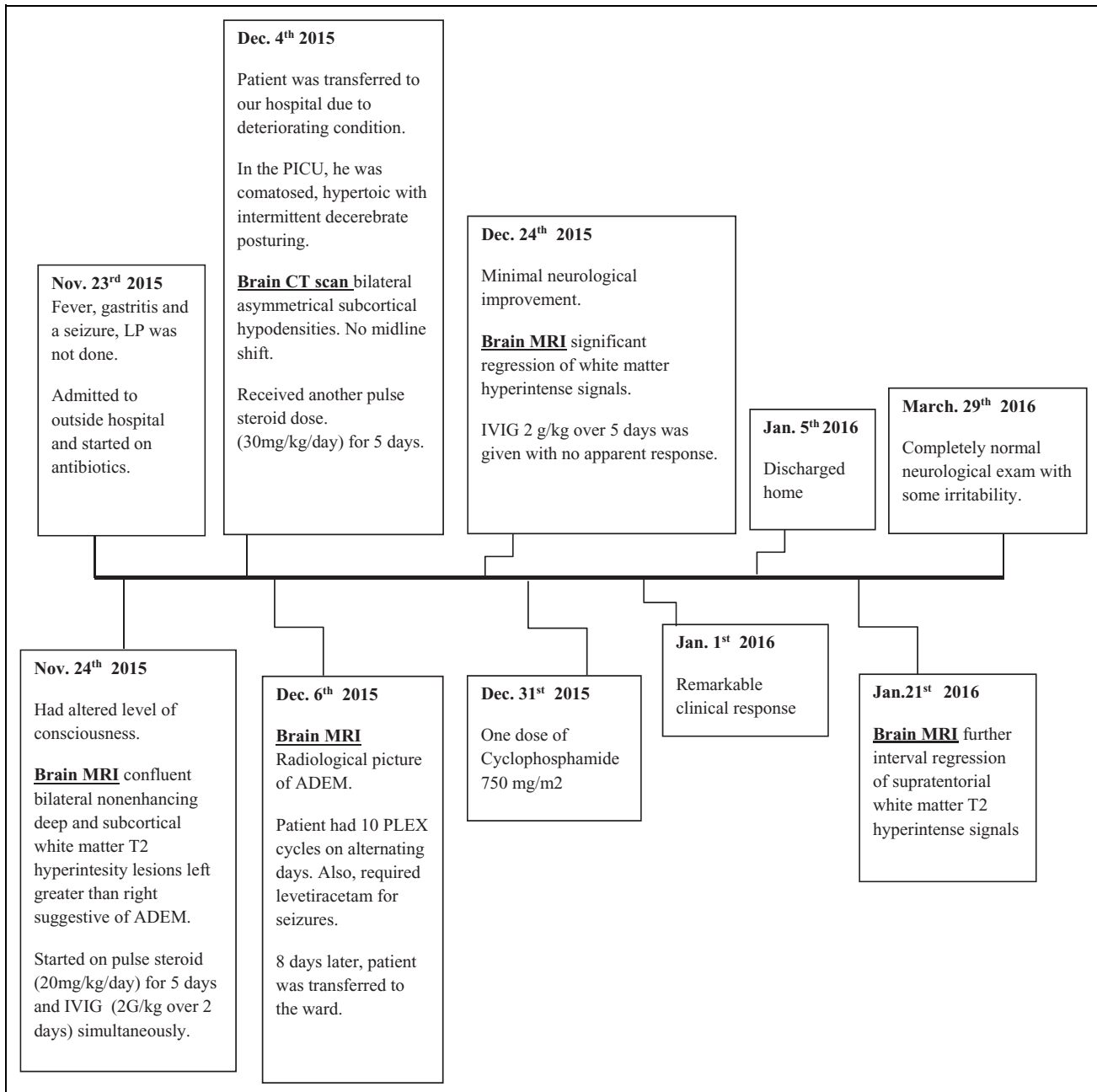


Figure 3. Timeline of the clinical manifestation, treatments and outcome.

as lymphokine-induced chemotaxis of other cellular mediators of inflammation. The increased levels of interferon γ , interleukin-6, and interleukin-8 have been significantly correlated with cerebral spinal fluid cell counts and protein concentration in acute disseminated encephalomyelitis cases. The pattern of cytokine elevation suggests that acute disseminated encephalomyelitis involves the activation of macrophages, microglial cells, and various Th1 and Th2 cells.⁶

High-dose intravenous methylprednisolone given for 3 to 5 days is usually the first choice of treatment for acute disseminated encephalomyelitis.⁷ Tapering oral corticosteroid

treatment over 4 to 6 weeks is given following intravenous methylprednisolone to reduce the risk of relapse. Intravenous immunoglobulin could be used as a second-line treatment, particularly in fulminant acute disseminated encephalomyelitis cases who did not respond to corticosteroids.⁸ Abdrabou et al⁹ reported that patients who received steroids on the first day and intravenous immunoglobulin during the first week of symptom onset had a better outcome. If there is a concern of infection, then intravenous immunoglobulin could be used as an alternative to corticosteroids. Plasmapheresis is another option for treatment in fulminant acute disseminated

encephalomyelitis. Typically, 5 to 7 exchanges are done over the period of 10 to 14 days. Early introduction of plasmapheresis along with intravenous pulse steroids has shown to be beneficial.¹⁰ Our experience has also been the same. Hypothermia has also been used with success in some patients with fulminant acute disseminated encephalomyelitis.¹¹

The CYC is an alkylating antineoplastic agent that binds to DNA and interferes with mitosis and cell replication.¹² The CYC has antimitotic property by targeting rapidly dividing cells, and it has been used as a chemotherapy medication in a range of solid tumors and hematological malignancies. It also has immunosuppressive and immunomodulatory properties as well. It causes suppression of cell-mediated and humoral immunity through its actions on T cells and B cells.¹³ The CYC is used as a second line of therapy for demyelinating diseases such as NMO and progressive multiple sclerosis. In multiple sclerosis, CYC has been shown to decrease the secretion of the pro-inflammatory Th1 cytokine interferon- γ and interleukin-12 and to increase the secretion of the anti-inflammatory Th2 cytokines interleukin-4 and interleukin-10 in cerebral spinal fluid and peripheral blood.¹⁴

It becomes challenging in some cases of fulminant acute disseminated encephalomyelitis which responds only partially and very slowly to the conventional treatment. Rothenberg et al¹⁵ reported a case of a 22-year-old man with refractory acute disseminated encephalomyelitis, who showed significant functional and neurological improvement with the use of CYC. Jaskowiak et al¹⁶ also reported a case of a 49-year-old woman with hemorrhagic acute disseminated encephalomyelitis who showed improvement with the use of CYC after the conventional treatment failed. Schwarz et al¹⁷ also reported the use of CYC in adult patients who showed poor response or no response or who progressively deteriorated during therapy with methylprednisolone.

Our patient received early treatment with corticosteroid and intravenous immunoglobulin followed by plasma exchanges with only minimal improvement. Based on the reports of successful use of CYC in adult patients with fulminant acute disseminated encephalomyelitis, we used it in our patient who showed dramatic and quick improvement with just 1 dose. Although it can be argued that the clinical response could be related to the different treatments patient received, the dramatic response from the very next day of CYC use compels us to believe that CYC had a significant impact on the quick recovery of our patient. At the 6-month follow-up, he was completely back to normal, and the lesions on the MRI brain scan had almost resolved. To our knowledge, there are no reports in the literature regarding the use of CYC in children with fulminant acute disseminated encephalomyelitis.

In summary, not only could fulminant acute disseminated encephalomyelitis be devastating but also the response to treatment and its outcome could be unfavorable even with the use of the recommended treatment. If conventional treatment fails, CYC could be tried in pediatric patients.

Author Contribution

AM, MWC, and RA contributed to conception and design, acquisition, drafted the manuscript, critically revised the manuscript, and gave final approval. HA contributed to conception and design, acquisition, analysis, and interpretation, drafted the manuscript, critically revised the manuscript, and gave final approval.

Declaration of Conflicting Interests

The authors declared no potential conflicts of interest with respect to the research, authorship, and/or publication of this article.

Funding

The authors received no financial support for the research, authorship, and/or publication of this article.

Ethical Approval

An informed consent was taken according to our IRB and hospital regulation.

References

1. Torisu H, Kira R, Ishizaki Y, et al. Clinical study of childhood acute disseminated encephalomyelitis, multiple sclerosis, and acute transverse myelitis in Fukuoka Prefecture, Japan. *Brain Dev.* 2010;32(6):454-462.
2. Young N, Weinschenker B, Lucchinetti C. Acute disseminated encephalomyelitis: current understanding and controversies. *Semin Neurol.* 2008;28(1):84-94.
3. Krupp L, Tardieu M, Amato M, et al. International pediatric multiple sclerosis study group criteria for pediatric multiple sclerosis and immune-mediated central nervous system demyelinating disorders: revisions to the 2007 definitions. *Mult Scler.* 2013;19(10):1261-1267.
4. Greenfield J, Graham D, Lantos P. *Greenfield's Neuropathology.* London, UK: Arnold; 2002.
5. Van Haren K, Tomooka B, Kidd B, et al. Serum autoantibodies to myelin peptides distinguish acute disseminated encephalomyelitis from relapsing-remitting multiple sclerosis. *Mult Scler.* 2013; 19(13):1726-1733.
6. Ishizu T, Minohara M, Ichiyama T, et al. CSF cytokine and chemokine profiles in acute disseminated encephalomyelitis. *J Neuroimmunol.* 2006;175(1-2):52-58.
7. Straub J, Chofflon M, Delavelle J. Early high-dose intravenous methylprednisolone in acute disseminated encephalomyelitis: a successful recovery. *Neurology.* 1997;49(4):1145-1147.
8. Marchioni E, Marinou-Aktipi K, Uggetti C, et al. Effectiveness of intravenous immunoglobulin treatment in adult patients with steroid-resistant monophasic or recurrent acute disseminated encephalomyelitis. *J Neurol.* 2002;249(1):100-104.
9. Sadek AA, Mohamed MA, Abou-Taleb A, Mohammed MI. Pattern and outcome of acute disseminated encephalomyelitis (ADEM) in children: experience in a tertiary center, Upper Egypt. *Electron Physician.* 2016;8(7):2679-2685.
10. de Seze J, Debouverie M, Zephir H, et al. Acute fulminant demyelinating disease. *Arch Neurol.* 2007;64(10):1426-1432.

11. Takata T, Hirakawa M, Sakurai M, Kanazawa I. Fulminant form of acute disseminated encephalomyelitis: successful treatment with hypothermia. *J Neurol Sci.* 1999;165(1):94-97.
12. Kovarsky J. Clinical pharmacology and toxicology of cyclophosphamide: emphasis on use in rheumatic diseases. *Semin Arthritis Rheum.* 1983;12(4):359-372.
13. Kim Y, Choi B, Oh H, Kang W, Mittler R, Kwon B. Mechanisms involved in synergistic anticancer effects of anti-4-1BB and cyclophosphamide therapy. *Mol Cancer Ther.* 2009;8(2):469-478.
14. Smith D, Balashov K, Hafler D, Khoury S, Weiner H. Immune deviation following pulse cyclophosphamide/methylprednisolone treatment of multiple sclerosis: increased interleukin-4 production and associated eosinophilia. *Ann Neurol.* 1997;42(3):313-318.
15. Rothenberg J, Lastra A, Alvarez G, Irwin R. Acute disseminated encephalomyelitis responsive to cyclophosphamide therapy: a case report. *J Med Cases.* 2015;6(7):290-294.
16. Jaskowiak J. Treatment of hemorrhagic acute disseminated encephalomyelitis with cyclophosphamide. *Am J Health Syst Pharm.* 2016;73(4):202-205.
17. Schwarz S, Mohr A, Knauth M, Wildemann B, Storch-Hagenlocher B. Acute disseminated encephalomyelitis: a follow-up study of 40 adult patients. *Neurology.* 2001;56(10):1313-1318.