

Sigmoid adenocarcinoma with renal metastasis

Carini Dagnoni,
Luzete Cristina Silva Granero,
Rodrigo Kraft Rovere

Department of Oncology, Santo Antonio Hospital, Blumenau, Santa Catarina, Brazil

Abstract

We report a case of a 75-year-old man submitted to a rectosigmoidectomy and partial cystectomy because of a sigmoid cancer and colovesical fistula. Seven months later and after four cycles of adjuvant chemotherapy, a lesion was detected in the kidney. Histology revealed tubular adenocarcinoma, which meant sigmoid cancer metastasis. Kidney metastases are very rare in colorectal cancer (CRC), but may be generally associated with an unfavorable prognosis. Thus, patients with metastatic CRC and kidney tumors are a diagnostic and therapeutic challenge.

Case Report

A 75-year-old man with previous history of coronary artery and cerebrovascular disease was admitted to the emergency room of our institution with intense proctalgia, constipation, fecaluria and pneumaturia. He referred loss of more than ten per cent of his weight in one month.

During hospitalization, he also developed dysuria, hematuria, hematochezia and diarrhea. On physical examination, he was in general good clinical condition beside the palpation of soft feces in the rectum.

Initial laboratory tests showed bleeding disorders [TAP: 14.2 (RV: 11-13), KPTT: 52.9 (RV: 29-42)] and decrease in albumin [3.2 (RV: 3.5-5.5)].

The computed tomography (CT) scan of the abdomen performed on the next day revealed a colovesical fistula and sigmoid tumor, besides enlarged abdominal lymph nodes, leading promptly to a rectosigmoidectomy and partial cystectomy.

After recovery from the surgery, the patient received adjuvant therapy with FLOX,¹ which is the regimen reimbursed by the Brazilian national health system. However, after the fourth cycle he developed severe febrile neutropenia requiring intravenous antibiotics and prolonged hospital stay, leading to a decision to suspend further chemotherapy.

The patient remained without any signs of disease relapse until seven months later, when during a routine follow up it was detected a serum tumor marker elevation [CEA: 55.91 (RV <5 ng/mL)], even though the patient remained asymptomatic.

Subsequent abdominal CT scan detected vegetating lesions on the bladder wall and a heterogeneous lesion in the upper pole of the right kidney measuring 4.2×3.9 cm. On chest CT, there was a nodule in left inferior lobe, adjacent the pulmonary hilum, measuring about 1.9 cm (Figure 1).

For further investigation, an urinary tract magnetic resonance imaging (MRI) demonstrated a mass of 5.6×3.6 cm in the middle third of the right kidney, extending to the pelvis.

Initially, the suspicion fell on a new primary tumor, probably an advanced kidney cancer. The patient was then referred to the urology department and underwent tumor puncture guided by ultrasound (Figure 2). Histological examination of the kidney biopsy diagnosed tubular adenocarcinoma infiltrative glandular proliferation (Figure 3), representing a sigmoid cancer metastasis.

Because of clinical worsening, palliative treatment with capecitabine had begun.

The last abdominal CT confirmed local progression of disease and chest CT showed enlarged thoracic lymph nodes. As the performance status was swiftly deteriorating and the patient was bedridden right after the exams, only best supportive care measured had been taken without any further lines of chemotherapy.

Discussion

Metastatic colorectal carcinoma (mCRC) is one of the most common malignant tumors in the Western world.² Although renal cell carcinoma (RCC) is relatively frequent as a second primary tumor in CRC^{3,4} the kidney is an unusual site of metastases in CRC.^{5,6}

The most common primary malignancy to involve the kidney is bronchogenic carcinoma, followed by breast and gastrointestinal cancers.^{5,7}

Colorectal cancer was found to involve the kidneys in only 2.7% of postmortem analyses, being part of an advanced systemic disease.^{5,8} Overall, the frequency of metastases to the kidney in cancer patients is 7-13% in large autopsy series,⁷ even though it is a much rarer event in clinical practice.

Kidney metastases in mCRC may be generally associated with an unfavorable prognosis, partly due to the accelerated metastatic spread via hematogeneous pathway from the kidney.⁸ Thus, patients with metastatic CRC and kidney tumors are a diagnostic and therapeutic chal-

Correspondence: Rodrigo Kraft Rovere, Department of Oncology, Santo Antonio Hospital, postal code 89015-200, Blumenau, Santa Catarina Brazil. Tel. +55.47.3231.4000
E-mail: rodrigorovere@hotmail.com

Key words: colorectal cancer, metastasis to the kidney, second primary tumor.

Received for publication: 18 September 2011.

Accepted for publication: 12 October 2011.

This work is licensed under a Creative Commons Attribution NonCommercial 3.0 License (CC BY-NC 3.0).

©Copyright C. Dagnoni et al., 2011
Licensee PAGEPress, Italy
Clinics and Practice 2011; 1:e88
doi:10.4081/cp.2011.e88

lenge. Biopsy of the kidney tumor should be performed in patients in good condition with a limited extent of CRC metastases responsive to therapy to distinguish between CRC renal metastasis and secondary primary RCC, since therapeutic decisions can be different.²

Though surgical resection is the only effective treatment for localized RCC, in some circumstances resection may be used for metastatic disease.⁹

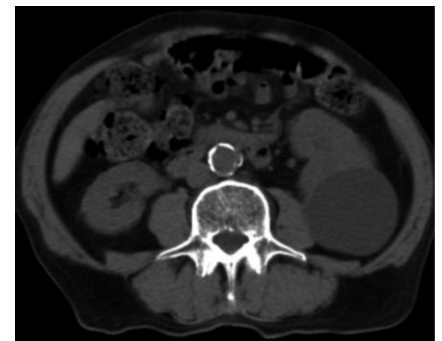

Figure 1. Abdominal computed tomography showing a heterogeneous lesion in the upper pole of the right kidney, measuring 4.2×3.9 cm.

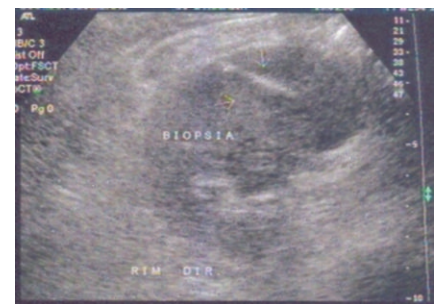

Figure 2. Tumor puncture guided by ultrasound.

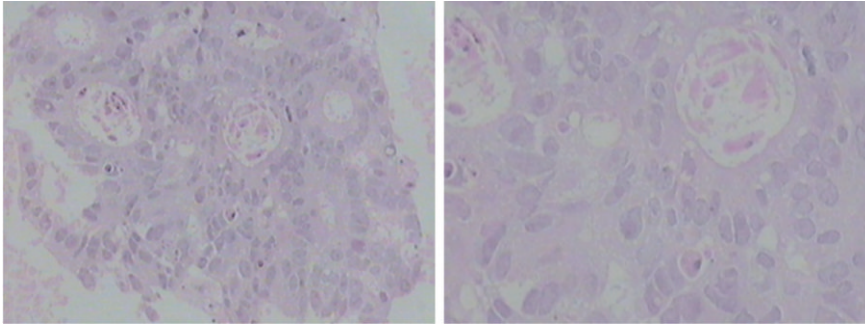


Figure 3. Histological examination of the kidney biopsy diagnosed tubular adenocarcinoma infiltrative glandular proliferation, representing a sigmoid cancer metastasis.

Selected patients with metastatic CRC and secondary primary RCC, taking into account the prognosis of the metastatic tumor, the patient's performance status and the presence of co morbidities, may benefit from nephrectomy. Except for these rare cases, nephrectomy has no role in the management of CRC renal metastases.² Indeed, nephrectomy may compromise the choice of chemotherapy agents that require renal clearance.⁵

Therefore, systemic chemotherapy remains the treatment of choice for CRC renal metastases. In case of inconclusive biopsy results,

management should be based on radiological and clinical findings.²

References

1. Kuebler JP, Wieand HS, O'Connell MJ, et al. Oxaliplatin combined with weekly bolus fluorouracil and leucovorin as surgical adjuvant chemotherapy for stage II and III colon cancer: results from NSABP C-07. *J Clin Oncol* 2007;25:2198-204.

2. Melichar B, Moravek P, Ferko A, Podhola M. Metastatic colorectal carcinoma and kidney tumors: a report of four cases. *Tumori* 2010;96:483-6.
3. Rabbani F, Reuter VE, Katz J, Russo P. Second primary malignancies associated with renal cell carcinoma: influence of histologic type. *Urology* 2000;56:399-403.
4. Beisland C, Talleraas O, Bakke A, Norstein J. Multiple primary malignancies in patients with renal cell carcinoma: a national population-based cohort study. *BJU Int* 2006;97:698-702.
5. Aksu G, Fayda M, Sakar B, Kapran Y. Colon cancer with isolated metastasis to the kidney at the time of initial diagnosis. *Int J Gastrointest Cancer* 2003;34:73-7.
6. Julianov A, Stoyanov H, Karashmalakov A. Late renal metastasis from sigmoid adenocarcinoma. *Lancet Oncol* 2004;5:726.
7. Bracken RB, Chica G, Johnson DE, Luna M. Secondary renal neoplasms: an autopsy study. *South Med J* 1979;72:806-7.
8. Kibar Y, Deveci S, Sumer F, Seckin B. Renal papillae metastasis of sigmoid colon adenocarcinoma. *Int J Urol* 2005;12:93-5.
9. Curti BD. Renal cell carcinoma. *JAMA* 2004;292:97-100.