



Contents lists available at ScienceDirect

International Journal of Surgery Case Reports

journal homepage: www.casereports.com

Rare case of transverse testicular ectopia – Case report and review of literature



Vinod Raj, Rajeev Gurunath Redkar*, Swathi Krishna, Shruti Tewari

Lilavati Hospital & Research Centre, India

ARTICLE INFO

Article history:

Received 16 June 2017

Received in revised form 9 September 2017

Accepted 10 September 2017

Available online 7 November 2017

Keywords:

Transverse testicular ectopia

Case report

Persistent mullerian duct syndrome

Laparoscopy

Trans-septal orchidopexy and trans-septal contralateral orchidopexy

ABSTRACT

This case report has been reported in line with the SCARE criteria; Consensus-based surgical case report guidelines of International Journal of Surgery 2016.

INTRODUCTION: Transverse Testicular Ectopia (TTE) is a rare condition which manifests with unilateral undescended testis and contralateral hernia. Till now around 100 cases have been described in the literature. The management depends on the anatomy of the vas, vessels and testis found on surgical exploration. An algorithm exists for its management and we propose a modified algorithm for management of TTE. **CASE PRESENTATION:** Five year male presented with complaints of unilateral undescended testis on the right and hernia on the left. Clinically the right testis was impalpable and left testis palpable in the left hemiscrotum and fluid hernia on the same side.

DISCUSSION: Transverse testicular ectopia is a rare condition presenting with UDT and contralateral inguinal hernia. Although more than 100 cases have been described in the literature so far, those managed with a transeptal contralateral orchidopexy are two cases to the best of our knowledge. TTE was first described by Von Lenhossek in 1886. The mean age of presentation is around 4 years and most of the cases are diagnosed on surgical exploration. The management of TTE remains controversial even though an algorithm has been described for its management due to its varied presenting scenarios.

CONCLUSION: TTE is a rare condition which requires high index of suspicion for diagnosis preoperatively. Whenever suspected we recommend an USG and/or MRI prior to diagnostic laparoscopy and proceed with orchidopexy. Diagnostic laparoscopy is both helpful in diagnosis and management. Transeptal contralateral orchidopexy gives good tension free fixation of testes in the scrotum.

© 2017 Published by Elsevier Ltd on behalf of IJS Publishing Group Ltd. This is an open access article under the CC BY-NC-ND license (<http://creativecommons.org/licenses/by-nc-nd/4.0/>).

1. Case report

Five year old male presented to us at a tertiary care hospital with complaints of unilateral undescended testis on the right side with an inguinal hernia on the left side. Clinically, the right testis was impalpable and left testis palpable in the left hemiscrotum with fluid hernia on the same side (Fig. 1, left side marked by yellow arrow and right side by red arrow in all figures). The patient had an ultrasound of the abdomen which showed both the testes on the left side with fluid hernia also on the left side (Fig. 2a). To confirm this finding, the patient underwent a MRI which reported an oval structure above the right deep inguinal ring which represents atrophic testis (Fig. 2b).

Abbreviations: TTE, Transverse testicular ectopia; UDT, Undescended testis; USG, Ultrasonography; MRI, Magnetic resonance imaging; PMDS, Persistent Mullerian duct syndrome; DSD, Disorder of sexual differentiation.

* Corresponding author.

E-mail addresses: doc.vraj89@gmail.com (V. Raj), rajeev.redkar@gmail.com (R.G. Redkar), swathichigicherla@gmail.com, swati9.chigicherla@gmail.com (S. Krishna), Shruti.t18@gmail.com (S. Tewari).

<https://doi.org/10.1016/j.ijscr.2017.09.032>

2210-2612/© 2017 Published by Elsevier Ltd on behalf of IJS Publishing Group Ltd. This is an open access article under the CC BY-NC-ND license (<http://creativecommons.org/licenses/by-nc-nd/4.0/>).

Due to the conflicting reports, it was decided to define the anatomy better with a diagnostic laparoscopy which showed closed internal ring on the right side, a wide open internal ring on the left side, and two sets of vas and vessels entering the ring, the right sided vas and vessels seen crossing the midline onto the left side and testis seen in the canal while another testis was palpable clinically in the left hemiscrotum (Fig. 3a,b and c). There were no Mullerian remnants present in the abdomen.

This was followed by a left inguinal exploration with dissection and ligation of peritoneal sac and separation of both the testes with their vas and vessels (Fig. 4). Adequate cord length could not be achieved for the right testis to reach the right hemiscrotum hence we performed a trans-septal contralateral orchidopexy fixing the right testis in the left hemiscrotum with vas laterally vessels medially and testicular sinus anteromedially and left testis vice – versa (Fig. 5). This case report has been reported in line with the SCARE criteria published in International Journal of Surgery 2016



Fig. 1. Clinical photograph pre operative.

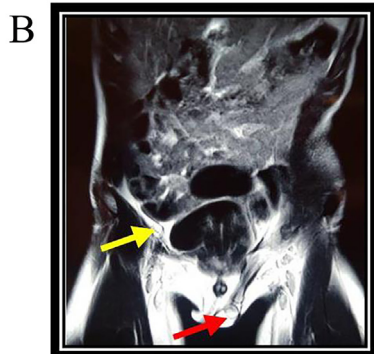
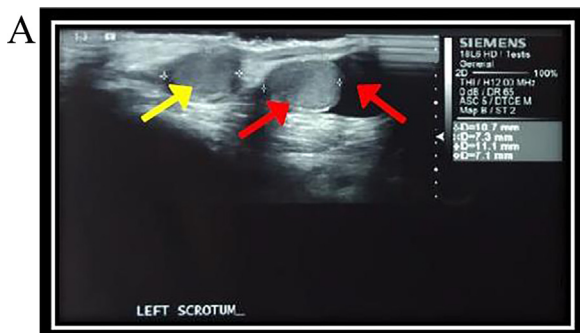


Fig. 2. (a) Ultrasonography (b) Magnetic resonance image.

2. Discussion

Transverse testicular ectopia is a rare condition presenting with UDT and contralateral inguinal hernia. Although more than 100 cases have been described in the literature so far [1], those managed with a trans-septal contralateral orchidopexy are two cases to the best of our knowledge [2,3].

TTE was first described by Von Lenhossek in 1886 [4]. The mean age of presentation is around 4 years [5] and most of the cases are diagnosed on surgical exploration [6]. In fact, those diagnosed preoperatively are either diagnosed by USG or MRI [7] and clinical

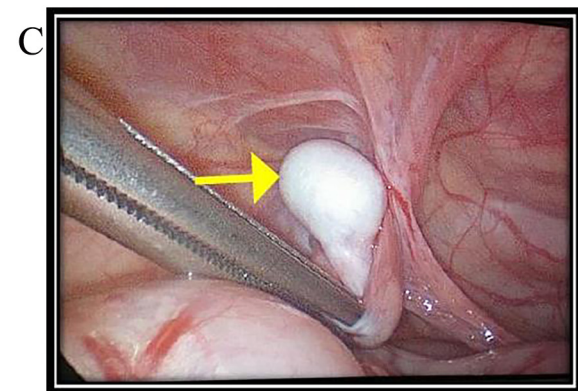
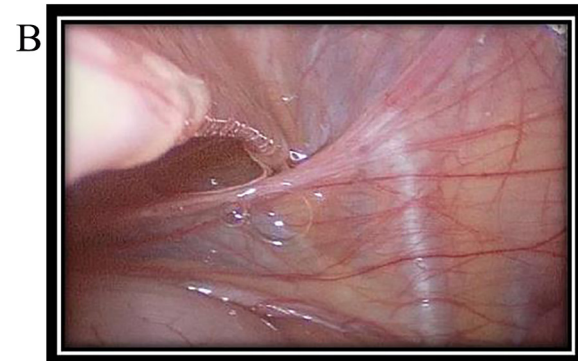
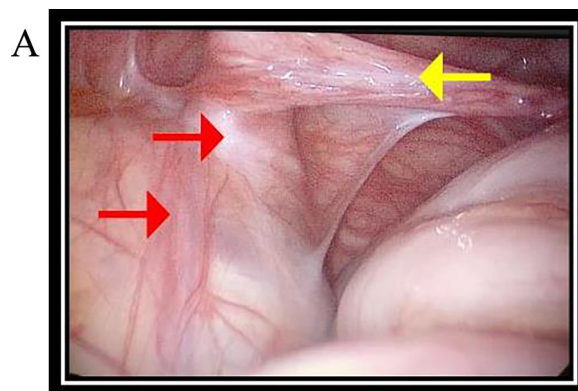


Fig. 3. Diagnostic laparoscopy findings.

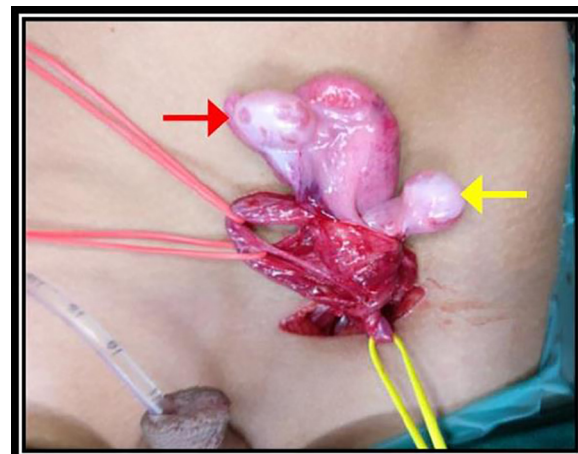


Fig. 4. Inguinal exploration.

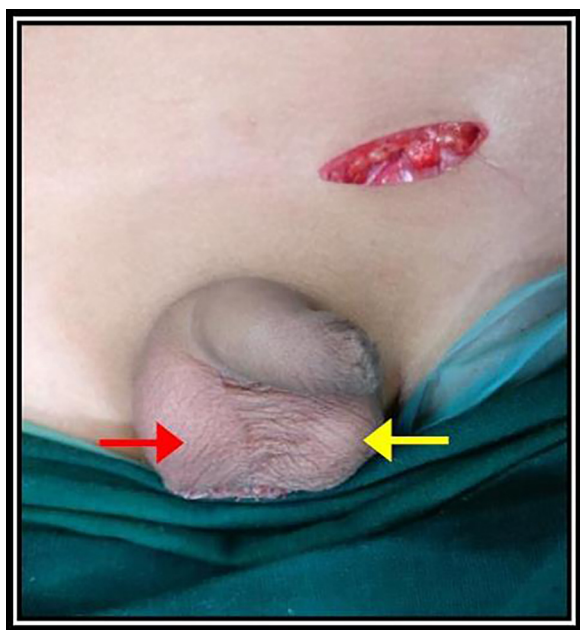


Fig. 5. Clinical photograph post operative.

diagnosis is possible only when both the testes are palpable on the same side with an empty scrotum on the opposite side.

There are various theories postulated in an attempt to explain its etiology. Berg thought that the two testes arise from the same germinal ridge [8]. Josso suggested various anatomical factors that may result in such an anomaly: defective implantation of the gubernaculum, obstruction of the inguinal ring and development of adhesions between the testes and adjacent structures [9]. Gupta and Das postulated that adherence and fusion of the developing Wolffian ducts took place early, and that descent of one testis caused the second one to follow [10]. Paltii suggested a defective implantation of the gubernaculum testis or an obstruction of the inguinal ring preventing testicular descent on the ipsilateral side [11]. Several animal models have been studied to explain the etiology and Clar-nette postulated that distal gubernaculotomy in rat could prevent development of the processus vaginalis because of mechanical dis-

ruption [12] while Frey and Rajfer noted that defective ipsilateral gubernacular development might predispose to TTE in their rat model [13].

Although many theories have been postulated, no single theory can explain the etiology and its variations and associated syndromes. Kimura believed that if both vasa deferentia arose from one side, there had been unilateral origin but if there was bilateral origin, one testis had crossed over [14]. This theory explains the fused single vas deference but fails to explain the propensity for migration towards either side. Thevasthan who ascribed TTE to the testes both lying in the same saccus vaginalis before descent. This occurs if the testes or vasa deferentia are bound together or if the vasa are bound to Mullerian structures [15]. This theory explains the persistent Mullerian structures associated with TTE.

On the basis of the presence of various associated anomalies, TTE has been classified into 3 types [5]: Type 1, accompanied only by hernia (40% to 50%); type 2, accompanied by persistent or rudimentary Mullerian duct structures (30%); and type 3, associated with disorders other than persistent Mullerian remnants (inguinal hernia, hypospadias, disorders of sexual differentiation and scrotal abnormalities) (20%).

Persistent Mullerian duct syndrome (PMDS) is a rare form of male DSD characterized by the presence of uterus or Fallopian tubes in phenotypically normal 46 XY males [16]. TTE associated with PMDS is a rare syndrome and it was first described by Jordan in 1895 [17]. The condition is caused by an insufficient amount of anti-Mullerian hormone which is released from Sertoli's cells in testes or by insensitivity of the target organ to this hormone [18]. Whenever PMDS is suspected on USG or MRI, it has to be confirmed with a diagnostic laparoscopy, testicular biopsy and chromosomal studies [19].

Patients with TTE are at increased risk of malignant transformation. In fact, the overall incidence of malignant transformation of gonads is 18% which is slightly higher than UDT [19]. There have been reports of embryonal carcinoma, seminoma, yolk sac tumor and teratoma [20]. There are not many reports of malignancy arising from the Mullerian remnants so there is currently no indication for need to remove the remnants which may injure the vas and blood supply to testes [18].

The management of TTE remains controversial even though an algorithm has been described for its management [21] due

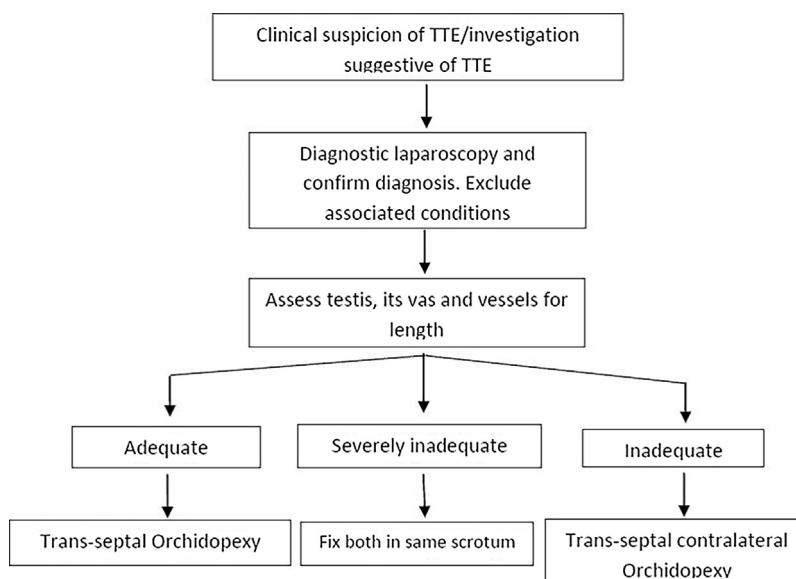


Fig. 6. Algorithm for management of transverse testicular ectopia.

to its varied presenting scenarios. The available options include inguinal exploration and orchidopexy, diagnostic laparoscopy and orchidopexy, diagnostic laparoscopy and trans-septal orchidopexy, diagnostic laparoscopy and trans-septal contralateral orchidopexy [22]. The laparoscopy-assisted orchidopexy was reported by Dean and Shah [23] while Balaji and Diamond first reported a case of TTE that was both diagnosed and treated by laparoscopy [24]. But the finding on exploration dictates the management and should be based on each case finding. An algorithm has also been postulated for management of TTE which was given by Bascuna et al. [21] which performs extensive dissection in order to gain length on vas and vessels. We propose a modification of their algorithm (Fig. 6) and propose not to perform extensive dissection in order to gain length because of the intricate blood supply which may be shared between the testes and their vas, and instead perform both orchidopexy on the same side if trans-septal orchidopexy is not possible.

This case report has been published in line with the SCARE criteria published in International Journal of Surgery in 2016[25].

3. Conclusion

TTE is a rare condition which requires high index of suspicion for diagnosis preoperatively. Whenever suspected we recommend an USG and/or MRI prior to diagnostic laparoscopy and proceed with orchidopexy. Diagnostic laparoscopy is both helpful in diagnosis and management. Transeptal contralateral orchidopexy gives good tension free fixation of testes in the scrotum.

Conflict of interest

None.

Funding

None.

Ethical approval

Not applicable

Consent

A written informed consent has been obtained from the patient for publication of this case report and accompanying image. Copy will be made available at request.

Author contribution

Study concept and interpretation – Dr Rajeev Redkar.
Writing paper – Dr Vinod Raj.

Paper editing and picture credits – Dr Swathi Krishna, Dr Shruti Tewari.

Guarantor

Dr Rajeev Redkar.

References

- [1] S. Naouar, K. Maazoun, L. Sahnoun, R. Jouini, A. Ksia, O. Elezzi, et al., Transverse Testicular Ectopia: A Three-Case Report and Review of the Literature, *Urology* 71 (6) (2008) 1070–1073.
- [2] E. Divarçı, I. Ulman, A. Avanoglu, Transverse testicular ectopia treated by transeptal contralateral transposition: case report, *Eur. J. Pediatr. Surg.* 21 (03) (2011) 191–192.
- [3] S. Salah, K. Elhaj, Y. Awadelseed, S. Mohammed, Crossed testicular ectopia, *Ann. Pediatr. Surg.* 12 (4) (2016) 170–172.
- [4] M.N. Von Lenhossek, Ectopia testis transversa, *Anta Anz* 1 (2017) 376–381 (1886).
- [5] M.W. Gauderer, E.R. Grisoni, T.A. Stellato, et al., Transverse testicular ectopia, *J. Pediatr. Surg.* 17 (1982) 43–47.
- [6] K.C. Chen, C.C. Chu, T.Y. Chou, Transverse testicular ectopia: preoperative diagnosis by ultrasonography, *Pediatr. Surg. Int.* 16 (1–2) (2000) 77–79.
- [7] W.W. Lam, S.D. Le, K.L. Chan, et al., Transverse testicular ectopia detected by MR imaging and MR venography, *Pediatr. Radiol.* 32 (2002) 126–129.
- [8] A.A. Berg, Transverse ectopy of the testis, *Ann. Surg.* 40 (1904) 223–224.
- [9] N. Josso, Development and descent of the fetal testis, in: J.L. Bierich, K. Rager, M.B. Ranke (Eds.), *Maldescensus Testis*, Urban and Schwarzenberg, Munich, 1977, pp. 1–3.
- [10] R.L. Gupta, P. Das, Ectopia testis transversa, *J. Indian Med. Assoc.* 34 (1960) 547–549.
- [11] N.P. Platii, Transverzala naia iktopii laichka, *Urol. Nefrol. (Mosk)* 30 (1965) 63.
- [12] T.D. Clarnette, J.M. Hutson, S.W. Beasley, Factors affectin the development of the processus vaginalis in the rat, *J. Urol.* 156 (1996) 1463–1466.
- [13] H.L. Frey, J. Rajfer, Role of the gubernaculum and intraabdominal pressure in the process of testicular descent, *J. Urol.* 131 (1984) 574–579.
- [14] T. Kimura, Transverse ectopy of the testis with masculine uterus, *Ann. Surg.* 68 (1981) 420–425.
- [15] C.D. Thevasthan, Transverse ectopia of the testis, *Aust. N. Z. J. Surg.* 37 (1967) 93–102.
- [16] I. Karnak, F.C. Tanyel, Z. Akcoren, et al., Transverse testicular ectopia with persistent Müllerian duct syndrome, *J. Pediatr. Surg.* 32 (1997) 1362–1364.
- [17] M. Jordan, Ein fall von einseitigem descensus testicularum, *Beitrage Klinische Chirurgie* 15 (1895) 245.
- [18] M.F. Acikalin, O. Pasaoglu, B. Tokar, et al., Persistent Müllerian duc syndrome with transverse testicular ectopia: a case report with literature review, *Turk J. Med. Sci.* 34 (2004) 333–336.
- [19] F. Berkmen, Persistent Müllerian duct syndrome with or without transverse testicular ectopia and testis tumors, *Br. J. Urol.* 79 (1997) 122–126.
- [20] J.A. Eastham, K. McEvoyk, R. Sullivan, et al., A case of simultaneous bilateral nonseminomatous testicular tumors in persistent Müllerian duct syndrome, *J. Urol.* 148 (1992) 407–408.
- [21] R. Bascuna, J. Ha, Y. Lee, H. Lee, Y. Im, S. Han, Transverse testis ectopia: diagnostic and management algorithm, *Int. J. Urol.* 22 (3) (2015) 330–331.
- [22] A.V. Deshpande, E.R. La Hei, Impact of laparoscopy on the management of transverse testicular ectopia, *J. Laparoendosc. Adv. Surg. Tech. A* 19 (3) (2009) 443–444.
- [23] G.E. Dean, S.K. Shah, Laparoscopically assisted correction of transverse testicular ectopia, *J. Urol.* 167 (2002) 1817–1819.
- [24] K.C. Balaji, D.A. Diamond, Laparoscopic diagnosis and management of transverse testicular ectopia, *Urology* 46 (1995) 879–880.
- [25] R.A. Agha, A.J. Fowler, A. Saetta, I. Barai, S. Rajmohan, D.P. Orgill, SCARE Group, The SCARE statement: consensus-based surgical case report guidelines, *Int. J. Surg.* 34 (2016) 180–186.

Open Access

This article is published Open Access at [sciencedirect.com](https://www.sciencedirect.com). It is distributed under the [IJSCR Supplemental terms and conditions](#), which permits unrestricted non commercial use, distribution, and reproduction in any medium, provided the original authors and source are credited.