

# Clinical and electrodiagnostic findings in cyhalothrine poisoning

Keivan Basiri, Mohammad Reza Mohaghegh, Somayyeh Sadat Teimouri, Ali Asghar Okhovat<sup>1</sup>

Department of Neurology, Isfahan Neurosciences Research Center, Isfahan University of Medical Sciences, Isfahan,

<sup>1</sup>Department of Neurology, Kashani Hospital, Shahre-Kord University of Medical Sciences, Shahre-Kord, Iran

## Abstract

Acute onset bulbar symptoms with respiratory failure and descending paralysis may occur in several neuromuscular disorders including variants of Guillain-Barre syndrome (GBS), diphtheria, botulism and toxins. We present a 51-year-old man who presented with complains of ptosis and dyspnea following pyrethroids spraying in an enclosed area for eradication of flea. Within 5-6 days of admission limb weakness, dysphagia, dysarthria, blurred vision, diplopia, tremor and respiratory distress added to previous symptoms. Temporal profile of events after exposure, development of similar symptoms in patient's son, electrodiagnostic findings and exclusion of other etiologies confirms intoxication etiology. We reviewed the literature and provide an extensive electrodiagnostic overview.

**Key Words:** Cyhalothrin, electrodiagnosis, polyneuropathy, pyrethroids

## Address for correspondence:

Prof. Keivan Basiri, Medical School, Isfahan Neurosciences Research Center, Isfahan University of Medical Sciences, Alzahra Hospital, Sofe Ave, Isfahan, Iran.

E-mail: basiri@med.mui.ac.ir

Received: 09.02.2014, Accepted: 08.06.2014

## INTRODUCTION

Pyrethroids are a group of insecticides commonly used for eradication of insects. Different subtypes include Permethrin, Deltamethrin and Cyhalothrin and among others. These substances are used in creams, solution and other topical forms for treatment of scabies. Exposure to this agents may result in intoxication and urinary levels of their metabolite correlate to indoor residential insecticide levels.<sup>[1]</sup>

Polyneuropathies are a group of lower motor neuron disorders characterized with parasthesia,

burnings, tinglings, muscle weakness and wasting, and rarely cranial nerve palsy. Onset may be acute, subacute or chronic and etiology vary from an acute toxic or inflammatory to chronic hereditary forms. Pattern of disease onset, being symmetric or asymmetric, having sensory, motor or mix complaints in history and electrodiagnostic findings (axonal or demyelinating/sensory, motor or mixed) help in etiologic classification of polyneuropathy. Inflammatory neuropathies, diphtheria, porphyry and toxins could present with acute generalized weakness. Herein we report a case of acute onset polyneuropathy due to cyhalothrin poisoning and review the literature.

## CASE REPORT

A 51-year-old man presented with recurrent cough following pyrethroids spraying in an enclosed area for eradication of flea. Twenty four hours after the beginning of symptoms he admitted in first medical center and partially treated for 2 days with impression of respiratory poisoning. He discharged seemingly

Access this article online	
Quick Response Code:	Website: www.advbiores.net
	DOI: 10.4103/2277-9175.178793

Copyright: © 2016 Basiri. This is an open-access article distributed under the terms of the Creative Commons Attribution License, which permits unrestricted use, distribution, and reproduction in any medium, provided the original author and source are credited.

**How to cite this article:** Basiri K, Mohaghegh MR, Teimouri SS, Okhovat AA. Clinical and electrodiagnostic findings in cyhalothrine poisoning. Adv Biomed Res 2016;5:32.

healthy, so that he could walk and breathe normally at the time of discharge. The same night symptoms recurred and he referred to second medical center and admitted for one and a half day and underwent indeterminate treatment. Four days after beginning of symptoms the patient referred to our tertiary university hospital with complaints of ptosis and dyspnea. Within 5-6 days of admission limb weakness, dysphagia, dysarthria, blurred vision, diplopia, tremor and respiratory distress added to previous symptoms. The patient was admitted to the ICU, intubated and mechanical ventilated. There was no history of diarrhea or respiratory infection in preceding 4 weeks.

In first physical examination the Blood pressure was 110/80, Temperature = 37.4, Respiratory rate = 16, Pulse rate = 80. He was conscious aware, obey and oriented. The pupils were of normal size and reactive. There was no evidence of gaze preference and nistagmus. The ophthalmoscopic examination was normal. Cranial nerves were intact and no gaze palsy was detected. In sensory examination, there was no stocking and gloving sensory loss and no sensory level. The position and vibration sensation was intact. In motor exam, there was no hypotonia or spasticity and rigidity, without any evidences of abnormal movements.

Deep tendon reflexes were 2+/and symmetric in upper and lower limbs and a reduced manual muscle force of 4/5 on the Medical Research Council (MRC) grading was detected symmetrically in upper limbs.

Electrocardiogram, chest X-ray and brain MRI were normal. No botulinium neurotoxin was detected in serum or feces. Lumbar puncture revealed normal CSF analysis without cytoalbuminemic dissociation.

In first electrodiagnostic study (EDX), 13 days after admission, distal motor latency (DML) of bilateral median and ulnar nerves was mildly prolonged in axonal range [Table 1]. Other parameters of motor nerve conduction studies (NCS) and F-wave latencies were within normal limits. Examination terminated prematurely due to sudden deterioration of respiratory function and hemodynamic status of the patient during EDX study. In the second study, 10 days later, compound muscle action potential (CMAP) amplitude was reduced in upper limbs in comparison to the first study [Table 2]. Distal sensory latency (DSL) was prolonged in bilateral median and ulnar nerves [Table 3]. In repetitive nerve stimulation (RNS), 10.4% decremental response in Nasalis muscle and up to 34.1% decremental response in abductor digiti minimi (ADM) were detected [Tables 4 and 5]. After exercise for 10 seconds

post activation facilitation was seen in the ADM muscle [Table 4]. In needle electromyography (EMG), reduced recruitment of normal-shaped motor unit action potentials (MUAPs) and fibrillations and positive sharp waves in facial and upper limb muscles were detected [Figure 1]. Slight polyphasia in deltoid was unremarkable.

We followed the patient conservatively without any immunomodulation: Keeping the patient in ICU

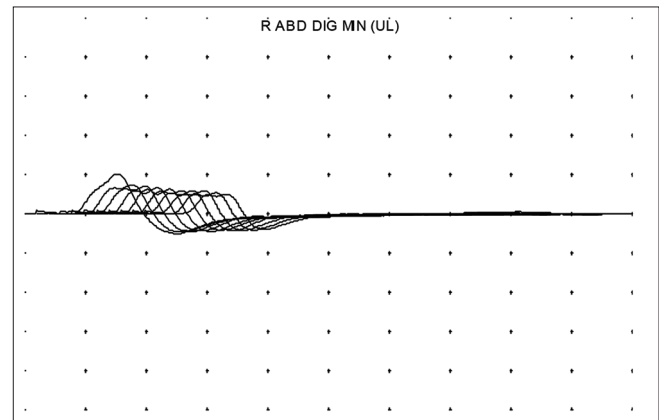


Figure 1: Decremental response in RNS of right ADM muscle

Table 1: Motor nerve conduction studies (NCS) 13 days after beginning of symptoms

Nerve/sites	Latency ms	Ampl mV	Distance cm	Velocity m/s
R median- APB				
1. Wrist	4.65	9.6		
2. Elbow	9.25	9.2	24	52.2
L median- APB				
1. Wrist	5.10	9.7		
2. Elbow	8.85	9.4	20	53.3
R ulnar- ADM				
1. Wrist	3.50	7.1		
2. B. Elbow	6.00	7.4	15	60.0
L ulnar- ADM				
1. Wrist	3.55	6.9		
2. B. Elbow	5.05	7.9	11	73.3
R commperoneal- EDB				
1. Ankle	4.80	1.6		
2. Fib head	11.15	1.3	30	47.2
L commperoneal- EDB				
1. Ankle	5.15	2.3		
2. Fib head	11.70	1.8	30	45.8
R tibial (knee) - AH				
1. Ankle	5.45	4.2		
2. Knee	14.50	3.3	36	39.8
L tibial (knee) - AH				
1. Ankle	5.75	2.8		
2. Knee	14.55	2.0	38	43.2

ADM: Abductor digiti minimi, EDB: Extensor digitorum brevis, APB: Abductor pollicis brevis, AH: Adductor hallucis

**Table 2: Motor NCS, 23 days after beginning of symptoms**

Nerve/sites	Latency ms	Ampl mV	Distance cm	Velocity m/s
R median- APB				
1. Wrist	4.20	6.2		
2. Elbow	8.70	6.0	21	46.7
L median- APB				
1. Wrist	4.50	6.6		
2. Elbow	8.15	5.9	22	60.3
R ulnar- ADM				
1. Wrist	3.45	2.9		
2. B.Elbow	7.70	2.6	18	42.4
L ulnar- ADM				
1. Wrist	3.75	5.2		
2. B.Elbow	5.95	4.4	17	77.3
R comperoneal- EDB				
1. Ankle	5.35	1.5		
2. Fib head	12.65	1.1	36	49.3
L comperoneal- EDB				
1. Ankle	5.20	2.0		
2. Fib Head	12.40	2.0	37	51.4
R tibial (knee) - AH				
1. Ankle	4.45	4.2		
2. Knee	14.75	2.2	42	40.8
L tibial (knee) - AH				
1. Ankle	4.80	2.9		
2. Knee	14.00	2.9	47	51.1

ADM: Abductor digiti minimi, EDB: Extensor digitorum brevis, APB: Abductor pollicis brevis, AH: Adductor hallucis

**Table 3: Sensory NCS**

Nerve/sites	Rec. site	P latency Ms	Pk Amp $\mu$ V	Area $\mu$ V ms	Duration Ms
R median- Digit II					
1. Wrist	II	4.00	23.8	25.9	1.65
L median- Digit II					
1. Wrist	II	3.75	30.5	23.1	1.65
R ulnar- Digit V					
1. Wrist	V	3.50	22.3	21.5	2.40
L ulnar- Digit V					
1. Wrist	V	3.25	23.1	14.7	1.35
R sural-lat malleolus					
1. Calf	Latmalleolus	3.15	14.8	6.8	1.35
L sural-lat malleolus					
1. Calf	Latmalleolus	3.15	9.4	6.5	1.35

intubated and mechanically ventilated, checking CBC, electrolytes and liver enzymes, controlling intake and output, feeding with nasogastric tube and DVT and bedsores prophylaxis. After the first week of ICU admission, condition of the patient improved but respiratory failure persists. During the first month several attempts of weaning was unsuccessful and the patient confined again on mechanical ventilation due to recurrence of respiratory distress. After 3 months he completely recovered without use of any antidote, plasma exchange or IVIG and discharged in good

general health. In follow-up visits after 6, 12 and 24 months the patient was strong and healthy without any residual weakness. The 23-year-old patient's son developed milder but similar symptoms of ptosis and dyspnea that remitted after 2 weeks without any hospitalization.

## DISCUSSION

Acute onset bulbar symptoms with respiratory failure and descending paralysis, as in our patient, may occur in several neuromuscular disorders including variants of Guillain-Barre syndrome (GBS), diphtheria, botulism and toxins.<sup>[2-5]</sup> Familial occurrence, EDX findings and lack of cytoalbuminemic dissociation in CSF are against the diagnosis of GBS. The absence of demyelinating features in EDX and lack of previous history of pharyngitis exclude diagnosis of diphtheria. There was no history of consuming contaminated food, no mydriasis or bradycardia was detected, and botulinum neurotoxin was absent in serum and feces. Temporal profile of events after exposure and development of similar symptoms in patient's son are in favor of intoxication etiology. The patient used about 20 liters of cyhalothrin for eradication of flea and soaked his blanket with toxin and slept with the same blanket that may explain rapidity of onset and severity of symptoms in comparison to other reports. His son with much lower exposure only developed transitory symptoms without hospitalization.

Intoxication with insecticide/pesticide was a health problem from many years ago. It may happen accidentally or voluntarily for suicide purpose. Suicide with organophosphate compounds is about one quarter of all suicidal attempts.<sup>[6]</sup> It happens all over the world, less prevalent in the west due to declining availability of organophosphate insecticide.<sup>[7]</sup> Pesticide/insecticide could affect all age groups, in case reports from a 19-month-old girl<sup>[8]</sup> to adults.

The most familiar agents are organophosphate compounds, but Abamectin, Carbamat, Avemectin, Chwastox and finally Pyrethroid intoxication are reported in the literature. In organophosphate intoxication some related and defined clinical manifestation like motor neuropathy, mixed sensory motor polyneuropathy and myelopathy have been reported,<sup>[9,10]</sup> but there is no uniform description of signs and symptoms in other pesticide. Most of the authors reported neurologic manifestation of organophosphate compounds as a delayed sensory motor polyneuropathy<sup>[11]</sup> and rarely pure motor and rapidly evolving myelopathy. In a study in India, Guillain-Barre like syndrome is seen in intoxication with organophosphate poisoning. In this case

**Table 4: Repetitive nerve stimulation (RNS)**

Muscle/train	Ampl. mV	d. Ampl 1-4 %	d. Ampl 4-10 %	Fac Ampl %	Area mV ms	d. Area 1-4 %	d. Area 4-10 %	Fac area %	Rate pps	Time
R ABD poll brevis										
Baseline	5.2	-7.3	-9.9	100	19.8	-11.6	-15.6	100	3	0:00:00
R ABD dig min (UL)										
Baseline	6.6	-25.5	-77.1	100	16.3	-15	-69.4	100	3	0:00:00
R ABD dig min (UL)										
Baseline	6.2	-28.7	-32.3	100	19.8	-20	-29.8	100	3	0:00:00
Facilitation	1.2	15.5	-28.7	19.2	3.7	21.8	-43	18.8	3	0:00:13
R ABD dig min (UL)										
Baseline	6.0	-23.6	-31.4	100	19.4	-15.8	-24.2	100	3	0:00:00
R ABD dig min (UL)										
Baseline	5.1	-34.1	-52.5	100	16.4	-29	-48.2	100	3	0:00:00
L ABD dig min (UL)										
Baseline	4.3	-7.5	-11.1	100	12.8	-18.3	-24	100	3	0:00:00
R nasalis										
Baseline	0.3	-10.4	-11	100	1.1	-13.6	-13.7	100	3	0:00:00

ABD: Abductor

**Table 5: Needle electromyography (EMG)**

	EMG summary table								
	Spontaneous activity					MUAP			Recruitment
	IA	Fib	PSW	Fasc	H.F.	Amp	Dur.	PPP	Pattern
R. Tib anterior	N	None	None	None	None	N	N	N	N
L. Gastrocn (med)	N	None	None	None	None	N	N	N	N
R. First D inteross	N	2+	2+	None	None	N	N	N	Reduced
R. Biceps	N	2+	2+	None	None	N	N	N	Reduced
L. First D inteross	N	1+	2+	None	None	N	N	N	Reduced
R. Trapezius (U)	N	3+	3+	None	None	N	N	N	Discrete
R. Deltoid	N	2+	3+	None	None	N	N	1+	Discrete
R. Frontalis	N	4+	3+	None	None	N	N	N	Discrete

EMG: Electromyography, MUAP: Motor unit action potentials, PSW: Positive sharp wave, IA: Insertional activity, PPP: Poly phasic pattern, N: Normal

neuropsychiatric disorders are defined as a chronic manifestation of this poison.<sup>[12]</sup> Our case presented with similar rapidity in onset, but was unusual because of prominent and early bulbar symptoms. In some severe cases atypical symptoms has been reported. For example in a 19-month-old infant that was admitted with tonic-clonic seizure, chorea, athetosis, tremor and coma (GCS = 6) intoxication with organophosphate agents has been detected.<sup>[8]</sup> In another report ataxia, mild ptosis and dilated pupils were detected in Abamectin intoxication.<sup>[13]</sup> In another one delayed polyneuropathy and cortical blindness are mentioned in relation with Carbamate intoxication.<sup>[14]</sup> Sung *et al.* described a case of acute Avermectin intoxication who presented with coma, myoclonus and polyneuropathy.<sup>[15]</sup> In a surprising study in mice, Canin ABCB1 gene mutation shows a

genetic transformation that results in more sensitivity to Ivermectin exposure.<sup>[16]</sup> There is a controversy about carbamate (A reversible inhibitor of acetylcholine esterase) and polyneuropathy. In an article three cases of polyneuropathy after severe poisoning by methyl-carbamates is discussed.<sup>[17]</sup> Jayawardane *et al.* described decremental pattern of RNS with organophosphate poisoning as in our patient. They explained a correlation between severity and progression of disease and electrodiagnostic findings.<sup>[18]</sup> In our case decremental response of 10.4% in facial and up to 34.1% in upper limb muscles was detected that correlate with neuromuscular junction defect. In addition, reduced CMAP amplitude and reduced recruitment and denervation potentials in facial and upper limb muscles was detected that indicate axonal damage. In previous reports of pyrethroid intoxication symptoms like mental decline, tinnitus, sensory motor polyneuropathy especially in lower limbs, paroxysmal tachycardia, visual disturbance and orthostatic hypotonia have been described but no EDX finding is reported.

Goel *et al.* demonstrate interesting MRI changes in striatum of a patient with extrapyramidal syndrome after organophosphate poisoning.<sup>[19]</sup>

Another report describes provocation of auto immune disorders such as scleroderma like syndrome, myasthenia like syndrome, autoimmune hemolysis and auto immune thrombocytopenic purpura 2 years following Pyrethroid intoxication.<sup>[20]</sup> In still another report of pyrethroid intoxication a combination of central, peripheral, autoimmune and immunological disturbances has been described.<sup>[21]</sup>

Teratogenic complications of Pyrethroid intoxication are mild and limited to craniofacial abnormality and pericardial edema just in high dose of intoxication.<sup>[22]</sup> Treatment is supportive and there is no special antidote. In an article, plasmapheresis is suggested for treatment of Chwastox herbicide intoxication, what we never see in other research works.<sup>[23]</sup>

## CONCLUSION

Pyrethroid intoxication could result in a combination of neuromuscular junction defect and polyneuropathy with a dose-dependent severity. Treatment with appropriate supportive care would result in complete recovery.

## REFERENCES

1. Trunnelle KJ, Bennett DH, Tulve NS, Clifton MS, Davis MD, Calafat AM, *et al.* Urinary pyrethroid and chlorpyrifos metabolite concentrations in Northern California families and their relationship to indoor residential insecticide levels, part of the Study of Use of Products and Exposure Related Behavior (SUPERB). *Environ Sci Technol* 2014;48:1931-9.
2. Capasso M, Notturmo F, Manzoli C, Yuki N, Uncini A. Reversible conduction failure in pharyngeal-cervical-brachial variant of Guillain-Barré syndrome. *Muscle Nerve* 2010;42:608-12.
3. Zhang JC, Sun L, Nie QH. Botulism, where are we now? *Clin Toxicol (Phila)* 2010;48:867-79.
4. Kanwal SK, Yadav D, Chhapola V, Kumar V. Post-diphtheritic neuropathy: A clinical study in paediatric intensive care unit of a developing country. *Trop Doct* 2012;42:195-7.
5. Abdollahi M, Karami-Mohajeri S. A comprehensive review on experimental and clinical findings in intermediate syndrome caused by organophosphate poisoning. *Toxicol Appl Pharmacol* 2012;258:309-14.
6. Eddleston M, Street JM, Self I, Thompson A, King T, Williams N, *et al.* A role for solvents in the toxicity of agricultural organophosphorus pesticides. *Toxicology* 2012;294:94-103.
7. Aardema H, Meertens JH, Ligtenberg JJ, Peters-Polman OM, Tulleken JE, Zijlstra JG. Organophosphorus pesticide poisoning: Cases and developments. *Neth J Med* 2008;66:149-53.
8. Giampreti A, Lampati L, Chidini G, Rocchi L, Rolandi L, Lonati D, *et al.* Recurrent tonic-clonic seizures and coma due to ingestion of Type 1 pyrethroids in a 19-month-old patient. *Clin Toxicol (Phila)* 2013;51:497-500.
9. Ergün SS, Öztürk K, Su O, Gürsoy EB, Uğurad I, Yüksel G. Delayed neuropathy due to organophosphate insecticide injection in an attempt to commit suicide. *Hand (N Y)* 2009;4:84-7.
10. Nóvak EM, Werneck LC. Neurologic involvement caused by insecticides. Study of chronic manifestations in 13 cases. *Arq Neuropsiquiatr* 1997;35:129-38.
11. Thivakaran T, Gamage R, Gunarathne KS, Gooneratne IK. Chlorpyrifos-induced delayed myelopathy and pure motor neuropathy: A case report. *Neurologist* 2012;18:226-8.
12. Rajasekaran D, Subbaraghavalu G, Jayapandian P. Guillain-Barre syndrome due to organophosphate compound poison. *J Assoc Physicians India* 2009;57:714-5.
13. Karunatilake H, Amarasinghe S, Dassanayake S, Saparamadu T, Weerasinghe S. Partial ptosis, dilated pupils and ataxia following abamectin poisoning. *Ceylon Med J* 2012;57:125-6.
14. Hu YH, YanqCC, Deng JF, Wu ML. Methomyl-alphamethrin poisoning presented with cholinergic crisis, cortical blindness, and delayed peripheral neuropathy. *Clin Toxicol (Phila)* 2010;48:859-62.
15. Sung YF, Huang CT, Fan CK, Lin CH, Lin SP. Avermectin intoxication with coma, myoclonus, and polyneuropathy. *Clin Toxicol (Phila)* 2009;47:686-8.
16. Orzechowski KL, Swain MD, Robl MG, Tinaza CA, Swaim HL, Jones YL, *et al.* Neurotoxic effects of ivermectin administration in genetically engineered mice with targeted insertion of the mutated canine ABCB1 gene. *Am J Vet Res* 2012;73:1477-84.
17. Lotti M, Moretto A. Docarbamates cause polyneuropathy? *Muscle Nerve* 2006;34:499-502.
18. Jayawardane P, Senanayake N, Dawson A. Electrophysiological correlates of intermediate syndrome following acute organophosphate poisoning. *Clin Toxicol (Phila)* 2009;47:193-205.
19. Goel D, Singhal A, Srivastav RK, Verma A, Lamba A. Magnetic resonance imaging changes in a case of extra-pyramidal syndrome after acute organophosphate poisoning. *Neurol India* 2006;54:207-9.
20. Müller-Mohnssen H. Chronic sequelae and irreversible injuries following acute pyrethroid intoxication. *Toxicol Lett* 1999;107:161-76.
21. Müller-Mohnssen H, Hahn K. A new method for early detection of neurotoxic diseases (exemplified by pyrethroid poisoning). *Gesundheitswesen* 1995;57:214-22.
22. DeMicco A, Cooper KR, Richardson JR, White LA. Developmental neurotoxicity of pyrethroid insecticides in zebrafish embryos. *Toxicol Sci* 2010;113:177-86.
23. Lankosz-Lauterbach J, Kaczor Z, Kaciński M, Pietrzyk JA, Stec Z. Severe polyneuropathy in a 3-year-old child after dichlorophenoxy acetic herbicide – Chwastox intoxication, treated successfully with plasmapheresis (PF). *Przegl Lek* 1997;54:750-2.

Source of Support: Nil, Conflict of Interest: None declared.