

New onset of acute heavy menstrual bleeding in a 34-year-old woman

Roy Khalife MD, Lisa Duffett MD, Tzu-Fei Wang MD, Alan Tinmouth MD MSc

■ Cite as: *CMAJ* 2021 August 3;193:E1173-6. doi: 10.1503/cmaj.210169

A 34-year-old woman presented to the emergency department with a 1-day history of heavy menstrual bleeding. She described needing to use thick pads or diapers that required changing hourly because of the heavy flow of blood.

One month previously, she had had sudden onset pelvic pain resulting from a ruptured hemorrhagic ovarian cyst and had undergone an urgent laparoscopic ovarian cystectomy, which was complicated by excessive bleeding of about 900 mL. Four days after discharge postsurgery, she presented to the emergency department again with worsening abdominal and pelvic pain and a hemoglobin level of 41 (reference range 115–155) g/L. A second urgent surgery, an open laparotomy, was performed and active bleeding was eventually controlled with a left salpingo-oophorectomy. Perioperatively, the patient received 4 units of packed red blood cells, 4 units of frozen plasma and 2 g of tranexamic acid over a 24-hour period. Her hemoglobin level was 78 g/L at discharge.

Before these hospital visits, she had no concerns with abnormal bleeding or anemia, and had a baseline hemoglobin of 120 g/L. She had never previously had heavy menstrual bleeding, epistaxis or unusual ecchymosis. She had previously had a spontaneous vaginal delivery and dental work without bleeding complications. She did not have a family history of abnormal bleeding and had not taken nonsteroidal anti-inflammatory or anticoagulant medications. Her nutritional intake was adequate without dietary restrictions.

On examination, the patient seemed anxious, looked pale and was tachycardic. She had active vaginal bleeding and extensive ecchymosis was noted on her lower extremities. Laboratory investigations showed a hemoglobin of 52 g/L, with normal mean corpuscular volume, platelet count and leukocyte count. Peripheral blood smear showed severe anemia with moderate rouleaux formation. Her ferritin and vitamin B12 levels were within normal limits. A serum beta-human chorionic gonadotropin (β -HCG) test was negative, and pelvic ultrasound was unremarkable.

Which of the following laboratory tests would not be useful to investigate this patient's bleeding?

- Prothrombin time (PT) / international normalized ratio (INR)
- Activated partial thromboplastin time (aPTT)
- Fibrinogen level
- D-dimer assay
- Bleeding time

The answer is (e). This patient presented with recurrent abnormal bleeding and should be investigated for an underlying bleeding disorder. The patient's symptoms of recent onset bleeding from multiple causes (i.e., hemorrhagic ovarian cyst, postsurgical bleeding, new menorrhagia and abnormal ecchymosis) are suggestive of an acquired bleeding diathesis.

Tests of PT/INR, aPTT and fibrinogen levels are first-line investigations in the evaluation of abnormal bleeding. In addition, the D-dimer assay can be used to evaluate for disseminated intravascular coagulation. The bleeding time is no longer widely performed because of poor standardization, wide inter- and intrauser variability and resultant cutaneous scarring.¹

The patient history remains the best screening test for a bleeding diathesis, with particular attention to the location, severity and treatment of bleeding events, including dental and surgical procedures, menstruation and childbirth. Family history of spontaneous or provoked bleeding events may raise the suspicion of a congenital bleeding disorder. Although multiple medications are associated with an increased risk of bleeding, clinicians should ask specifically about use of antiplatelet agents (including nonsteroidal anti-inflammatory drugs) and anticoagulants.

Laboratory tests complement a thorough history. Kidney, liver and thyroid disorders can rarely increase bleeding and bruising tendencies in premenopausal women, manifesting as heavy menstrual bleeding. For our patient, test results for PT/INR, fibrinogen and D-dimer were normal, making the diagnosis of disseminated intravascular coagulation unlikely. However, she was found to have a prolonged aPTT of 46 (reference range 19–28) seconds.

What is the next single test to investigate an isolated, prolonged aPTT?

- Von Willebrand factor levels
- Platelet function studies
- Thrombin time
- Mixing study (50:50 study)
- Lupus anticoagulant

The answer is (d). An isolated, prolonged aPTT in a bleeding patient with no anticoagulation exposure should raise suspicion for defects of the intrinsic pathway of coagulation (factors VIII, IX, XI), which can be caused by either a deficiency of a coagulation factor or an inhibitor that interferes with the factors' activity.^{2,3} Although factor XII is also part of the intrinsic pathway, deficiencies lead to in vitro prolongation of aPTT without associated bleeding tendencies.^{2,4} Abnormalities in von Willebrand factor levels do not prolong the aPTT, unless there is a concomitant factor VIII deficiency.

Mixing, or 50:50, studies, in which the patient's plasma is mixed with normal plasma at 1:1 ratio,^{2,3} are performed in most laboratories to differentiate between factor deficiencies and the presence of inhibitors (Figure 1).⁴ Clinicians need to request this test, as it is not automatically per-

formed by laboratories. If coagulation factor level abnormalities are suspected and can be readily tested at one's centre, these tests should be performed simultaneously to avoid diagnostic delays.⁴

We promptly performed our patient's mixing study, and results were available after 2 hours. Her aPTT was 48.4 seconds and partially corrected to 34.5 seconds with the immediate mixing of normal pooled plasma (aPTT of 25.4 s). After incubation at 37°C for 1 hour, the patient's aPTT prolonged further to 57.6 seconds.

What diagnosis is most likely to explain this patient's presentation and her clinical and laboratory findings?

- Congenital coagulation factor deficiency
- Acquired coagulation factor inhibitor
- Von Willebrand disease
- Acquired von Willebrand syndrome
- Lupus anticoagulant

The answer is (b). In this case, results of the mixing study suggested the presence of a coagulation factor inhibitor. The further prolongation of aPTT after incubation at 37°C

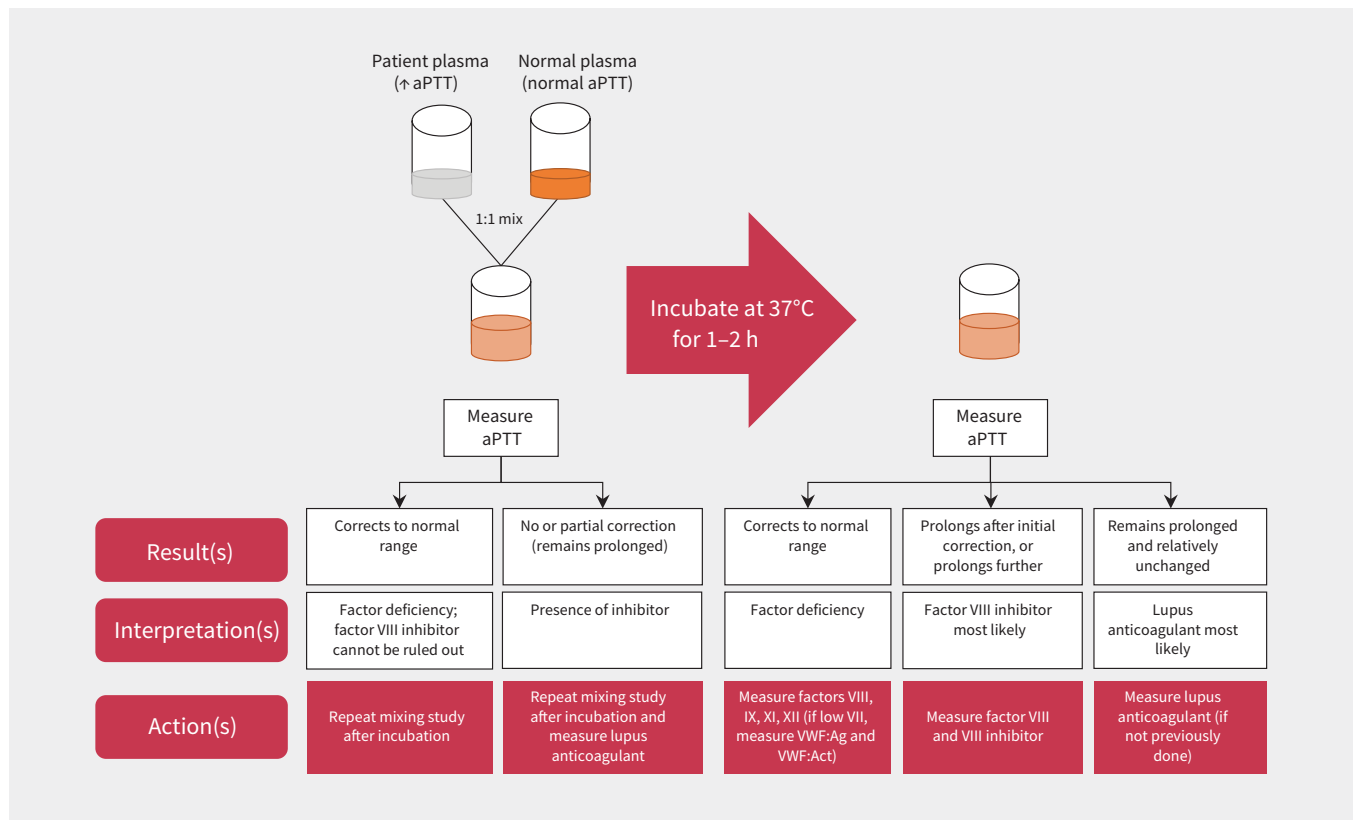


Figure 1: Interpretation of mixing studies and suggested follow-up investigations.¹⁻³ Plasma from the patient with prolonged activated partial thromboplastin time (aPTT) is mixed with normal plasma in a 1:1 ratio. The aPTT test is performed immediately after mixture with plasma and after incubation for 1–2 hours at 37°C. If the aPTT corrects (normalizes) at immediate testing and at 1 hour, then a coagulation factor deficiency is suspected as the normal plasma corrected the missing coagulation factor(s). If the aPTT corrects fully or partially on the immediate mixing study, but then prolongs after incubation for 1 hour, then a factor VIII inhibitor is suspected because of the time- and temperature-dependent kinetics. Lupus anticoagulant (a non-specific inhibitor) tends to prolong the aPTT with no correction on immediate mixing or after 1 hour (i.e., is not dependent on time or temperature). Note: Act = activity, Ag = antigen, VWF = von Willebrand factor.

(i.e., showing time and temperature dependence) is typically seen only in patients with an acquired factor VIII inhibitor.^{2,3} An acquired inhibitor to factor VIII, or acquired hemophilia A, is the most common acquired specific coagulation factor inhibitor.⁴ A lupus anticoagulant may prolong the aPTT, which would also result in a lack of correction in aPTT during the mixing study.² Additionally, our patient presented with substantial bleeding, and the presence of lupus anticoagulant is more often associated with thrombotic rather than bleeding complications.²

Therefore, acquired hemophilia A should be suspected in a bleeding patient with isolated prolongation of aPTT and the above mixing study pattern, and with no previous personal or family history of bleeding. Acquired hemophilia A is confirmed by a low factor VIII level and the presence of a factor VIII inhibitor, which can be measured in specialized coagulation laboratories.^{4,5} For completeness, we also tested von Willebrand factor antigen and activity levels, which were within normal range, ruling out acquired von Willebrand syndrome. Based on our investigations, we diagnosed acquired hemophilia A in our patient.

Which of the following management options is not appropriate at this time?

- Provide supportive and resuscitative care with saline and packed red blood cells
- Administer antifibrinolytic therapy (e.g., tranexamic acid)
- Perform an endometrial balloon tamponade until definitive management is available
- Consult with the on-call hematologist at a centre with clinical and laboratory expertise in the management of bleeding disorders for immediate treatment and transfer of care
- Consult with the on-call gynecologist for menstrual suppression and local treatments

The answer is (c). Patients suspected to have acquired hemophilia A should be transferred and managed at a centre with expertise in bleeding disorders and access to specialized coagulation testing and hemostatic therapies.⁴ The management of bleeding events in acquired hemophilia A requires treatment with specialized blood products, including agents that bypass factor VIII or concentrates of recombinant porcine factor VIII, which may not be available at all centres.⁴ Desmopressin, recombinant human factor VIII concentrates and plasma infusions are generally ineffective and not appropriate alternatives.⁴ The administration of tranexamic acid (an antifibrinolytic agent) and hormonal preparations are first-line treatment options in the management of acute, heavy menstrual bleeding and are important adjunct treatments.⁶ The use of endometrial balloon tamponade is invasive, and unlikely to be effective or necessary because control of bleeding requires treatment of the coagulopathy.⁶

We administered intravenous fluids, packed red blood cells, high-dose estrogen and tranexamic acid to manage our patient's acute, heavy menstrual bleeding and severe anemia. She was then transferred to a hemophilia treatment centre

and the diagnosis of acquired hemophilia A was confirmed by a reduced factor VIII level of 0.33 (reference range 0.50–1.50) IU/mL, and a detectable factor VIII inhibitor titer of 2.9 (reference range 0.0–0.5) Bethesda units/mL. In acquired hemophilia A, factor VIII levels are typically substantially reduced to below 0.05 IU/mL (5%), but levels between 0.05 and 0.50 IU/mL have also been implicated in bleeding events.^{7,8}

Our patient presented with bleeding after hemostatic challenges (i.e., ruptured ovarian cysts, postsurgical bleeding and menstrual flow), which would be expected in patients with mildly decreased factor VIII levels. High-dose estrogen therapy and tranexamic acid were given and successfully stopped her menstrual bleeding. Immunosuppression with prednisone at 1 mg/kg daily was started as an initial treatment to eradicate the inhibitor. Given that 30%–50% of patients with acquired hemophilia A will have an underlying malignancy or autoimmune condition,⁵ additional investigations were completed, including antinuclear antibodies, rheumatoid factor, protein electrophoresis, and imaging of her chest, abdomen and pelvis. Her work-up revealed an immunoglobulin G κ monoclonal protein level of 25 g/L. Bone marrow examination confirmed the diagnosis of a plasma cell neoplasm and additional studies did not show end-organ damage related to myeloma. The patient's acquired hemophilia A was considered to be secondary to multiple myeloma and chemotherapy was started to treat the underlying cause.

Discussion

Acquired hemophilia A is a rare bleeding disorder caused by autoantibodies that inhibit the function of factor VIII.^{4,5} The incidence is about 1 to 1.5 cases per million, with a median age of 64 years, affecting men and women equally.^{5,7} Acquired hemophilia A is a medical emergency requiring prompt recognition and treatment, especially in a bleeding patient. Its hallmark presentation consists of moderate-to-severe bleeding (large hematomas, or mucocutaneous or soft tissue bleeds), extensive bruising or bleeding from unusual sites, without a personal or family history of bleeding.⁵ Unlike with congenital hemophilia, hemarthroses are rare.^{5,7} Bleeding tends to be spontaneous, but may be secondary to trauma or surgery, and may not correlate with factor VIII activity.^{4,7,8} Lack of recognition can lead to potentially fatal bleeding events.⁷ A cause is identified in about 50% of cases, with common causes including malignancies, autoimmune disorders, infections and drugs.^{5,7} It can also develop among people in the postpartum period.^{4,7}

The management of acquired hemophilia A requires clinical and laboratory expertise in hemostasis and generally requires referral to a hemophilia treatment centre.⁴ The main management strategies include treatment of acute bleeding event, eradication of inhibitors and treatment of the underlying cause, if found.⁴ The hemostatic agents used to manage bleeding events include agents that bypass factor VIII (i.e., recombinant factor VIIa [e.g., Niastase, NovoSeven] and activated prothrombin complex concentrates [e.g., FEIBA]), and recombinant porcine factor VIII concentrate, (e.g., Obizur).

As there are no randomized controlled trials comparing these agents, the choice of hemostatic agent is typically guided by patient and product characteristics, and by physician experience.⁴ Tranexamic acid should be used cautiously in patients receiving recombinant factor VIIa or activated prothrombin complex concentrates, given case reports of thromboembolic complications when used concomitantly.⁴

First-line immunosuppressants for eradication of inhibitors include corticosteroids alone (for 4–6 wk, followed by taper) or in combination with cyclophosphamide (for 6 wk).⁴ In the largest, multicentre, European prospective cohort study of acquired hemophilia A, combination therapy offered faster and higher remission rates, but had a similar overall mortality rate to corticosteroids alone, likely from the increased toxicity and infection complications related to cyclophosphamide.⁹ Rituximab, administered weekly for a maximum of 4 cycles, can also be used in combination with corticosteroids, but is generally considered second-line therapy, and outcomes appear similar or slightly better than corticosteroids alone.⁹

Mortality rates from bleeding in patients with acquired hemophilia A, historically around 20%–30%, have improved in recent years and vary between 3% (in the largest and longest registry)⁷ to 9% (in a 2-year cohort study).¹⁰ A recent single-centre, retrospective cohort study in Canada reported high rates of hospitalization (87.5%) and critical care admissions (12.5%) for patients with acquired hemophilia A.¹¹ Delays in time to treatment are associated with lower response rates and worse clinical outcomes.^{4,8}

References

- Ma A, Mazepa M. Evaluation of the bleeding patient. In: Key NS, Makris M, Lillicrap D, editors. *Practical Hemostasis and Thrombosis*. 3rd ed. John Wiley & Sons; 2017:63-78.
- Hayward CPM, Moffat KA. Laboratory testing for bleeding disorders: strategic uses of high and low-yield tests. *Int J Lab Hematol* 2013;35:322-33.
- Elbaz C, Sholzberg M. An illustrated review of bleeding assessment tools and common coagulation tests. *Res Pract Thromb Haemost* 2020;4:761-73.
- Tiede A, Collins P, Knoebl P, et al. International recommendations on the diagnosis hemophilia and a treatment of acquired. *Haematologica* 2020;105:1791-801.
- Tiede A, Zieger B, Lisman T. Acquired bleeding disorders. *Haemophilia* 2021;27(Suppl 3):5-13.
- James AH, Kouides PA, Abdul-Kadir R, et al. Evaluation and management of acute menorrhagia in women with and without underlying bleeding disorders: consensus from an international expert panel. *Eur J Obstet Gynecol Reprod Biol* 2011;158:124-34.
- Knoebl P, Marco P, Baudo F, et al. Demographic and clinical data in acquired hemophilia A: results from the European Acquired Haemophilia Registry (EACH2). *J Thromb Haemost* 2012;10:622-31.
- Holstein K, Liu X, Smith A, et al. Bleeding and response to hemostatic therapy in acquired hemophilia A: results from the GTH-AH 01/2010 study. *Blood* 2020;136:279-87.
- Collins P, Baudo F, Knoebl P, et al. Immunosuppression for acquired hemophilia A: results from the European Acquired Haemophilia Registry (EACH2). *Blood* 2012;120:47-55.
- Collins PW, Hirsch S, Baglin TP, et al. Acquired hemophilia A in the United Kingdom: a 2-year national surveillance study by the United Kingdom Haemophilia Centre Doctors' organisation. *Blood* 2007;109:1870-7.
- Jayakar JP, O'Neill N, Yan M, et al. Retrospective review of Acquired Haemophilia A from the largest Canadian Haemophilia treatment centre. *Haemophilia* 2018;24:e383-7.

Competing interests: Roy Khalife reports research grants from the Canadian Hemophilia Society, Pfizer and the Department of Innovation in Medical Education of the University of Ottawa. He has also received speaking honoraria from Pfizer. Tzu-Fei Wang reports a grant from Leo Pharma, and payments for serving on the advisory boards of Pfizer and Servier. No other competing interests were declared.

This article has been peer reviewed.

The authors have obtained patient consent.

Affiliations: Department of Medicine, University of Ottawa at The Ottawa Hospital and Ottawa Hospital Research Institute, Ottawa, Ont.

Contributors: All of the authors contributed to the conception and design of the work, drafted the manuscript, revised it critically for important intellectual content, gave final approval of the version to be published and agreed to be accountable for all aspects of the work.

Content licence: This is an Open Access article distributed in accordance with the terms of the Creative Commons Attribution (CC BY-NC-ND 4.0) licence, which permits use, distribution and reproduction in any medium, provided that the original publication is properly cited, the use is noncommercial (i.e., research or educational use), and no modifications or adaptations are made. See: <https://creativecommons.org/licenses/by-nc-nd/4.0/>

Correspondence to: Roy Khalife, rkhalife@toh.ca

CMAJ invites submissions to “What is your call?” Clinical details (including images) are presented with a multiple-choice question about the diagnosis. The answer and a brief discussion of the condition follow. We specifically invite submissions illustrating common or important radiographic and electrocardiographic diagnoses of appeal to a general audience. We require authors to obtain consent from the patient for publication of his or her story. Submit manuscripts online at <http://mc.manuscriptcentral.com/cmaj>