

Sclerosing liposarcoma of epididymis: Role of chemical shift magnetic resonance imaging

Subramaniyan Ramanathan, Vineetha Raghu², Devendra Kumar, Venkata R P Sempiege¹

Departments of Clinical Imaging and ¹Urology, Hamad Medical Corporation, Doha, Qatar, ²Department of Radiology, Consultant Radiologist, NU West, Rajajinagar, Bangalore, India

Correspondence: Dr. Subramaniyan Ramanathan, Department of Clinical Imaging, Hamad Medical Corporation, Doha, Qatar. E-mail: rm_subbu2000@yahoo.com

Abstract

Sclerosing liposarcoma of epididymis is a rare extratesticular scrotal tumor with variable prognosis. Ultrasonography is the initial imaging modality of choice for the evaluation of scrotal mass and helps to differentiate testicular and extratesticular masses, thereby narrowing down the differential diagnosis. Magnetic resonance imaging with its excellent soft tissue resolution can help in the further characterization of the nature of the tumor. In this case report, we highlight the role of chemical shift imaging in making a confident preoperative diagnosis of liposarcoma thereby guiding optimal and timely management.

Key words: Chemical shift imaging; epididymis; liposarcoma; magnetic resonance imaging; sclerosing

Introduction

Liposarcoma of paratesticular tissues that include spermatic cord, testicular tunics, and the epididymis is a relatively rare tumor and comprises approximately 7% of paratesticular sarcomas.^[1,2] Most of these cases present with a painless scrotal mass. Ultrasonography (USG) reveals the site of origin of the scrotal mass. Here, we present a case of sclerosing variant of well-differentiated liposarcoma of epididymis, which was characterized preoperatively on magnetic resonance imaging (MRI) using chemical shift imaging (CSI) demonstrating the microscopic fat within the tumor. To our knowledge, this is the first case report emphasizing the role of chemical shift MRI in the characterization of fat-containing epididymal tumors.

Case History

A 37-year-old Filipino male presented with a painless left scrotal swelling since 1 year. Physical examination revealed a hard mass in the left scrotal sac which was neither reducible nor transilluminating. A testicular/paratesticular tumor was considered in the differential diagnosis. Serum beta human chorionic gonadotropin levels and alphafeto protein levels were normal.

USG was performed using 3–12 MHz high-frequency linear transducer (LOGIQ E9, General Electric Medical Systems, Chicago, USA) and it revealed a heterogenous, well-defined, extra-testicular mass posterior and inferior to the left testis. It was predominantly hyperechoic, measuring 5 × 4.5 ×

Access this article online

Quick Response Code:



Website:
www.ijri.org

DOI:
10.4103/0971-3026.190425

This is an open access article distributed under the terms of the Creative Commons Attribution-NonCommercial-ShareAlike 3.0 License, which allows others to remix, tweak, and build upon the work non-commercially, as long as the author is credited and the new creations are licensed under the identical terms.

For reprints contact: reprints@medknow.com

Cite this article as: Ramanathan S, Raghu V, Kumar D, Sempiege VR. Sclerosing liposarcoma of epididymis: Role of chemical shift magnetic resonance imaging. Indian J Radiol Imaging 2016;26:356-9.

2.6 cm, and showed minimal vascularity. Considering the solid nature of the mass, possibility of neoplastic etiology was entertained and a staging computed tomography (CT) scan of the chest and abdomen was performed using intravenous contrast. It showed a heterogeneously enhancing left hemiscrotal mass separate from the testis with no retroperitoneal lymphadenopathy or lung metastasis [Figure 1].

MRI scrotum was performed using 1.5-T system (Magnetom Avanto, Siemens Healthcare, Malvern, Pennsylvania, USA) using a circular surface coil. Scrotal MRI protocol included axial T1-weighted (T1W) turbo spin echo (TSE) with and without fat suppression, three plane T2W TSE, axial fat-suppressed T2W TSE, and two-dimensional T1W dual echo in and opposed phase chemical shift imaging (CSI). Patients received 0.1 mmol/kg of body weight of gadopentetate dimeglumine (Magnevist, Bayer HealthCare Pharmaceuticals, Whippany NJ, USA) approximately 1 min prior to axial and coronary fat-suppressed T1W postcontrast TSE images. MRI showed a heterogenous T2 hyperintense and T1 isointense mass in the left hemiscrotum posteroinferior to and separate from the left testis displacing it more superiorly [Figure 2]. Differential diagnosis of adenomatoid tumor, fibrous pseudotumor, and low grade sarcoma probably of epididymal origin were considered considering its posteroinferior location. CSI (in and opposed phase images) is a special sequence performed to detect microscopic fat and is routinely performed in all abdomen and pelvic MRI in our institution. It was also performed in this patient and revealed signal drop on the opposed phase indicating the presence of fat within the tumor, favoring the diagnosis of lipid containing benign or malignant

tumors [Figure 3]. It showed heterogenous enhancement on postcontrast images [Figure 3].

Following discussion in the tumor board, left radical orchiectomy and wide excision of the tumor with high ligation of the spermatic cord was performed. Histopathology revealed a tumor adherent to left epididymis, with histopathological features consistent with well-differentiated sclerosing liposarcoma. The tumor margin was negative for malignancy. The left spermatic cord and testis were uninvolved by the tumor. The patient had uneventful recovery and was advised follow-up with CT chest and abdomen after 6 months.

Discussion

Paratesticular liposarcoma is a rare entity with less than 200 cases reported so far.^[1-3] Although it is the most frequently encountered intrascrotal sarcoma, primary epididymal origin is rare. Spermatic cord is the most common site followed by testicular tunics and epididymis (76%, 20%, and 4%, respectively). The mean age at presentation is 55 years (with a range from 16 to 85 years), usually presenting as a painless scrotal mass.^[4] There have been case reports of a paratesticular liposarcoma mimicking clinically (and sometimes radiologically) as an inguinal hernia.^[5] Hence, it is imperative to have in mind that liposarcoma is a differential diagnosis of painless scrotal mass.

At least 4 histological types of liposarcoma have been described. (1) Well-differentiated liposarcoma,

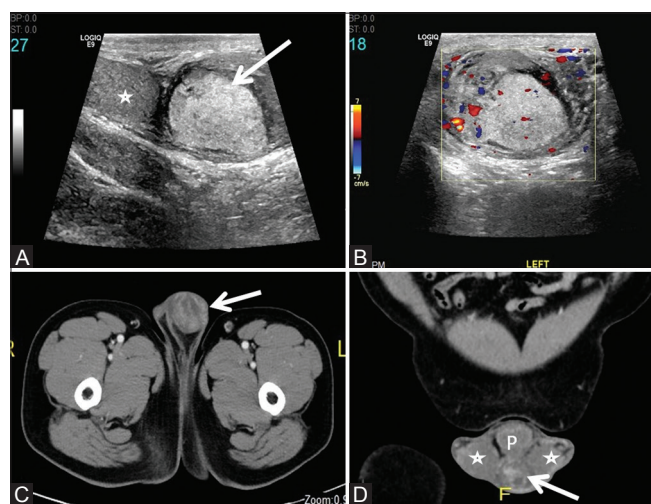


Figure 1 (A-D): (A) Grey scale ultrasound shows hyperechoic mass (arrow) separate from the testis (asterisk). (B) Color Doppler ultrasound shows minimal internal vascularity. (C) Axial and (D) coronal contrast-enhanced CT shows heterogeneously enhancing extratesticular mass (arrow) separate from the testes (asterisk). P: Penis

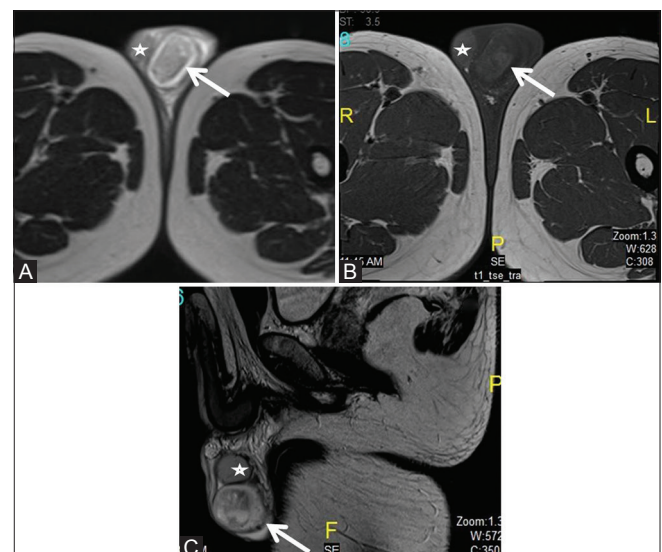


Figure 2 (A-C): (A) Axial T2-weighted MRI shows heterogeneous hyperintense mass (arrow) in the left hemiscrotum separate from the testis (asterisk). (B) Axial T1-weighted MRI shows heterogeneous isointense mass (arrow) in the left hemiscrotum separate from the testis (asterisk). (C) Sagittal T2-weighted MRI shows clearly the posteroinferior location of the mass (arrow) in relation to the left testis (asterisk) suggesting possible epididymal origin

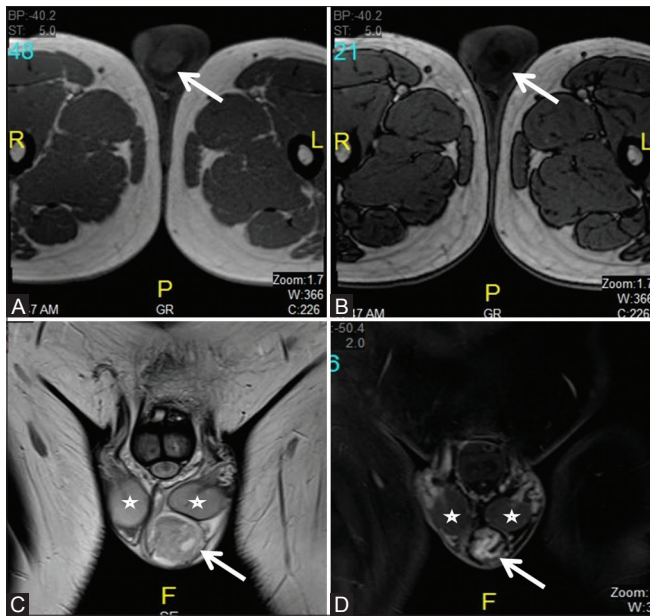


Figure 3 (A-D): (A) In-phase and (B) Out-of-phase images from chemical shift MRI shows signal drop within the mass (arrow). (C) Coronal T2-weighted MRI shows heterogeneous hyperintense mass (arrow) in the left hemiscrotum separate from the testis (asterisk). (D) Postcontrast T1-weighted MRI shows heterogeneously enhancing mass (arrow) in the left hemiscrotum separate from the testis (asterisk)

(2) sclerosing liposarcoma, (3) myxoid variety, (4) dedifferentiated liposarcoma.^[6] USG is usually the first investigation that is ordered given its wide availability, low cost, and superior depiction of scrotal anatomy. It typically reveals a solid, hyperechoic, heterogeneous lesion separate from the testis. However, USG findings are often variable and nonspecific.^[7] CT demonstrates a soft tissue mass with fat attenuation intermixed with septa or soft tissue nodules. The presence and the amount of fat depend on the degree of differentiation and the histological subtype. It may be absent or present in a small quantity in dedifferentiated and sclerosing variants (as in our current case).^[7]

MRI is being increasingly used in the characterization of scrotal masses because of its superior soft tissue contrast and absence of radiation. MRI allows differentiation of extratesticular from intratesticular disease and also the tissue nature of the lesion. It offers a wider field of view than USG, and is better than USG in differentiating between a solid neoplasm and inflammatory or vascular abnormalities or inguinal hernia^[8] Specifically, MRI allows detection of fat, blood products, and fibrous tissue, hence offering a preoperative histological diagnosis.^[9]

T1W images are useful in the detection of fat in lipoma or liposarcoma, which gives a high signal. Blood and proteinaceous contents within a cyst may also give a high T1 signal and fat suppression is useful in differentiation. Liposarcoma often shows soft-tissue septa and areas of

calcification. Fat is detected in approximately 80% of cases of liposarcoma.^[10,11] The sclerosing subtype, however, shows CT attenuation or an MR signal intensity that approximates the characteristics of muscle. Unlike other subtypes of well-differentiated liposarcoma, the sclerosing variant is less likely to be composed predominantly of fat and may be associated with an increased propensity for dedifferentiation.^[10,11]

CSI with in-phase and out-of-phase axial T1W spoiled gradient-echo sequences is more accurate in identifying fat-water admixtures and microscopic fat especially in such cases. It is more sensitive than frequency-selective fat suppression because the latter simply eliminates signal from fat, so that a larger amount of fat is required for its effect to be noticeable. This sequence showed the presence of minimal fat in our index case as signal drop in the out-of-phase images which helped in the preoperative diagnosis of liposarcoma and thereby helping in timely diagnosis and treatment.^[12] It is important to make this observation preoperatively because it has significant implications in the surgical planning and prognostication. If the paratesticular tumors contain easily identifiable macroscopic fat on CT and/or conventional MRI, it usually indicates well-differentiated liposarcoma, which is known to have relatively good prognosis. In contrast, identification of small amount of microscopic fat using CSI, as in our index case, often indicates poor or dedifferentiated tumor with grave prognosis.^[10,11]

The differential diagnosis of paratesticular masses includes sclerosing lipogranuloma, fibrous pseudotumor, germ cell tumors, and lymphoma among other lesions. Sclerosing lipogranuloma is a fat-containing paratesticular tumor and presents with a painless intrascrotal mass that gradually increases in size. Microscopic analysis shows lipid vacuoles surrounded by densely sclerotic stroma and foreign body granulomas. USG demonstrates a hypoechoic extra testicular mass. T1W and T2W MR images typically show an enlarged heterogeneous mass that contains intravoxel fat in the upper scrotum or penoscrotal junction. It has a high prevalence of spontaneous resolution and may be managed conservatively or treated with excisional biopsy.^[8]

Fibrous pseudotumor or chronic periorchitis is a nonneoplastic lesion that may present as an indurated scrotal mass. A history of epididymo-orchitis or infected hydrocele, and sometimes trauma is usually present and imaging features are nonspecific and the diagnosis is usually established at surgery or histopathology.^[13] Paratesticular sarcomas include rhabdomyosarcoma, leiomyosarcoma, fibrosarcoma, and malignant fibrous histiocytoma. These have similar imaging features with heterogeneous T2 high signal and heterogeneous postcontrast

enhancement. They do not contain fat unless lipomatous differentiation occurs.^[13]

Germ cell tumors of paratesticular area are overall rare, the epididymis being more commonly involved than the spermatic cord. These include seminoma, embryonal carcinoma, and teratoma with similar clinical and biochemical picture as the testicular type. Lymphoma primarily involving the epididymis or paratesticular area is very rare; these may be secondarily involved in the cases of testicular lymphoma.^[13] Metastatic involvement of the paratesticular area by tumors of the prostate, kidney, lung, and stomach have rarely been reported.

Liposarcoma tends to spread primarily by local extension. The treatment of choice is radical orchidectomy and wide excision with high ligation of the spermatic cord. Scrotectomy may be considered to prevent local recurrence.^[14] If the margin is in doubt, adjuvant radiotherapy is indicated. Retroperitoneal lymph node dissection is not indicated unless there is evidence of metastasis. Long-term follow-up is usually necessary because of unfavourable prognosis of sarcomatous tumors in general and high likelihood of recurrence.

Conclusion

Paratesticular liposarcoma is a rare entity and epididymal origin is uncommon with variable imaging features. USG and CT show the extratesticular location of the tumor. However MRI helps in confident diagnosis by showing the lipomatous nature of these masses. Chemical shift MRI is valuable in identifying microscopic fat which can be overlooked on CT and conventional MRI, as was in the abovementioned case of sclerosing liposarcoma. Identification of minimal microscopic fat as compared to large amount of macroscopic fat often indicated poor or dedifferentiated tumors with grave prognosis.

Financial support and sponsorship

Nil.

Conflicts of interest

There are no conflicts of interest.

References

- Schwartz SL, Swierzewski SJ 3rd, Sondak, VK, Grossmann HB. Liposarcoma of the spermatic cord: Report of 6 cases and review of the literature. *J Urol* 1995;153:154-7.
- Catton C, Cummings BJ, Fornasier V, O'Sullivan B, Quirt I, Warr D. Adult paratesticular sarcoma: A review of 21 cases. *J Urol* 1991;146:342-5.
- Sogani PC, Grabstald H, Withmore WJ Jr. Spermatic cord sarcoma in adults. *J Urol* 1978; 120:301-5.
- Alyousef H, Osman EM, Gomha MA. Paratesticular Liposarcoma: A Case Report and Review of the Literature. *Case Rep Urol* 2013;2013:806289.
- Li F, Tian R, Yin C, Dai X, Wang H, Xu N, *et al.* Liposarcoma of the spermatic cord mimicking a left inguinal hernia: A case report and literature review. *World J Surg Oncol* 2013;11:18.
- Petersen RO, Sesterhenn I, Davis CJ. *Urologic Pathology*. 3rd ed. Philadelphia: Lippincott Williams & Wilkins; 2009: p. 427
- Papageorgiou MS, Dadakas G, Donev K. Liposarcoma of the spermatic cord: A case report. *Case Rep Med* 2011;2011:197584.
- Fiona Hughes Cassidy, Kevin M. Ishioka, Colm J. McMahon *et al.* MR imaging of scrotal tumors and pseudotumors. *Radiographics* 2010;30:665-83.
- Tsili AC, Tsampoulas C, Giannakopoulos X, Stefanou D, Alamanos Y, Sofikitis N, *et al.* MRI in the histologic characterization of testicular neoplasms. *AJR Am J Roentgenol* 2007;189:W331-7.
- Shin NY, Kim MJ, Chung JJ, Chung YE, Choi JY, Park YN. The differential imaging features of fat-containing tumors in the peritoneal cavity and retroperitoneum: The radiologic-pathologic correlation. *Korean J Radiol* 2010;11:333-45
- Bestic JM, Kransdorf MJ, White LM, Bridges MD, Murphey MD, Peterson JJ, *et al.* Sclerosing variant of well-differentiated liposarcoma: Relative prevalence and spectrum of CT and MRI features. *AJR Am J Roentgenol* 2013;201:154-61.
- Pereira JM, Sirlin CB, Pinto PS, Casola G. CT and MR imaging of extrahepatic fatty masses of the abdomen and pelvis: Techniques, diagnosis, differential diagnosis, and pitfalls. *Radiographics* 2005;25:69-85.
- Bostwick DG, Cheng L. *Urologic Surgical Pathology*. Chapter 14. 3rd ed. Philadelphia: Elsevier Health Sciences; 2014.
- Coleman J, Brennan MF, Alektiar K, Russo P. Adult spermatic cord sarcomas: Management and results. *Ann Surg Oncol* 2003;10:669-75.