



Case Report

Primary pediatric cerebellar gliosarcoma

Syed Sarmad Bukhari¹, Muhammad Junaid², Ali Afzal³, Anisa Kulsoom³

¹Department of Neurosurgery, Aga Khan University Hospital, ²Department of Neurosurgery, Bahria University Medical and Dental College, Karachi,

³Department of Radiology, Fauji Foundation Hospital, Jhelum Road, Rawalpindi, Punjab, Pakistan.

E-mail: *Syed Sarmad Bukhari - sarmadbukhari@gmail.com; Muhammad Junaid - junaidkhan1034@gmail.com; Ali Afzal - dokterali@gmail.com; Anisa Kulsoom - docanisa@hotmail.com



*Corresponding author:

Syed Sarmad Bukhari,
Department of Neurosurgery,
Aga Khan University Hospital,
Stadium Road, Karachi - 74800,
Sindh, Pakistan.

sarmadbukhari@gmail.com

Received : 28 April 2019
Accepted : 03 March 2020
Published : 09 May 2020

DOI
10.25259/SNI_274_2019

Quick Response Code:



ABSTRACT

Background: Primary gliosarcomas of the central nervous are rare and very few have been reported in the infratentorial compartment. Here, we describe such a lesion in a 12-year-old male.

Case Description: A 12-year-old male presented with headache, ataxia, and vomiting. When Magnetic resonance studies documented a posterior fossa lesion, he underwent placement of a right ventriculoperitoneal shunt followed by a suboccipital craniectomy. The lesion proved to be a primary gliosarcoma. Unfortunately, it recurred 2 years later and required repeated resection.

Conclusion: Here, we reviewed the rare case of a 12-year-old male requiring shunt placement and suboccipital craniectomy for a primary gliosarcoma that recurred 2 years later.

Keywords: Gliosarcoma, Pediatric, Primary

INTRODUCTION

Gliosarcomas are malignant brain tumors that usually involve the temporal lobe in the supratentorial compartment; only rarely do they involve the cerebellum.^[3] They typically contain mixed glial and mesenchymal elements. The present WHO system classifies them as a variant of glioblastomas. Here, we present a 12-year-old male who first underwent ventriculoperitoneal shunt placement and a suboccipital craniectomy for a primary cerebellar gliosarcoma resection; unfortunately, the tumor recurred 2 years later.

CASE DESCRIPTION

Clinical and magnetic resonance (MR) presentation

A 12-year-old male presented with headache, ataxia, and vomiting of 3 months duration. The brain MRI with/without contrast revealed a heterogenous appearing lesion within the fourth ventricle measuring 3.18 × 3.26 × 3.90 cm. There was also a small cystic component noted along the right lateral aspect which was isointense on T1, iso to hyperintense on T2, and hyperintense on the FLAIR study. Anteriorly, the tumor was causing marked compression of the medulla oblongata, pons, and midbrain; this resulted in obstructive hydrocephalus.

This is an open-access article distributed under the terms of the Creative Commons Attribution-Non Commercial-Share Alike 4.0 License, which allows others to remix, tweak, and build upon the work non-commercially, as long as the author is credited and the new creations are licensed under the identical terms.

©2020 Published by Scientific Scholar on behalf of Surgical Neurology International

Surgery

The patient first underwent placement of a right-sided ventriculoperitoneal shunt. This was followed by a suboccipital craniotomy for subtotal excision of tumor. At surgery, the lesion was firm pseudo-encapsulated, and partially adherent to the brainstem on the left; due to the adhesions, a portion of the left-sided lesion was unresectable.

Pathology and immunohistochemistry

The microscopic features and the immunohistochemical profile revealed a heterogeneous tumor with hypercellular tissue that contained spindle-shaped cells that were vimentin positive. These findings confirmed the diagnosis of a cerebellar gliosarcoma [Figure 1]. The patient was, therefore, referred to oncology for further management.

Postoperative course and repeat MR 1 year later

The patient did well post-surgery for 1 year. However, when the MRI was repeated, it documented a significant recurrent lesion now measuring $4.1 \times 3.3 \times 3.7$ cm [Figures 2 and 3]. However, there was no increase in hydrocephalus due to the presence of the VP shunt. In addition, the MR showed herniation of the cerebella tonsils through the foramen magnum with attendant syringohydromyelia involving the cervicodorsal cord. Although the patient's family was offered further surgery, they declined, and the patient was lost to follow-up.

Poor outcome 2 years later without further surgery

The patient next seen 2 years postoperatively. Over the prior 3 months, he had developed progressive quadriparesis and was wheelchair bound for 1 month. Although a follow-up MRI was requested, only a T2 sequence could be obtained due to financial constraints [Figure 4]. Due to very significant brainstem compression, the patient underwent a repeated suboccipital resection of tumor. Despite the subsequent postoperative MRI showing maximum safe resection of

tumor, the patient's clinical condition did not improve in the early postoperative period (1 month of follow-up) [Figure 5].

DISCUSSION

WHO classification

Gliosarcoma has been classified by the World Health Organization (WHO) as high-grade tumors (Grade IV) resembling glioblastomas. They account for nearly 2% of Grade IV glial neoplasms and have a similar age distribution as glioblastoma.^[3]

Location

Most, if not all, cases of primary gliosarcomas in the literature occur in the supratentorial compartment, very rarely, they involve the cerebellum in adults, and even less frequently, in children.^[3,7] These tumors typically involve the peripheral regions of the temporal lobe followed by the frontal and parietal lobes; they only occasionally involve the corpus callosum. Here, we reported the unusual presentation of a cerebellar gliosarcoma occurring in a 12-year-old male within the fourth ventricle, abutting the brainstem.

Computed tomography (CT) and MR findings of gliosarcoma

CT

CT findings are similar to those for an infiltrating glioblastoma. They may appear as a well-defined hyperdense mass with heterogeneous ring enhancement due to their fibrous component. Central necrosis is less common due to their predilection for peripheral lobe locations. Dural involvement is not uncommon.^[5,6]

MR

Nitta *et al.*^[6] reported that the MRI appearance of infratentorial gliosarcomas resembles those of supratentorial gliosarcomas, for example, peripheral location within the

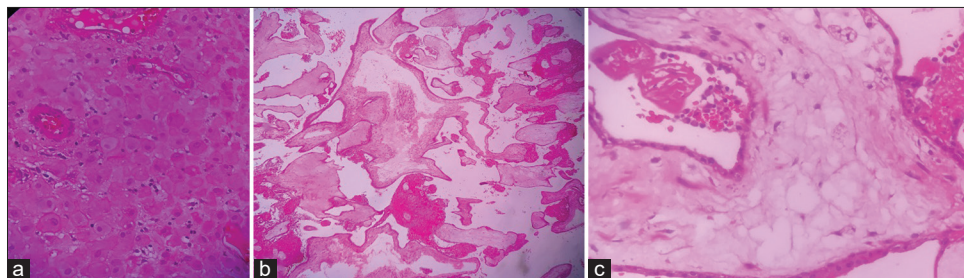


Figure 1: (a-c) Photomicrographs with H&E staining demonstrating the cytoarchitecture of the tumour with hypercellular and hypocellular myxoid areas. The cellular areas are composed of spindle shaped cells having mildly pleomorphic elongated nuclei. Scattered eosinophilic globules with few microtubules are seen as well.

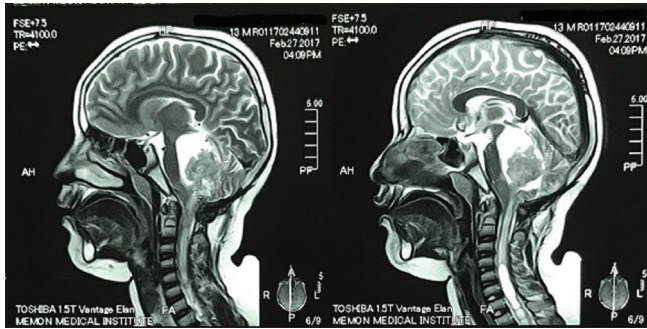


Figure 2: Post-operative T2 weighted sagittal images showing a large 4th ventricular mass causing downward migration of the cerebellar tonsils and anterior compression on the brainstem demonstrating recurrence.

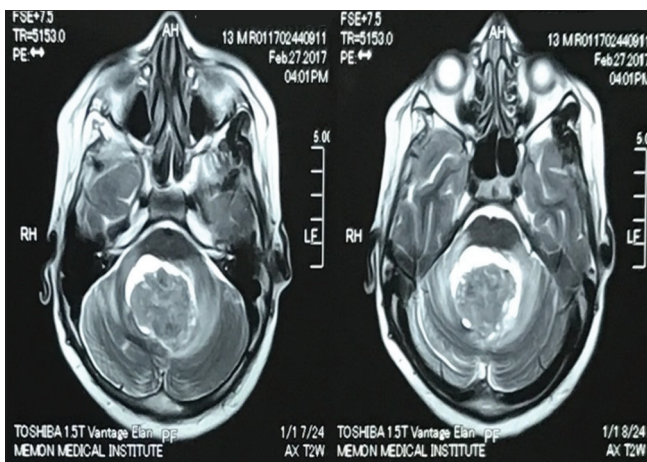


Figure 3: Post-operative T2 weighted axial images showing tumor recurrence with a sleeve of cerebrospinal fluid around the tumor. The tumor growth was in what is likely the resection cavity.

cerebellum, accompanied by a broad meningeal base, with multifocality. Further, on magnetic resonance imaging, gliosarcomas appear as a heterogeneous mass both on T1- and T2-weighted images, with strong peripheral enhancement, and central hemorrhage or necrosis.^[5]

Pathology of gliosarcomas

Pathologically, gliosarcomas are characterized by a biphasic tissue pattern with alternating areas of glial and mesenchymal differentiation.^[1] The sarcomatous component shows malignant spindle cells with features of fibrosarcoma or malignant fibrous histiocytoma. Areas of mesenchymal differentiation into cartilage, bone, fat, and smooth or skeletal muscle may be an associated finding. In our case, the tumor was predominantly sarcomatous and had a mixture of clearly malignant mesenchymal GFAP-negative areas and GFAP-positive glial areas. Furthermore, collagen deposition and reticulin fibers were seen in the sarcomatous component

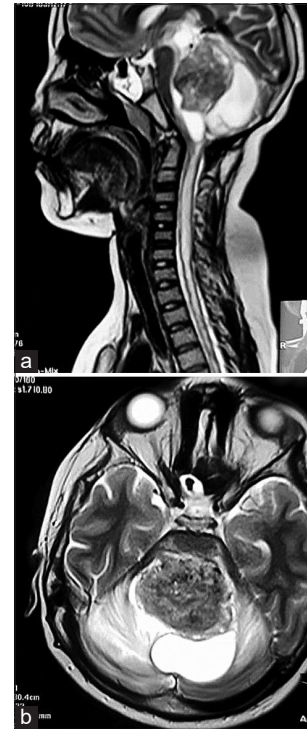

Figure 4: Post-operative magnetic resonance imaging at 2 year follow up. (a) Sagittal images showing significant increase in the size of the lesion causing increasing mass effect over the adjacent brain stem. (b) Axial section showing increased pressure effect over the brain stem.

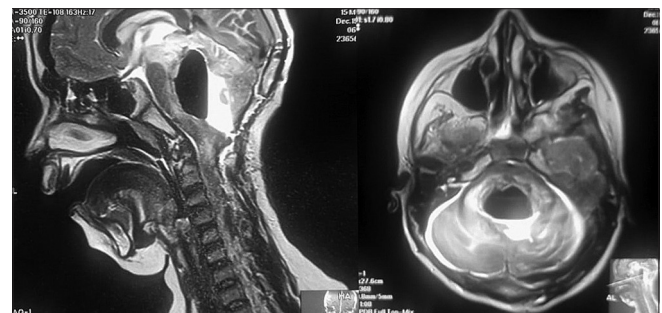


Figure 5: Magnetic resonance imaging brain without contrast showing immediate post op images demonstrating maximum safe resection of the tumor.

which helped differentiate it from glioblastoma (e.g., with florid fibroblastic proliferation).^[2]

Local recurrence

Local recurrence and metastases of gliosarcomas along cerebrospinal fluid pathways are common.^[8] Of interest, extracranial metastases carry an even worse prognosis.^[4] Common differential diagnoses for gliosarcomas include glioblastoma, metastasis, brain abscess, or other infratentorial intraaxial tumors (e.g., hemangioblastomas or medulloblastomas).^[3,5]

CONCLUSION

Primary infratentorial gliosarcomas are rare in children and are particularly located within the infratentorial compartment. Although shunting and resection may result in short-term improvement, these lesions typically recur, resulting in devastating neurological deficits and short-term survival.

Declaration of patient consent

Patient's consent not required as patients identity is not disclosed or compromised.

Financial support and sponsorship

Nil.

Conflicts of interest

There are no conflicts of interest.

REFERENCES

1. Alatakis S, Stuckey S, Siu K, McLean C. Gliosarcoma with osteosarcomatous differentiation: Review of radiological and

2. Han SJ, Yang I, Tihan T, Prados MD, Parsa AT. Primary gliosarcoma: Key clinical and pathologic distinctions from glioblastoma with implications as a unique oncologic entity. *J Neurooncol* 2010;96:313-20.
3. Karremann M, Rausche U, Fleischhack G, Nathrath M, Pietsch T, Kramm CM, *et al.* Clinical and epidemiological characteristics of pediatric gliosarcomas. *J Neurooncol* 2010;97:257-65.
4. Malde R, Jalali R, Muzumdar D, Shet T, Kurkure P. Gliosarcoma occurring 8 years after treatment for a medulloblastoma. *Childs Nerv Syst* 2004;20:243-6.
5. Neelima R, Abraham M, Kapilamoorthy TR, Hingwala DR. Pediatric gliosarcoma of thalamus. *Neurol India* 2012;60:674-6.
6. Nitta H, Hayase H, Moriyama Y, Yamashita T, Yamashita J. Gliosarcoma of the posterior cranial fossa: MRI findings. *Neuroradiology* 1993;35:279-80.
7. Nsir B, Thai Q, Kassab AZ, Said B, Jemel H. Primary cerebellar gliosarcoma with extracranial metastases: An orphan differential diagnosis. *World Neurosurg* 2015;84:2076.e13-7.
8. Reis RM, Konu-Lebleblicioglu D, Lopes JM, Kleihues P, Ohgaki H, *et al.* Genetic profile of gliosarcomas. *Am J Pathol* 2000;156:425-32.

How to cite this article: Bukhari SS, Junaid M, Afzal A, Kulsoom A. Primary pediatric cerebellar gliosarcoma. *Surg Neurol Int* 2020;11:96.