

Case Report

---

# Lenvatinib Combined with the PD-1 Inhibitor Camrelizumab in the Treatment of Primary Liver Cancer Caused Hemorrhagic Exfoliative Gastritis

Hong Chen<sup>a</sup> Zihua Wang<sup>b</sup> Chunhua Wang<sup>c</sup>

<sup>a</sup>Department of Clinical Pharmacy, Bethune International Peace Hospital, Shijiazhuang, China;

<sup>b</sup>Department of Oncology, Bethune International Peace Hospital, Shijiazhuang, China;

<sup>c</sup>Department of Gastroenterology, Bethune International Peace Hospital, Shijiazhuang, China

## Keywords

Lenvatinib · Camrelizumab · Hemorrhagic exfoliative gastritis · Primary liver cancer · Programmed cell death protein · Case report

## Abstract

**Introduction:** Patients with advanced primary liver cancer often lose the opportunity for surgery when they are found, and the treatment options are limited. Lenvatinib, as a multi-target tyrosine kinase inhibitor, has been used as the first-line treatment for advanced liver cancer. Immune checkpoint inhibitors, such as programmed cell death protein 1 inhibitors, have been successfully used in advanced or metastatic liver cancer. **Case Presentation:** We report a case of combined lenvatinib and the programmed cell death protein 1 inhibitor camrelizumab in the treatment of primary liver cancer, in which the rare complication of full-thickness gastric mucosa exfoliation occurred. To the best of our knowledge, this is the first report of the side effect of hemorrhagic exfoliative gastritis with the combination of lenvatinib and camrelizumab. **Conclusion:** Hemorrhagic exfoliative gastritis is an extremely rare clinical complication. Lenvatinib inhibits vascular proliferation and could cause gastrointestinal perforation, which is considered to be the main factor, but whether camrelizumab plays a role in it or only causes gastrointestinal reactions leading to nausea and vomiting, resulting in gastric mucosal exfoliation bleeding, remains to be further explored.

© 2024 The Author(s).

Published by S. Karger AG, Basel

---

Correspondence to:  
Chunhua Wang, crown99@126.com

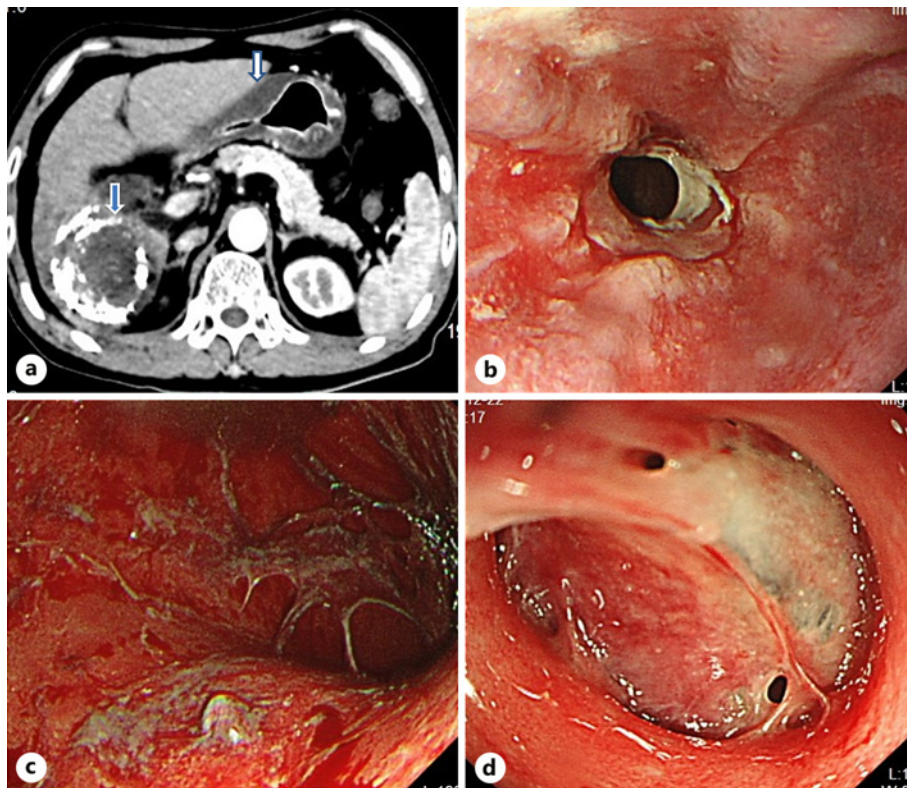
## Introduction

Primary liver cancer is a common malignant tumor of the digestive tract. According to the data of the American Cancer Society, liver cancer is the sixth most common tumor in the world, and its mortality rate accounts for the fourth of all malignant tumors in the world, accounting for 780,000 deaths and 840,000 new cases each year [1]. The malignant degree of the disease is very high, and many patients have no indication for surgery when they go to the hospital.

In recent years, breakthroughs in targeted therapy and immunotherapy have brought more survival options to patients [2, 3]. Lenvatinib, a tyrosine kinase inhibitor (TKI), is the second targeted agent, after sorafenib, approved for first-line treatment of liver cancer [4]. Blocking the interaction between programmed cell death protein 1 (PD-1) and its ligands (PD-L1) is a potential and effective treatment strategy for advanced hepatocellular carcinoma; PD-1 inhibitors such as camrelizumab have emerged. Since antiangiogenesis can improve the tumor microenvironment, it has a significant role in tumor immunotherapy, which can transition from immunosuppression to immune support. Therefore, immunotherapy combined with targeted therapy is becoming a new research trend. The use of these new drugs also brings some rare side effects, which are gradually recognized [5]. Here, we present a rare case of gastric mucosal exfoliation bleeding caused by lenvatinib combined with the PD-1/PD-L1 inhibitor camrelizumab.

## Case Report

A 54-year-old man was admitted to our hospital with nausea, vomiting, and upper abdominal pain of a 10-day duration. He was diagnosed with chronic viral hepatitis B for more than 20 years and was treated with oral entecavir and diagnosed with primary liver cancer 2 years ago. After transcatheter arterial chemoembolization, he received lenvatinib for 20 months (8 mg/d) since April 7, 2020, and immunotherapy with a 3-week cycle of camrelizumab (200 mg/d) for 10 cycles since March 7, 2021, until admission. Before the onset of nausea and vomiting, analgesics, aspirin, alcohol, and other drugs and food that can damage gastric mucosa were not used. Abdominal CT scan 10 days before admission indicated gastric mucosa thickening (Fig. 1a, the blue arrow indicates a liver cancer lesion with iodide deposits, and the white arrow indicates a thickened gastric mucosa). Before the patient stopped lenvatinib and camrelizumab treatment, repeated CT scans showed no expansion of the liver lesion and found metastasis. His vital signs were stable when he was admitted; liver and kidney function, blood routine, coagulation and blood gas analysis showed no obvious abnormalities. Gastroscopy on December 22, 2021, showed that the gastric mucosa from the cardia to the pylorus was exfoliated (Fig. 1b, c). The exfoliated mucosa prolapsed into the duodenum (Fig. 1d). During the gastroscopy, a biopsy was not performed due to the patient's severe reaction and intolerance (timeline of patient treatment and examination showed in Fig. 2). After excluding infectious diseases such as cytomegalovirus infection and autoimmune diseases, hemorrhagic exudative gastritis caused by targeted drugs for primary liver cancer was considered. Then given the fasting and water prohibition, anti-vomiting, inhibition of gastric acid, hemostasis, maintain water and electrolyte balance, and other treatments, the symptoms of abdominal pain, nausea, and vomiting were gradually relieved after discontinuation of lenvatinib and camrelizumab. After 6 months of follow-up, the patient did not have gastrointestinal bleeding and mucosal exfoliation. The patient was not subsequently treated with lenvatinib or camrelizumab but underwent multiple hepatic arterial perfusion embolizations.



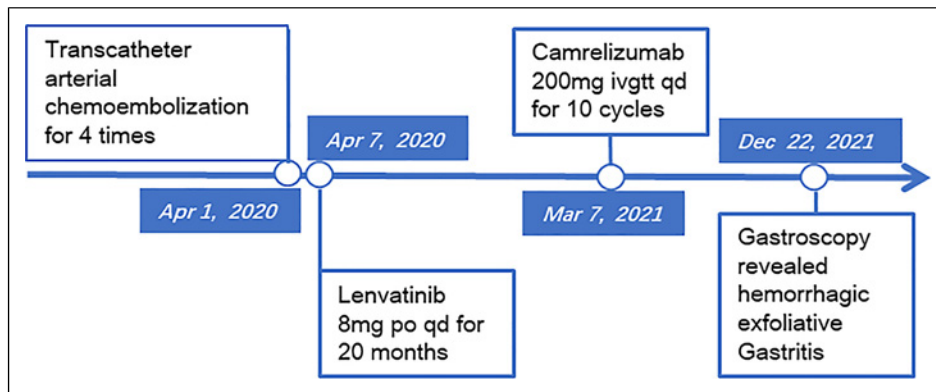
**Fig. 1.** **a** Abdominal CT scan 10 days before admission indicated gastric mucosa thickening. **b, c** Gastroscopy showed that the gastric mucosa from the cardia to the pylorus was exfoliated. **d** Exfoliated mucosa prolapsed into the duodenum.

## Discussion

Lenvatinib is an oral, multi-targeted TKI and inhibits the production of kinases. It can act on vascular endothelial growth factor receptor 1–3, fibroblast growth factor receptor 1–4, and platelet-derived growth factor receptor at the same time. It can effectively control the proliferation of tumor cells and inhibit the tumor angiogenesis [6], added transcatheter arterial chemoembolization could be more effective [7]. Adverse reactions of lenvatinib include hypertension, hand-foot syndrome, bleeding, gastrointestinal perforation, arterial thromboembolism, and hematologic reactions [8].

Camrelizumab is a humanized monoclonal antibody against PD-1, which can specifically bind PD-1 expressed on the surface of CD4+ and CD8+ T cells and B lymphocytes, block the combination of PD-1 and PD-L1, relieve the PD-1 pathway-mediated T-cell immunosuppression, and thus inhibit the immune escape of tumor cells, reestablishing the immune system's ability to monitor and kill tumor cells; this results in a sustained anti-tumor effect [9]. PD-1/PD-L1 inhibitors not only enhance the anti-tumor effect of cellular immunity but also cause immune tolerance imbalance by enhancing the body's normal immune response, which causes immune-related adverse events [10]. The most common adverse reactions were reactive capillary hyperplasia, bilirubin and liver enzymes abnormality, hypothyroidism, proteinuria, etc. [11, 12].

Some studies have found that lenvatinib combined with PD-1/PD-L1 inhibitors may improve the efficacy of PD-1 [13]. Lenvatinib reduces the number of tumor-associated macrophages, which are known as an immunomodulator in the tumor microenvironment.



**Fig. 2.** Timeline of patient treatment and examination.

By reducing tumor-associated macrophages, the expression levels of cytokines and immunomodulatory receptors change, thereby promoting immune activation [14]. Studies have found that compared with sorafenib, lenvatinib combined with camrelizumab not only has a significant effect but also improves the quality of life [6].

In this case, gastroscopy found that the gastric mucosa was removed, but the esophageal mucosa was normal. Combined with abdominal enhanced CT more than 10 days before the gastroscopy, the gastric wall was thickened, while the esophageal wall and intestinal wall were normal, which ruled out the possible thickening of the whole digestive wall caused by gastrointestinal congestion caused by portal hypertension. Severe nausea and vomiting can lead to gastric mucosa exfoliation, but it is difficult to explain why the esophageal mucosa was not involved. After excluding infectious diseases such as cytomegalovirus infection and autoimmune diseases, we hypothesized that mucosal exfoliation was due to abnormal thickening of the stomach wall and nausea. According to the manual of lenvatinib mesylate, the time of gastric perforation and fistulas in various parts of the body ranged from 2 weeks to more than 1 year after the start of treatment, with a median delay of about 3 months [15]. The reason of gastric mucosal exfoliation and oozing blood cannot be excluded to be related to the effect of TKI drugs on inducing microvascular ischemia. The occurrence of gastric mucosal exfoliation and bleeding in this patient has a reasonable time relationship with the use of lenvatinib, and its correlation is considered to be "very possible." There have been reports of fistula and visceral perforation caused by TKI [16, 17]. However, there is no related report of gastric mucosal injury caused by camrelizumab in the manual and relevant literature, but in this case, the patient received camrelizumab after 1 year of lenvatinib, and the gastric mucosal bleeding exfoliation occurred after 6 months of combined application. It has been found that 67% of patients treated with camrelizumab develop reactive cutaneous capillary endothelial proliferation [9]. We wondered whether splanchnic capillary proliferation might also occur, inducing mucosal exfoliation and bleeding after nausea and vomiting. The rare complications of camrelizumab should also be considered. We have no evidence of which drug, or the combination of the two, causes bleeding and exfoliation of the gastric mucosa. Unfortunately, a biopsy was not performed during gastroscopy in this patient. Although inflammation was likely to be observed under the microscope, it was not possible to identify and understand the possible immune cell infiltration. During the treatment, thyroid hormone and adrenal gland tests were not completed. It was not known whether the patient had abnormal hormone levels resulting in damage to the gastrointestinal mucosa caused by the combination of lenvatinib and

camrelizumab. However, this case is reported in order to let more clinicians know the rare complications of the combination of these two drugs, so as to be alert to similar situations during treatment.

## Conclusion

In conclusion, we found hemorrhagic exfoliative gastritis in a patient with primary liver cancer while being treated with lenvatinib and camrelizumab. Hemorrhagic exfoliative gastritis is an extremely rare clinical complication. Lenvatinib inhibits vascular proliferation and could cause gastrointestinal perforation, which is considered to be the main factor, but whether camrelizumab plays a role in it or only causes gastrointestinal reactions leading to nausea and vomiting resulting in gastric mucosal exfoliation bleeding remains to be further explored. The CARE Checklist has been completed by the authors for this case report, attached as online supplementary material (for all online suppl. material, see <https://doi.org/10.1159/000538006>).

## Statement of Ethics

Ethical approval is not required for this study in accordance with local or national guidelines. Written informed consent was obtained from the patient for publication of the details of their medical case and any accompanying images.

## Conflict of Interest Statement

The authors declare that they have no competing interests.

## Funding Sources

No funding was received.

## Author Contributions

Z.H.W. was responsible for the clinical management of the patient and the processing and scientific interpretation of the data. H.C. was responsible for evaluating the data and revising the manuscript, analysis of the specialized literature, the study of the clinical case, and writing the manuscript. C.H.W. was responsible for the analysis of the specialized literature, interpreting the data and evaluating the data, and revising the manuscript. All the authors read and approved the final manuscript.

## Data Availability Statement

All data generated or analyzed during this study are included in this published article and its online supplementary material files. Further enquiries can be directed to the corresponding author.

## References

- 1 Bray F, Ferlay J, Soerjomataram I, Siegel RL, Torre LA, Jemal A. Global cancer statistics 2018: GLOBOCAN estimates of incidence and mortality worldwide for 36 cancers in 185 countries. *CA Cancer J Clin.* 2018;68(6):394–424. doi: [10.3322/caac.21492](https://doi.org/10.3322/caac.21492).
- 2 Rizzo A, Ricci AD, Brandi G. Systemic adjuvant treatment in hepatocellular carcinoma: tempted to do something rather than nothing. *Future Oncol.* 2020;16(32):2587–9. doi: [10.2217/fon-2020-0669](https://doi.org/10.2217/fon-2020-0669).
- 3 Luo XY, Wu KM, He XX. Advances in drug development for hepatocellular carcinoma: clinical trials and potential therapeutic targets. *J Exp Clin Cancer Res.* 2021;40(1):172. doi: [10.1186/s13046-021-01968-w](https://doi.org/10.1186/s13046-021-01968-w).
- 4 Kim BH, Yu SJ, Kang W, Cho SB, Park SY, Kim SU, et al. Expert consensus on the management of adverse events in patients receiving lenvatinib for hepatocellular carcinoma. *J Gastroenterol Hepatol.* 2022;37(3):428–39. doi: [10.1111/jgh.15727](https://doi.org/10.1111/jgh.15727).
- 5 Kudo M. Systemic therapy for hepatocellular carcinoma: latest advances. *Cancers.* 2018;10(11):412. doi: [10.3390/cancers10110412](https://doi.org/10.3390/cancers10110412).
- 6 Laface C, Fedele P, Maselli FM, Ambrogio F, Foti C, Molinari P, et al. Targeted therapy for hepatocellular carcinoma: old and new opportunities. *Cancers.* 2022;14(16):4028. doi: [10.3390/cancers14164028](https://doi.org/10.3390/cancers14164028).
- 7 Rizzo A, Ricci AD, Brandi G. Trans-arterial chemoembolization plus systemic treatments for hepatocellular carcinoma: an update. *J Pers Med.* 2022;12(11):1788. doi: [10.3390/jpm12111788](https://doi.org/10.3390/jpm12111788).
- 8 Zhang ZF, Wang T, Liu LH, Guo HQ. Risks of proteinuria associated with vascular endothelial growth factor receptor tyrosine kinase inhibitors in cancer patients: a systematic review and meta-analysis. *PLoS One.* 2014;9(3):e90135. doi: [10.1371/journal.pone.0090135](https://doi.org/10.1371/journal.pone.0090135).
- 9 Qin S, Ren Z, Meng Z, Chen Z, Chai X, Xiong J, et al. Camrelizumab in patients with previously treated advanced hepatocellular carcinoma: a multicentre, open-label, parallel-group, randomised, phase 2 trial. *Lancet Oncol.* 2020;21(4):571–80. doi: [10.1016/S1470-2045\(20\)30011-5](https://doi.org/10.1016/S1470-2045(20)30011-5).
- 10 Rizzo A, Ricci AD, Brandi G. Atezolizumab in advanced hepatocellular carcinoma: good things come to those who wait. *Immunotherapy.* 2021;13(8):637–44. doi: [10.2217/imt-2021-0026](https://doi.org/10.2217/imt-2021-0026).
- 11 Liao R. Effectiveness of anti-PD-1 for hepatocellular carcinoma. *Lancet Oncol.* 2020;21(6):e293. doi: [10.1016/S1470-2045\(20\)30170-4](https://doi.org/10.1016/S1470-2045(20)30170-4).
- 12 Song P, Zhang D, Cui X, Zhang L. Meta-analysis of immune-related adverse events of immune checkpoint inhibitor therapy in cancer patients. *Thorac Cancer.* 2020;11(9):2406–30. doi: [10.1111/1759-7714.13541](https://doi.org/10.1111/1759-7714.13541).
- 13 Zhu XD, Sun HC. Emerging agents and regimens for hepatocellular carcinoma. *J Hematol Oncol.* 2019;12(1):110. doi: [10.1186/s13045-019-0794-6](https://doi.org/10.1186/s13045-019-0794-6).
- 14 Sun B, Zhang L, Sun T, Ren Y, Cao Y, Zhang W, et al. Safety and efficacy of lenvatinib combined with camrelizumab plus transcatheter arterial chemoembolization for unresectable hepatocellular carcinoma: a two-center retrospective study. *Front Oncol.* 2022;12:982948. doi: [10.3389/fonc.2022.982948](https://doi.org/10.3389/fonc.2022.982948).
- 15 Fujimoto Y, Namisaki T, Takeda S, Murata K, Enomoto M, Takaya H, et al. Leaky gut and severe adverse events in advanced hepatocellular carcinoma treated with lenvatinib. *Anticancer Res.* 2022;42(10):4895–905. doi: [10.21873/anticancer.15995](https://doi.org/10.21873/anticancer.15995).
- 16 Honda S, Saito Y, Sawada K, Hasebe T, Nakajima S, Okumura T. Repeated perforation of the gallbladder in a patient with hepatocellular carcinoma receiving lenvatinib. *Intern Med.* 2020;59(5):657–62. doi: [10.2169/internalmedicine.3806-19](https://doi.org/10.2169/internalmedicine.3806-19).
- 17 Valerio L, Giani C, Agate L, Molinaro E, Viola D, Bottici V, et al. Prevalence and risk factors of developing fistula or organ perforation in patients treated with lenvatinib for radioiodine-refractory thyroid cancer. *Eur Thyroid J.* 2021;10(5):399–407. doi: [10.1159/000514182](https://doi.org/10.1159/000514182).