

Clopidogrel-Associated Thrombotic Thrombocytopenic Purpura following Endovascular Treatment of Spontaneous Carotid Artery Dissection

Jerry A. Rubano¹ Kwan Chen² Brianne Sullivan² James A. Vosswinkel¹ Randeep S. Jawa¹

¹Division of Trauma, Department of Surgery, Stony Brook University School of Medicine, Stony Brook, New York, United States

²Stony Brook University School of Medicine, Stony Brook, New York, United States

Address for correspondence Randeep S. Jawa, MD, Division of Trauma, Department of Surgery, Stony Brook University School of Medicine, HSC Level 18, Room 040, Stony Brook, NY 11794-8191, United States (e-mail: randeep.jawa@stonybrookmedicine.edu).

J Neurol Surg Rep 2015;76:e287–e290.

Abstract

Thrombotic thrombocytopenic purpura (TTP) is a life-threatening multisystem disease secondary to platelet aggregation. We present a patient who developed profound thrombocytopenia and anemia 8 days following initiation of therapy with clopidogrel after stent placement for carotid artery dissection. She did not have a disintegrin and metalloproteinase with thrombospondin domain 13 (ADAMTS 13) deficiency. Management included steroids and therapeutic plasma exchange. Clopidogrel has rarely been associated with TTP. Unlike other causes of acquired TTP, the diagnosis of early clopidogrel-associated TTP is largely clinical given the infrequent reduction in ADAMTS 13 activity.

Keywords

- ▶ clopidogrel
- ▶ TTP
- ▶ carotid
- ▶ stent
- ▶ thrombocytopenia

Introduction

Thrombotic thrombocytopenic purpura (TTP) is a rare multisystem disease, characterized by thrombocytopenia, microangiopathic hemolytic anemia, neurologic abnormalities, renal abnormalities, and fever.^{1–4} However, only thrombocytopenia and microangiopathic hemolytic anemia are required for diagnosis.³ Only 35% of patients have neurologic changes; these are subtle (i.e., headaches and confusion) and can easily be missed in neurosurgical patients with altered baseline levels of consciousness.^{2,3} Generally, noncongenital TTP is secondary to autoantibody mediated reduction in activity of a disintegrin and metalloproteinase with thrombospondin domain 13 (ADAMTS 13), a metalloproteinase that degrades von Willebrand factor (vWF).^{3,5} Reduced vWF proteolysis results in platelet aggregation with consequent microvascular thrombosis, thrombocytopenia, and hemolytic anemia.⁶ Although there have been case series of clopidogrel-associated TTP in the cardiac literature, there has been little discussion in the

neurointerventional literature. We discuss a patient who likely developed TTP following clopidogrel administration after carotid artery stenting, along with its unique features.

Case Report

A middle-aged woman with untreated hypertension presented with altered mental status following an upper respiratory prodrome. She subsequently seized and became obtunded (Glasgow Coma Score 4T). Computed tomography and magnetic resonance imaging of the head and neck demonstrated multiple acute bihemispheric cerebral infarcts and bilateral internal carotid artery (ICA) dissection. Rheumatologic work-up for vasculitis was negative. Cerebral angiography demonstrated left ICA occlusion just distal to carotid bifurcation and a high-grade dissection of the entire extracranial right ICA. The right ICA dissection was managed with stenting (Carotid Wallstent Monorail Endoprosthesis, Boston Scientific, Marlborough, Massachusetts, United States) and Pipeline Embolization Device (Covidien-ev3, Plymouth,

received
June 25, 2015
accepted
August 19, 2015
published online
October 25, 2015

DOI <http://dx.doi.org/10.1055/s-0035-1566127>.
ISSN 2193-6358.

© 2015 Georg Thieme Verlag KG
Stuttgart · New York

License terms



Minnesota, United States) placement from the cavernous to the distal cervical right ICA. Intraoperatively, the patient received heparin and abciximab. Postoperatively (hospital day [HD] 2), the patient was started on clopidogrel and aspirin (–Table 1). On HD 3, a bifrontal craniectomy was performed for cerebral edema.

Clopidogrel was held on days 4 and 5 because of the craniectomy. On HD 6 the clopidogrel response time (P2Y12 reaction units [PRU]) was nontherapeutic at 385; hence she was reloaded. Subsequent clopidogrel dosing was based on daily PRU measurements. On HD 9, her PRU decreased to 178 (therapeutic range < 194) so she was maintained on 75 mg clopidogrel daily. Clopidogrel was stopped after administration on HD 10 because of new profound thrombocytopenia with a platelet count of 46,000/μL with subsequent nadir to 3,000/μL (–Fig. 1). Petechial rash was noted on both arms. Four platelet pheresis units were transfused that day, with an increase of platelets to 15k/μL. Hemoglobin decreased to 6.3 g/dl (from 8.3 g/dL on HD 9). Hence she was transfused 3 units of packed red blood cells.

Hematologic work-up demonstrated occasional schistocytes. Mildly increased lactate dehydrogenase, alanine transferase, and aspartate aminotransferase levels were noted. Haptoglobin and D-dimer levels were elevated. Total and indirect bilirubin, international normalized ratio, partial thromboplastin time, and fibrinogen levels were within normal limits. Serum creatinine level remained within normal limits. Her maximum temperature was 40.1°C on

HD 10. Her neurologic status was unchanged. Given subsequent concern for TTP, an ADAMTS13 level was sent; it was normal. Her Rose and Eldor score was 6, consistent with severe TTP. Intravenous methylprednisolone was started on HD 10 and gradually tapered off. Therapeutic plasma exchange (TPE) was begun on HD 11 and performed daily until HD 15. Her platelet counts increased from 47,000/μL after TPE on HD 11 to 242,000/μL on HD 15. Aspirin was resumed on HD 15. Her neurologic status remained unchanged.

Discussion

Following carotid and coronary artery stenting, thienopyridines and aspirin are prescribed to reduce the rate of stent thrombosis and consequent major complications.^{7–9} All three thienopyridines (ticlopidine, clopidogrel, and prasugrel) have been linked to TTP. Ticlopidine has the highest reported incidence of TTP at 1 case per 1,600 to 5,000 treated patients.^{6,10} Clopidogrel-mediated TTP is rare, with 11 cases reported among 3 million patients between 1998 and 2001 and 197 reported cases by 2011.^{4,10} As noted in our patient, clopidogrel-associated TTP generally occurs within 2 weeks of therapy.⁴ In early thienopyridine-associated TTP (< 2 weeks), the mechanism is not known but involves microvascular endothelial cell damage.⁶ The mechanism may be nonimmunologic because no antibodies to ADAMTS13 have been reported in clopidogrel-associated TTP compared with 100%

Table 1 Hospitalization course

HD	Notes	Tmax, °C	Aspirin dose, mg	Clopidogrel dose, mg	PRU	Hgb, g/dL	Platelets, k/mL	Cr, peak, mg/dL	PRBCs transfused	Platelet pheresis transfused	TPE
1	Admit	38.2	–	–	–	13.6	221	0.6	–	–	–
2	RICA stent	38.6	300	600	–	11.0	199	.43	–	–	–
3	Craniectomy	38.5	325	75	–	9.9	161	0.44	–	1	–
4		38.7	–	–	–	8.8	145	0.55	–	–	–
5		39	325	–	–	9.1	171	0.56	–	–	–
6	PEG, trach	38.9	325	300	385	8.1	194	0.72	–	–	–
7		38.8	325	375	361	7.1	180	0.58	–	–	–
8		38.5	325	675	318	8.5	251	0.58	–	–	–
9		39.1	325	75	178	8.3	253	0.60	–	–	–
10		40.1	325	75	–	7.4 to 6.3	46 to 3	0.78	1	4	–
11		38.8	–	–	–	9.7	47	0.67	2	–	1
12		38	–	–	–	9.6	67	0.52	–	–	1
13		38.2	–	–	–	10	142	0.55	–	–	1
14		38.4	–	–	–	9.1	170	0.52	–	–	1
15		37.9	325	–	–	9.5	242	0.49	–	–	1

Abbreviations: Cr, creatinine; HD, hospital day; Hgb, hemoglobin; PEG, percutaneous endoscopic gastrostomy; PRBCs, packed red blood cells; PRU, P2Y12 reaction units; RICA, right internal carotid artery; Tmax, maximal temperature; TPE, therapeutic plasma exchange; trach, tracheostomy.

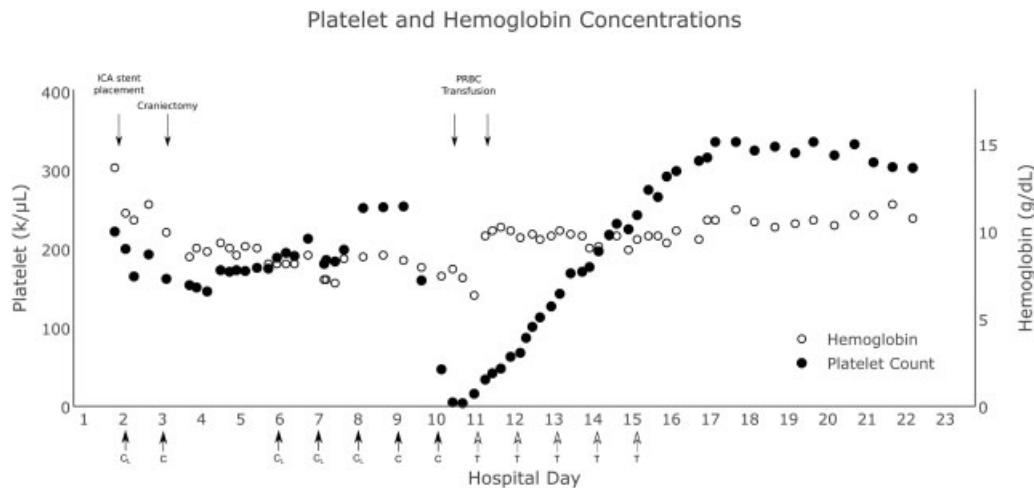


Fig. 1 C, clopidogrel maintenance dose, C_L, clopidogrel load; P, Plavix administered; T, therapeutic plasma exchange.

in 30 cases of ticlopidine-associated TTP.¹⁰ Notably, ADAMTS13 activity deficiency has only been reported in a minority (0–22%) of clopidogrel-associated TTP cases compared with severe deficiency in 80 to 100% of ticlopidine-induced TTP and virtually all cases of idiopathic TTP.^{3,5,10,11} Hence clopidogrel-associated TTP appears to be primarily a clinical diagnosis. To this end, the Rose and Eldor scoring system, based on platelet count, hemoglobin, serum creatinine, and neurologic function, has been used to assess the likelihood of TTP; a score ≥ 4 of 8 indicates a high probability of TTP.^{1,4}

Given the highly thrombogenic nature of the Pipeline devices, as used in this case, antiplatelet therapy was guided by PRU. Because clopidogrel is a prodrug and patients are variably responsive, reloading may be performed. It has been shown to overcome platelet nonresponsiveness, with reduced rates of myocardial infarction, stent thrombosis, and cardiovascular death following cardiac stenting.^{12–14}

Management recommendations for clopidogrel-associated TTP are based on case reports. Clopidogrel should be discontinued. The role of TPE is unclear. Unlike cases of thienopyridine-associated TTP occurring after 2 weeks of therapy, where TPE dramatically improves survival (84% versus 38%), in patients treated with clopidogrel for < 14 days who had TTP ($n = 26$), survival was 70% with TPE and 66.7% without TPE.¹¹ Additional recommendations that are not specific to early thienopyridine-associated TTP include (1) continue TPE for at least 2 days after platelet count > 150k/ μ L; (2) avoid platelet transfusion in the absence of life-threatening bleeding; (3) administer high-dose steroids and folic acid; (4) consider aspirin and prophylactic dose low-molecular-weight heparin when platelet count is > 50k/ μ L; (5) PRBC transfusion as needed; and (6) advise patients of possibility of relapse.^{2–4}

Conclusions

Clopidogrel-associated TTP generally occurs within 2 weeks of the initial dose of clopidogrel. Because there is frequently no ADAMTS13 activity deficiency, diagnosis is primarily clinical,

such as the Rose and Eldor score. Management is largely based on case reports. To our knowledge, this phenomenon has not been described in the neurocritical care literature. Given the frequency of neurointerventional endovascular procedures and the consequent need for dual antiplatelet therapy, this uncommon side effect must be recognized.

Financial Disclosure

Randeep S. Jawa received a Stony Brook University Department of Surgery Research Grant to evaluate vitamin D binding protein in mice.

References

- Rose M, Rowe JM, Eldor A. The changing course of thrombotic thrombocytopenic purpura and modern therapy. *Blood Rev* 1993; 7(2):94–103
- George J, Leung L, Timauer J. Diagnosis of thrombotic thrombocytopenic purpura-hemolytic uremic syndrome in adults. Available at: http://www.uptodate.com.proxy.library.stonybrook.edu/contents/diagnosis-of-thrombotic-thrombocytopenic-purpura-hemolytic-uremic-syndrome-in-adults?source=search_result&search=ttp+diagnosis&selectedTitle=1-150. Accessed May 27, 2015
- Scully M, Hunt BJ, Benjamin S, et al; British Committee for Standards in Haematology. Guidelines on the diagnosis and management of thrombotic thrombocytopenic purpura and other thrombotic microangiopathies. *Br J Haematol* 2012;158(3): 323–335
- Bennett CL, Connors JM, Carwile JM, et al. Thrombotic thrombocytopenic purpura associated with clopidogrel. *N Engl J Med* 2000; 342(24):1773–1777
- Verbij FC, Fijnheer R, Voorberg J, Sorvillo N. Acquired TTP: ADAMTS13 meets the immune system. *Blood Rev* 2014;28(6): 227–234
- Zakarija A, Kwaan HC, Moake JL, et al. Ticlopidine- and clopidogrel-associated thrombotic thrombocytopenic purpura (TTP): review of clinical, laboratory, epidemiological, and pharmacovigilance findings (1989–2008). *Kidney Int Suppl* 2009; (112):S20–S24

- 7 Ricotta JJ, Aburahma A, Ascher E, Eskandari M, Faries P, Lal BK; Society for Vascular Surgery. Updated Society for Vascular Surgery guidelines for management of extracranial carotid disease. *J Vasc Surg* 2011;54(3):e1–e31
- 8 Liapis CD, Bell PR, Mikhailidis D, et al; ESVS Guidelines Collaborators. ESVS guidelines. Invasive treatment for carotid stenosis: indications, techniques. *Eur J Vasc Endovasc Surg* 2009;37(4, Suppl):1–19
- 9 Bell B, Layland J, Poon K, Spaulding C, Walters D. Focused clinical review: periprocedural management of antiplatelet therapy in patients with coronary stents. *Heart Lung Circ* 2011;20(7):438–445
- 10 Jacob S, Dunn BL, Qureshi ZP, et al. Ticlopidine-, clopidogrel-, and prasugrel-associated thrombotic thrombocytopenic purpura: a 20-year review from the Southern Network on Adverse Reactions (SONAR). *Semin Thromb Hemost* 2012;38(8):845–853
- 11 Bennett CL, Kim B, Zakarija A, et al; SERF-TTP Research Group. Two mechanistic pathways for thienopyridine-associated thrombotic thrombocytopenic purpura: a report from the SERF-TTP Research Group and the RADAR Project. *J Am Coll Cardiol* 2007;50(12):1138–1143
- 12 Matetzky S, Fefer P, Shenkman B, Varon D, Savion N, Hod H. Effectiveness of reloading to overcome clopidogrel nonresponsiveness in patients with acute myocardial infarction. *Am J Cardiol* 2008;102(5):524–529
- 13 Tan LA, Keigher KM, Munich SA, Moftakhar R, Lopes DK. Thromboembolic complications with Pipeline Embolization Device placement: impact of procedure time, number of stents and pre-procedure P2Y12 reaction unit (PRU) value. *J Neurointerv Surg* 2015;7(3):217–221
- 14 Price MJ, Angiolillo DJ, Teirstein PS, et al. Platelet reactivity and cardiovascular outcomes after percutaneous coronary intervention: a time-dependent analysis of the Gauging Responsiveness with a VerifyNow P2Y12 assay: Impact on Thrombosis and Safety (GRAVITAS) trial. *Circulation* 2011;124(10):1132–1137