

## Case report

# Successful pregnancy following myomectomy for uterine smooth muscle tumor of uncertain malignant potential: A case report and review of the literature



Jessica E. Campbell, Jennifer F. Knudtson, Philip T. Valente, Randal D. Robinson, Edward R. Kost\*

The University of Texas Health and Science Center San Antonio, San Antonio, Texas, United States

## ARTICLE INFO

### Article history:

Received 21 June 2015

Received in revised form 15 July 2015

Accepted 30 July 2015

Available online 7 August 2015

### Keywords:

STUMP

Smooth muscle tumors

Leiomyomata

Atypical leiomyoma

Pregnancy

## 1. Introduction

According to the 2003 World Health Organization classification, uterine smooth muscle tumors that cannot be definitively diagnosed as benign or malignant should be termed smooth muscle tumors of uncertain malignant potential or STUMP (Hendrickson et al., 2003). STUMPs are rare smooth muscle neoplasms with a clinical behavior between benign leiomyomas and frankly malignant leiomyosarcoma. Patients with leiomyomas, STUMPs, and leiomyosarcomas present with similar clinical symptoms which include abnormal uterine bleeding, pelvic pain, and pelvic pressure (Ip et al., 2010). Preoperative diagnosis is based on findings of an enlarged uterus on pelvic examination and/or radiographic imaging. Conventional surgical treatment includes myomectomy or hysterectomy. In women desiring fertility myomectomy is commonly performed. The finding of a STUMP tumor in myomectomy specimens has been well described (Vilos et al., 2012). Pregnancy after the diagnosis of a STUMP treated with myomectomy has not been previously reported. In the current case we describe a successful pregnancy after a preconceptually diagnosed STUMP. We present recommendations for counseling and management of patients with STUMPs who desire fertility.

## 2. Case report

A 41 year-old female Gravida 5 Para 4014 presented with heavy bleeding and pelvic pain with a known history of uterine leiomyomata. She had a new partner and wanted to maintain her fertility. Physical exam was notable for a 20 week size uterus with an 8 cm anterior fibroid. Ultrasound revealed a 7.8 cm × 7.1 cm uterine leiomyoma that impinged on the cavity. An endometrial biopsy showed late secretory endometrium. An abdominal myomectomy was performed via an eight centimeter Pfannenstiel incision with excision of a 10 cm and a 4 cm uterine leiomyoma. The pelvic organs and peritoneal surfaces were otherwise normal. After the surgery, the patient's uterus was noted to be 10 week sized. Pathology of the smaller uterine tumor showed a smooth muscle tumor with focal, mild, cytologic atypia, apoptotic cell necrosis and increased mitotic activity with up to 9 MF per 10 HPF (Figs. 1,2) consistent with diagnosis of STUMP. Immunohistochemical staining for p53 and p16 was negative (Fig. 3). The patient conceived spontaneously 6 months after her myomectomy. Her pregnancy was uncomplicated. She presented to labor and delivery at 37 weeks in labor and underwent a repeat cesarean section and tubal ligation with delivery of a viable infant with APGARs 9 and 10 with a weight of 3338 g. During the surgery, the surgeons were unable to exteriorize the uterus due to suspected intramural and fundal myomas, and pelvic adhesive disease. Two years from the initial diagnosis of STUMP and one year since delivery, she underwent a total abdominal hysterectomy without complications. The intraoperative findings included an eight week size uterus, normal ovaries and fallopian tubes and no evidence of metastatic disease. Final pathology showed no residual STUMP. She is alive and without recurrent tumor 4 years from her initial diagnosis.

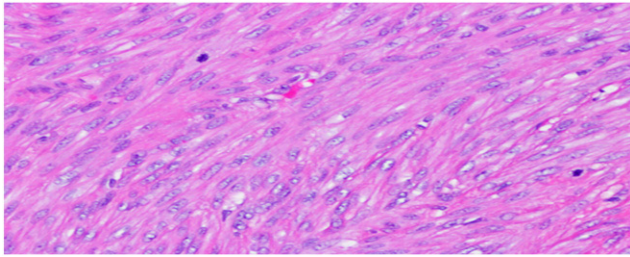
## 3. Discussion

A literature search from January 1960 up to April 2015 was performed in PubMed and Medline databases without language restriction. All articles were initially screened for title and abstract and full texts of eligible articles were subsequently selected. The search terms were “smooth muscle tumor of uncertain malignant potential”, “pregnancy”, “leiomyomata”, and “typical leiomyomata”.

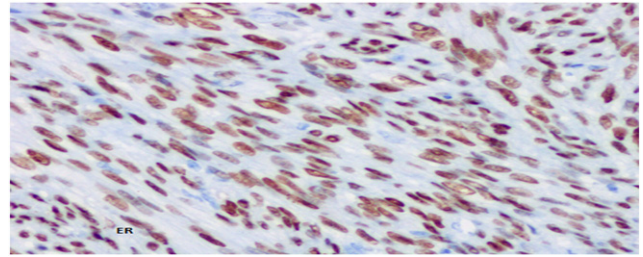
Five case reports were found and are summarized in Table 1. In the first two cases the STUMPs were diagnosed during pregnancy and

\* Corresponding author at: Department of Obstetrics and Gynecology, Division of Gynecologic Oncology, University of Texas Health and Science Center at San Antonio, 7703 Floyd Curl Drive, San Antonio, TX 78229, United States.

E-mail address: [kost@UTHSCSA.edu](mailto:kost@UTHSCSA.edu) (E.R. Kost).



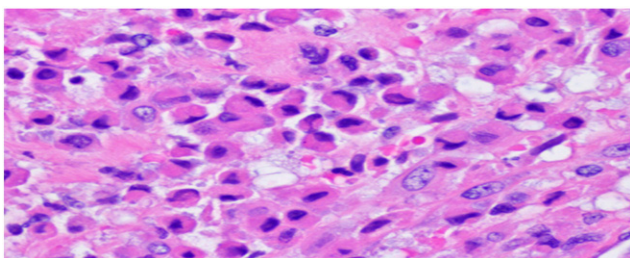
**Fig. 1.** Mild focal atypia and increased mitotic rate are seen (100 $\times$ , hematoxylin & eosin).



**Fig. 3.** Stump is ER positive, p16 and p53 negative (immunoperoxidase, 200 $\times$ ).

therefore did not qualify as preconceptually diagnosed STUMP. In cases 3, 4, and 5 the smooth muscle tumors were not actually STUMPs, demonstrating the difficulty with nomenclature of uterine smooth muscle tumors. Bizarre leiomyomata and mitotically active leiomyomas are variants of benign leiomyomata with no malignant potential and should not be classified as STUMP (Ip et al., 2010; Downes & Hart, 1997). Different types of smooth muscle tumors are discussed in Table 2. The rarity of pregnancy occurring after the diagnosis of STUMP is likely related to advanced maternal age at diagnosis, infrequency of these tumors, and the decision to have hysterectomy once the diagnosis of STUMP is made. Our current case does show that pregnancy is possible after the diagnosis of a STUMP.

The current case highlights the necessity of a multidisciplinary management approach. The role of the gynecologic oncologist centers upon counseling concerning the risk of STUMP recurrence. Depending on the definition of STUMP used in the particular study, the recurrence rates vary from 7.3 to 26.7% (Guntupalli et al., 2009; Peters et al., 1994). Ip et al. performed an evaluation of all published studies that used the same Stanford 3-feature diagnostic criteria for STUMP; cytologic atypia, mitotic count, and coagulative tumor cell necrosis (CTCN) (Ip et al., 2010). This review identified 91 cases of STUMP with 10 recurrences, for a recurrence rate of 11%. Of the recurrences, 67% recurred as leiomyosarcoma with significant CTCN, and 80% had metastatic sites out of the pelvis including lymph nodes, lung, bone, liver, and omentum. The average time to recurrence was 51 months with a range of 15 months to 9 years. Specific information regarding the risk of STUMP recurrence after treatment by myomectomy is provided in the review by Vilos et al. (Ip et al., 2010). Among 76 patients with STUMP treated with myomectomy, 5 (6.6%) experienced recurrence of disease. Several observations can be made from these data. The majority of STUMP recurrences reported in the literature had pathologic characteristics consistent with a diagnosis of leiomyosarcoma (Ip et al., 2010; Yoon et al., 2011). Recurrences following hysterectomy frequently involved metastatic sites outside of the pelvis. However in patients who have recurrence after myomectomy the recurrences are isolated to the uterus in more than 50% of the cases. Isolated uterine recurrence after myomectomy may actually represent “persistent disease” resulting from incomplete excision of the STUMP. The majority of STUMP recurrences are classified as late recurrence occurring greater than 5 years



**Fig. 2.** Apoptotic necrosis is seen, no evidence of coagulative tumor cell necrosis (100 $\times$ , hematoxylin and eosin).

from diagnosis. Fortunately the salvage rate for the patients who recur is excellent with virtually all patients alive with disease or have no evidence of disease. It is conceivable that a small subset of STUMPs undergoes progression or malignant degeneration from STUMP to a leiomyosarcoma similar to progression of serous borderline tumors progressing to low grade serous adenocarcinoma (Dehari et al., 2007). An alternative explanation is that a subset of the STUMPs which recurred was actually low grade leiomyosarcoma at initial diagnosis. The late recurrences and excellent survival are consistent with the behavior of low grade leiomyosarcoma (Veras et al., 2011). Certain histologic features such as extensive CTCN should be considered a warning sign for potential recurrence. Recent studies have suggested that the use of immunohistochemical stains, including p16 and p53 may help to identify the STUMPs at greater risk of recurrence (Atkins et al., 2008; Ip et al., 2009). Although cases of STUMPs with recurrence have been associated with diffuse immunoreactivity for p16 and p53, the number of cases in these studies is small, and further study is required to confirm the reliability of employing such markers. In the current case there was no CTCN and immunohistochemistry showed negative staining for p16 and p53.

In those patients who desire fertility the risks of STUMP recurrence must be weighed against the realistic expectation of pregnancy. Fortunately most STUMPs have a favorable prognosis with a 5 year overall survival rate of 92% (Peters et al., 1994). However, patients must also be counseled that pregnancy is quite rare after the diagnosis of STUMP likely due in part to advanced maternal age. At the current time there is no reliable method to predict the clinical behavior of STUMPs. Based on the available information several risk factors for recurrence can be proposed including extensive CTCN, possibly the expression of p53 and p16, and incomplete excision at myomectomy. We recommend thorough evaluation of the surgical material by a gynecologic pathologist to assure leiomyosarcoma is ruled out. The surgical margins must be carefully assessed in the myomectomy specimen as positive margins could result in uterine recurrence or persistence. Adequate surgical material should be available to the pathologist. Ideally the smooth muscle lesion should be removed with the capsule intact. Extensive morcellation of the specimens can make pathologic assessment difficult. If there is uncertainty concerning the surgical margin consideration should be given to re-operation with re-resection to assure negative margins. Finally patients should be counseled that most recurrences generally carry a good prognosis but deaths have been reported. The recurrent tumors frequently recur as leiomyosarcoma which can be aggressive tumors. With respect to surveillance we recommend surveillance similar to that for uterine sarcoma. We recommend that a completion hysterectomy be performed once childbearing is completed due to the risk of late uterine recurrences. Evaluation for STUMP recurrence should be performed before pregnancy is attempted. Treatment of recurrent and metastatic STUMP during pregnancy should be avoided. As far as surveillance for recurrence during pregnancy ionizing radiation should be avoided. Imaging modalities that have been used to monitor uterine leiomyomas during pregnancy include ultrasound and MRI, however differentiation between leiomyomas, STUMPs, and leiomyosarcoma on imaging is not possible. In summary, good clinical outcomes for both mother

**Table 1**  
Literature review of STUMP in pregnancy.

Source	Age	Presentation	Treatment	Gross findings	Microscopic findings	Pregnancy outcome	Follow up
Clauss et al. (2010)	30	Incidental finding at C-section	Myomectomy at time of C-section	2.7 cm leiomyoma	STUMP	Live birth 27 weeks by C-section.	16 months NED
Vranjes et al. (2011)	37	Uterine mass noted at 14 weeks EGA	Myomectomy at 18 weeks, C-section at 33 weeks	35 cm fundal myoma-like tumor, 4250 g	STUMP	Live birth 33 weeks by C-section-hysterectomy.	No residual STUMP
Takeda et al. (2011)	30	Abnormal uterine lesions on ultrasound	Laparoscopic excision	4.3 cm tumor excised in pieces, 20 g	Bizarre leiomyoma	Conceived 7 months later. Live birth 37 weeks by C-section	No data
Dgani et al. (1998)	35	Prolapsed myoma	Vaginal myomectomy	Typical leiomyoma	Mitotically active leiomyoma	Conceived 3 months later. Live birth.	>16 months NED
Downes & Hart (1997)	ND	Symptomatic fibroid uterus	Myomectomy	Typical leiomyoma	Bizarre leiomyoma	2 subsequent live births by C-section	73 months NED
Campbell et al.	40	Symptomatic fibroid uterus	Abdominal myomectomy	10 cm and 4 cm leiomyomas	STUMP	Conceived 12 months later, Live birth by C-section	Hysterectomy no STUMP, 24 months NED

ND – no data; NED – no evidence of disease; EGA – estimated gestational age.

**Table 2**  
Types of smooth muscle tumors.  
Adapted from Dgani et al.

Diagnosis	Atypia	CTCN	MF/10 HPF
Leiomyoma	None–mild	None	0–4
Leiomyoma with increased mitotic activity	None–mild	None	Greater than 5
Atypical leiomyoma	Moderate–severe	None	0–9
Smooth muscle tumor of uncertain malignant potential	None–mild	Present	0–9
Leiomyosarcoma	None–mild	Present	Greater than 10
Leiomyosarcoma	Moderate–severe	None	Greater than 10
Leiomyosarcoma	Moderate–severe	Present	Any

CTCN: coagulative tumor cell necrosis; MF: mitotic figure; HPF: high power field.

and baby are possible after a fertility sparing myomectomy and successful pregnancy in a patient diagnosed preconceptually with a STUMP.

Written informed consent was obtained from the patient for publication of this case report and accompanying images. A copy of the written consent is available for review by the Editor-in-Chief of this journal on request.

The authors have no conflicts of interest to disclose.

## References

Hendrickson, M.R., Tavassoli, F.A., Kempson, R.L., et al., 2003. Mesenchymal tumors and related lesions. In: Tavassoli, F.A., Devilee, P. (Eds.), *World Health Organization Classification of Tumors: Pathology and Genetics of Tumors of the Breast and Female Genital Organs*. IARC Press, Lyon, pp. 236–243.

Ip, P.P., Tse, K.Y., Tam, K.F., et al., 2010. Uterine smooth muscle tumors other than the ordinary leiomyomas and leiomyosarcomas: a review of selected variants with emphasis on recent advances and unusual morphology that may cause concern for malignancy. *Adv. Anat. Pathol.* 17, 91–112.

Vilos, G.A., Marks, J., Ettler, H.C., et al., 2012. Uterine smooth muscle tumors of uncertain malignant potential: diagnostic challenges and therapeutic dilemmas. Report of 2 cases and review of the literature. *J. Minim. Invasive Gynecol.* 19 (3), 288–295 (May–Jun).

Clauss, S., Holler, S., Hegi, L., et al., 2010. “STUMP” (smooth muscle tumor of uncertain malignant potential), a tumor of the uterus in pregnancy – a diagnostic and therapeutic challenge. *Z. Geburtshilfe Neonatol.* 214, 74–77.

Vranjes AM, Sijanovic S, Vidosavljevic D, Kasac Z, Zuljevic KA. Surgical treatment of large smooth muscle tumor of uncertain malignant potential during pregnancy. *Med. Glas., Vol 8, number 2, 2011, p 290-1. (August)*

Takeda, A., Imoto, S., Mori, M., Nakamura, H., 2011. Successful pregnancy outcome after laparoscopic-assisted excision of a bizarre leiomyoma: a case report. *J. Med. Case Rep.* 5, 344.

Dgani R, Piura B, Ben-Baruch G et al. Clinical pathological study of leiomyomas with high mitotic activity. *Acta Obstet. Gynecol. Scand.* 1998;77: 74–77.

Downes KA, Hart WR. Bizarre leiomyomata of the uterus: a comprehensive pathologic study of 24 cases with long term follow-up. *Am. J. Surg. Pathol.* Volume 21(11), 1997, pp 1261–1270. (November)

Guntupalli, S.R., Rameriz, P.T., Anderson, M.L., et al., 2009. Uterine smooth muscle tumor of uncertain malignant potential: a retrospective analysis. *Gynecol. Oncol.* 113 (3), 324–326.

Peters III, W.A., Howard, D.R., Anderson, W.A., et al., 1994. Uterine smooth-muscle tumors of uncertain malignant potential. *Obstet. Gynecol.* 83, 1015–1020.

Yoon, B.S., Seong, S.J., Park, H., 2011. Rapid recurrence of uterine smooth muscle tumor of uncertain malignant potential as leiomyosarcoma. *Int. J. Obstet. Gynecol.* 113, 244–245.

Dehari, R., Kurman, R.J., Logani, S., LeM, S., 2007. The development of high-grade serous carcinoma from atypical proliferation (borderline) serous tumors and low-grade micropapillary serous carcinoma: a morphologic and molecular genetic analysis. *Am. J. Surg. Pathol.* 31 (7), 1007–1012 (Jul).

Veras, E., Zivanovic, O., Jacks, L., et al., 2011. “Low-grade leiomyosarcoma” and late-recurring smooth muscle tumors of the uterus: a heterogeneous collection of frequently misdiagnosed tumors associated with an overall favorable prognosis relative to conventional uterine leiomyosarcoma. *Am. J. Surg. Pathol.* 35 (11), 1626–1637 (Nov).

Atkins, K.A., Arronte, N., Darus, C.J., et al., 2008. The use of p16 in enhancing the histologic classification of uterine smooth muscle tumors. *Am. J. Surg. Pathol.* 32, 98–102.

Ip, P.P., Cheung, A.N., Clement, P.B., 2009. Uterine smooth muscle tumors of uncertain malignant potential (STUMP). A clinicopathologic analysis of 16 cases. *Am. J. Surg. Pathol.* 33 (7), 992–1004.