

# Guillain-Barré syndrome and COVID-19: association or coincidence

Aislinn Gale, Suganya Sabaretnam, Asher Lewinsohn

Anaesthetics and Intensive Care Medicine, Luton and Dunstable University Hospital NHS Foundation Trust, Luton, UK

## Correspondence to

Dr Aislinn Gale;  
aislinn.gale@nhs.net

Accepted 29 October 2020

## SUMMARY

COVID-19 is a novel disease best known to cause a cough, fever and respiratory failure. Recently, it has been recognised that COVID-19 may present in multi-systemic ways which can cause diagnostic uncertainty or error. We present a patient who attended hospital with features of Guillain-Barré syndrome (GBS) before developing clinical and radiological findings of COVID-19. While the authors recognise that neurological complications have been reported following COVID-19 infection, to their knowledge this report describes a unique presentation of GBS without preceding COVID-19 symptoms.

Since these conditions may have considerable overlapping features including respiratory failure and (following prolonged critical care admission) profound weakness, it is possible that one diagnosis may be overlooked. Raising awareness of a possible association between these conditions is important so both are considered allowing appropriate investigations to be arranged to optimise the chance of neurological recovery and survival, while also protecting staff from potentially unrecognised COVID-19.

## BACKGROUND

As a novel disease, the spectrum of effects associated with infection by 2019-nCoV-2 (Coronavirus) have not yet been fully established. Although it is widely known to affect the respiratory system, its effects on other systems are only recently becoming recognised (eg, myocarditis and hypercoagulability states).<sup>1,2</sup> The effects of COVID-19 on the neurological system in particular are perhaps the most rare complication, and also the least well understood. This case report aims to expand our understanding and awareness of how COVID-19 can be associated with Guillain-Barré syndrome (GBS) by presenting a patient who attended our facility with progressive neuromuscular weakness following exposure to Coronavirus, who subsequently developed respiratory features and confirmation of this infection by reverse transcription PCR (rt-PCR).

It is well established that COVID-19 may cause progressive respiratory failure by lung parenchyma inflammation without neuromuscular weakness, therefore it is the authors' belief that awareness of this case is particularly important as the diagnosis of GBS may easily be missed in patients who have respiratory failure with an established (or suspected) COVID-19 infection. In these cases, especially where a patient may have already spent a period of time ventilated on intensive care, the global weakness seen may be misattributed to either COVID-19

infection alone, perceived poor physiological reserve or critical illness myopathy. These beliefs may then influence the ongoing decisions for ceilings of care and survival prognostication. Further to that, the authors also believe that awareness of this case is vital in patients with rapid progression (or primary presentation) of ascending paralysis where focusing on the primary neurological impairment may preclude the consideration of an underlying 'silent' COVID-19 infection and therefore subsequent personnel and patient exposure risks.

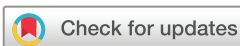The authors hope that by raising awareness of the association between GBS and COVID-19 clinicians will consider both conditions in their differential diagnosis when either condition is complicated by features of the other. This may in turn encourage clinicians to undertake a focused neurological examination in patients with severe COVID-19 in respiratory failure prior to intubation, and if profound weakness or labile blood pressure complicates their critical care admission then specific investigations may be arranged to identify a diagnosis of GBS when present. This will then enable initiation of appropriate treatment to limit disease severity, shorten intensive care stay and improve overall patient outcomes.

## CASE PRESENTATION

A Caucasian man aged 58 years was brought in by ambulance on 9 April reporting a 1 day history of progressive ascending weakness affecting all four limbs and impairing his mobility. This was preceded by a day of numbness spreading from his feet to legs. The patient reported no recent illness and specifically denied any fever, cough, breathlessness, gastrointestinal upset or urinary symptoms. On further questioning, the patient did however report that as his wife had been experiencing coryzal symptoms they had both been self-isolating for the preceding 13 days as recommended by the national Coronavirus public health guidelines at the time.<sup>3</sup>

The only other significant history reported by the patient on admission was of new lumbar back discomfort over the preceding few days but no saddle anaesthesia or changes in continence. He was otherwise functionally independent but was known to have hypertension, hypercholesterolaemia and a myocardial infarction 5 years earlier.

On initial examination, the patient's vital signs were within normal limits and he was afebrile. His cardiovascular and respiratory examinations were unremarkable. His neurological examination demonstrated normal tone throughout all four limbs, power was Medical Research Council (MRC) 5/5 in both arms with no pronator drift and 4/5 in



© BMJ Publishing Group Limited 2020. No commercial re-use. See rights and permissions. Published by BMJ.

**To cite:** Gale A, Sabaretnam S, Lewinsohn A. *BMJ Case Rep* 2020;**13**:e239241. doi:10.1136/bcr-2020-239241

both legs. Plantars were flexor on stimulation and sensation to light touch was objectively normal throughout. There was no facial asymmetry and cerebellar examination was unremarkable, however he was too unstable on his feet to attempt Romberg's test.

On 11 April, the patient suddenly became breathless and bradycardic on lying supine for a CT scan. Power was noted as MRC 1/5 proximally and 4/5 distally in all four limbs and reflexes were absent. There was no facial weakness and eye movements were normal. He had new bulbar dysfunction resulting in a weak cough, difficulty swallowing and dysarthria. Chest expansion was reduced with limited air entry bilaterally. Arterial blood gas analysis at the time on 5 L O<sub>2</sub>/min showed a respiratory acidosis with pH 7.329, PaCO<sub>2</sub> 6.48 kPa, PaO<sub>2</sub> 13.6 kPa, lactate 1.2 mmol/L, HCO<sub>3</sub><sup>-</sup> 23.4 mmol/L, base excess -0.4 and glucose 8.4 mmol/L. He was diagnosed with severe GBS clinically and referred to intensive care for further support including invasive ventilation. While awaiting transfer to the hospital's COVID-19 intubation area, he developed sudden respiratory arrest and was expediently intubated and ventilated.

On arrival to the intensive care unit (ICU), he was prone and arterial gas analysis on FiO<sub>2</sub> 0.85 with positive end-expiratory pressure 14 showed pH 7.27, PaO<sub>2</sub> 9.35 kPa, PaCO<sub>2</sub> 7.19 kPa and HCO<sub>3</sub><sup>-</sup> 22. He was given treatment for GBS, secondary bacterial infection and supportive intensive care management as described below.

The patient gradually improved allowing vasopressor support to be withdrawn. Shortly after this, GBS involvement of the autonomic nerve system became apparent as he developed a labile blood pressure, fluctuating up and down between 220 and 80 mm Hg systolic. He also developed constipation despite regular laxatives and nasogastric feeding.

On 25 April, 14 days after being intubated, a tracheostomy was formed to enable respiratory wean. Neurology review on 26 April after a sedation wean found him appropriate, interacting by turning his head. Oxygen requirement had reduced to FiO<sub>2</sub> 0.28, but he remained on ventilation support. Examination demonstrated bifacial weakness with inability to close eyes, power of shoulder shrug 2/5, finger movements 2/5, lower limbs proximally 2/5 and distally 3-4/5.

By April 28, the patient had weaned from the ventilator and was trialled on a speaking valve. Speech and language assessment found that he had a weak and wet voice with weak tongue movement and quiet speech and was deemed unsafe for a swallow

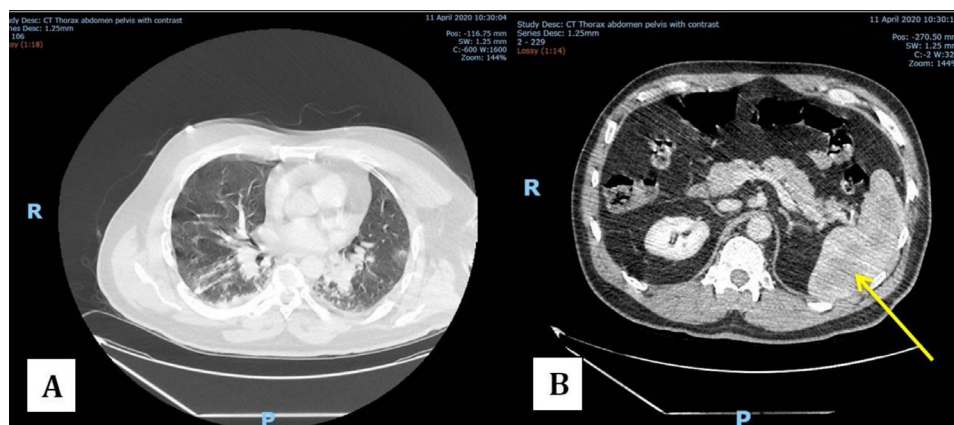
assessment at the time. He was unable to maintain sitting balance but participated in daily physiotherapy to optimise his recovery. By the 27th day of admission, he was stepped down from critical care to the respiratory ward then on 15 May he was discharged to a community rehabilitation unit to continue his recovery.

This patient's history on presentation was typical for GBS describing lumbar back pain and distal acroparaesthesia preceding ascending weakness but without objective sensory loss on examination.<sup>4</sup> An urgent MRI excluded cord compression then a CT was arranged to investigate for an underlying malignancy but during this scan he had acute respiratory decompensation on lying flat which prompted the diagnosis of GBS. GBS is well known to occur following *Campylobacter jejuni* infection,<sup>5</sup> but importantly in his presentation he had no recent symptoms of this infection nor unwell contacts except his wife who had symptoms of COVID-19; therefore, we were suspicious he had been exposed to Coronavirus.

## INVESTIGATIONS

Initial lab investigations on arrival demonstrated a neutrophilia ( $12.03 \times 10^9/L$ ), normal C reactive protein (2.6 mg/L) and low lymphocyte count ( $0.70 \times 10^9/L$ ). Haemoglobin, electrolytes and both renal and liver function tests were within normal limits. Haemoglobin A1c and vitamin B<sub>12</sub> were normal and folate was low (3.3 µg/L). Nasopharyngeal Coronavirus rt-PCR was sent on admission and initially came back negative. An MRI of head and spine showed only minor degenerative disc disease. CT to exclude malignancy demonstrated hyperdense splenic lesions possibly suggestive of lymphoma and lung changes including bilateral groundglass densities, patchy consolidation and nodules, reported as possibly due to COVID-19 (figure 1). We were later informed that these splenic lesions had been noted previously and been characterised as haemangiomas by MRI.

While in ICU further investigations were arranged to ascertain if the suspected diagnosis of GBS could be confirmed and if a precipitant could be identified. Cerebrospinal fluid analysis demonstrated a raised protein of 1.5 g/L but normal glucose, no white or red blood cells, no organisms and negative PCR analysis of potential fungal, viral and bacterial pathogens. There was no evidence of HIV or hepatitis B infection. Coronavirus was detected on tracheal aspirate and both IgG and IgM immunoglobulins to *C. jejuni* were present but no other pathogens were cultured. *Campylobacter* serology was repeated after discharge



**Figure 1** CT scan with contrast of chest abdomen and pelvis on 11 April. (A) Coronal section of the lung showing patchy consolidation and bilateral ground glass densities. (B) Coronal section of the abdomen showing hyperdense lesions in the spleen that prompted further investigation by positron emission tomography scan. The arrow highlights an abnormal region in the spleen.

**Table 1** Nerve conduction study compared with normal reference values

Nerve		Amplitude (mV)		Conduction velocity (m/s)		Latency (ms)	
		Reference	Measured	Reference	Measured	Reference	Measured
Median	Wrist to abductor pollicis brevis	4.2	0.9	47	–	4.7	8.2
Ulnar	Wrist to abductor digiti minimi	7.9	1.7	52	–	3.7	6.0
	Below elbow to wrist	7.9	0.4 (CB)	52	19	3.7	18.9

Reference values stated for amplitude and conduction velocity are the lower limit of the 3rd percentile for normal healthy individuals; matched for age, height and test site as appropriate. Reference values for latency are the upper limit of the 97th percentile for normal healthy individuals matched for age and sex as appropriate.<sup>5</sup>

The table demonstrates how the measured amplitude was significantly reduced in all nerves, the conduction velocity was reduced in the ulnar nerve (not measured in median) and latency was increased in all nerves. These are all expected findings in GBS.

CB, conduction block; GBS, Guillain-Barré syndrome.

from critical care and the trend in serology reported in June weeks after discharge from hospital suggested a recent infection.

Nerve conduction studies on 17 April supported the diagnosis of acute inflammatory demyelinating polyneuropathy, the most common form of GBS. The median and ulnar nerves were both tested at levels below the elbow and, compared with reference values,<sup>6</sup> showed a significant reduction in both amplitude and conduction velocity and also an increased latency (table 1). Spontaneous electromyography of tibialis anterior showed only minimal fibrillation and positive sharp waves indicating mild acute denervation. These findings are consistent with demyelination and mild axonal loss as expected in GBS.

The nasopharyngeal swab for Coronavirus was initially negative, however a known limitation of this test is its sensitivity. Wang compared the sensitivity of different sample sources for Coronavirus and found a sensitivity of 63% for nasal swabs, 32% for pharyngeal, 72% for sputum and 93% for bronchoalveolar lavage.<sup>7</sup> Therefore, it is not unexpected that nasopharyngeal swabs will give false negative results, so when clinical suspicion remains high a repeat sample should be obtained ideally from a source where the sensitivity has been found to be greater. When this was done in our patient the tracheal aspirate confirmed the diagnosis.

### DIFFERENTIAL DIAGNOSIS

The diagnoses of GBS and COVID-19 were both confirmed individually as discussed above, however whether these were unrelated conditions occurring together by coincidence or in association with each other is yet to be established.

Although the cause of GBS may be *C. jejuni* based on the serological results, other precipitants are also plausible including Coronavirus and even lymphoma. GBS is most commonly preceded by an upper respiratory infection caused by a non-specific pathogen 2–4 weeks prior to the onset of weakness.<sup>5</sup> Therefore, in this case, developing GBS 2 weeks after exposure to a respiratory virus such as Coronavirus would not be wholly atypical. *C. jejuni* infection is a well-recognised precipitant of GBS particularly of the axonal neuropathy form.<sup>8</sup> In this case, although serology confirmed recent *C. jejuni* infection, the nerve conduction studies showed a predominantly demyelinating form of GBS therefore, while the authors acknowledge that *C. jejuni* remains a potential cause, other precipitants are also still possible. Other pathogens associated with GBS that were ruled out in this case also include HIV, hepatitis B and cytomegalovirus.

Lymphoma is still being investigated in this case, but the close association in time between the onset of GBS and the exposure to two infectious triggers supports the suggestion of their association, even if this is on the background of an unrecognised and undiagnosed lymphoma. Now we are aware that similar splenic lesions were present 4 years ago, the likelihood of lymphoma is decreasing but further investigations to rule out this diagnosis

are still underway. We note that although GBS is associated with lymphoma, it typically does not precede it.<sup>9</sup> Anderson *et al* describe a case where GBS was diagnosed first, and treatment with intravenous immunoglobulin resulted in worsened neurology that prompted the eventual diagnosis of lymphoma.<sup>10</sup> This is in contrast to our patient who responded well to intravenous immunoglobulin and recovered from GBS without any treatment directed at a potential underlying lymphoma.

### TREATMENT

This patient was admitted to ICU for invasive ventilation after the diagnosis of GBS was made. He was treated with 0.4 g/kg intravenous immunoglobulin for 5 days and piperacillin-tazobactam to cover secondary bacterial infection. Standard supportive intensive care management was provided including nutritional support via nasogastric feeding, sedation, cardiovascular support, stress ulcer prophylaxis, care bundles to prevent both ventilator-associated pneumonia and vascular access line infections alongside high-quality nursing care to prevent soft-tissue injuries and maintain dignity. Due to the increased incidence of thrombotic phenomena observed in critically ill patients with confirmed or suspected COVID-19, a local policy was instituted recommending these patients receive a higher weight-based dose of tinzaparin as venous thromboembolism prophylaxis. This patient was therefore given 125 units/kg tinzaparin, rather than the routine dose of 4500 units for patients of his weight with preserved renal function. When the tracheal aspirate came back positive for Coronavirus, this patient was enrolled in the RECOVERY (Randomised Evaluation of COVID-19 Therapy) trial and randomised to receive dexamethasone.<sup>11</sup>

### OUTCOME AND FOLLOW-UP

By April 28, the patient had weaned from the ventilator and was trialed on a speaking valve. By the 27th day of admission, he was stepped down from critical care to the respiratory ward for ongoing physiotherapy and speech and language therapy. On 15 May, he was discharged to a community rehabilitation unit to continue his recovery, then in early June he returned to his own home.

### DISCUSSION

To the best of the authors' knowledge, this is the first potential case of COVID-19 associated with GBS reported in the UK, although other cases have been reported in Iran, China and Italy.<sup>12–14</sup> This case is important as it highlights and further strengthens our understanding of how, following exposure to Coronavirus, GBS may develop days prior to any typical COVID-19 symptoms like cough, fever or breathlessness.<sup>15</sup> This uniquely differentiates it from the majority of cases previously

reported where symptoms of GBS started after the diagnosis of COVID-19 had been established.

Since both COVID-19 and GBS may result in respiratory failure requiring intensive care support, it is possible for either condition to be overlooked resulting in both inadequate overall management of the patient or potential poor overall prognosis. As this case illustrates, both COVID-19 and GBS may possibly co-exist at the same time in the same patient and if not recognised it can lead to either omission of treatment for GBS with intravenous immunoglobulin or an unacceptable exposure risk to staff and other patients by ventilating a patient with undiagnosed COVID-19 without the appropriate isolation. Notably, this patient had a respiratory arrest and was given ventilatory support when the initial Coronavirus rt-PCR was negative. It is important to increase awareness of the potential association of Coronavirus with GBS to improve the chances of diagnosing both conditions when they co-exist and therefore limiting the risk to the patient, staff and others present.

The authors recognise that the presence of positive *C. jejuni* serology, a known precipitant of GBS, could be seen to undermine the potential association COVID-19 may have had in the development of GBS in this case. However, this association still needs to be considered seriously, especially in view of the fact that 97% of *C. jejuni* infections do not result in GBS,<sup>16</sup> and 22%–53% of GBS cases are known to be precipitated by respiratory tract infections.<sup>17</sup> The clinical presentation and nerve conduction studies in this case are not typical of GBS precipitated by *C. jejuni*, however the exposure to COVID-19, a viral respiratory infection, 13 days prior to developing neurological symptoms is typical. While anecdotal case reports cannot confirm a causative association, the authors believe this patient's disease course demonstrates a plausible association between a novel disease and GBS that should be reported to enable further research to establish the extent of this association definitively.

The authors also note that the other case reports published on this subject do not state their *Campylobacter* serology results at all,<sup>12–14</sup> and the knowledge of a *C. jejuni* infection (in this case) was a retrospective diagnosis made after discharge which therefore could not have influenced the investigations or management decisions made at the time under our care. The learning points from this case are therefore relevant for all patients presenting with GBS during this pandemic as causative organisms cannot be excluded or confirmed acutely, therefore management decisions must be made in context of this potential association with Coronavirus. In turn, it may also be prudent to note from this that the haste to share new information about this novel disease may later be found to have allowed significant omissions (such as waiting for important alternative diagnoses or laboratory tests to be excluded) to have occurred.

Despite the presence of antibodies to *C. jejuni* (a known cause of GBS), this case remains noteworthy to highlight the potential unrecognised association that COVID-19 may have with GBS so that learning points can be shared and the need for national retrospective studies highlighted to establish if the incidence of GBS increased during the COVID-19 pandemic. If there was no change in overall incidence, Coronavirus could be confirmed as an unlikely precipitant of GBS. However, if the incidence did increase during this period, then further analysis could be performed to determine whether Coronavirus in itself is independently associated with GBS or whether it may contribute synergistically in patients co-infected with *C. jejuni* to develop GBS.

Collateral learning from this case highlights how early multidisciplinary working during the COVID-19 pandemic was

effective in enabling timely diagnosis and subsequent treatment of GBS with appropriate early escalation to critical care. Increased neurology consultant support in this case enabled specialist review to occur within a very short time of the patient's clinical deterioration, facilitating early diagnosis and highlighting the need for close observation pending transfer for intubation. Further extensive multidisciplinary team input was vital in this case for the successful outcomes achieved including the input from dietitians, physiotherapists and speech and language therapists to support his recovery and rehabilitation.

### Learning points

- ▶ When patients present with COVID-19 symptoms during the pandemic, take a focused neurological examination to identify concurrent Guillain-Barré syndrome when present.
- ▶ When critically ill patients with COVID-19 are weak, consider Guillain-Barré syndrome as a rare but treatable cause of this, alongside other more common causes including critical illness myopathy.
- ▶ When patients present with signs and symptoms suggestive of Guillain-Barré syndrome during the COVID-19 pandemic, consider them at high risk of being infected with Coronavirus and investigate for this alongside other known precipitants.
- ▶ Be mindful of the imperfect sensitivity of nasopharyngeal swabs and consider doing multiple samples when radiological investigations show typical features of COVID-19.

**Acknowledgements** The authors would like to thank the multidisciplinary critical care team and neurology consultants who supported the diagnosis and management of this patient while on ICU. The authors would particularly like to thank ICU consultants Dr Sivagnanam, Dr Burns, Dr Foldi, Dr Ijaz, Dr Lang, Dr Liu, Dr Raza, Dr Shaw, Dr Spong, Dr Warnapura and Dr Zaidi, alongside neurophysiology consultant Dr Freilich and neurology consultants Dr Batla and Dr Watts.

**Contributors** SS identified the case and the key learning points to be conveyed. She had a significant role in conception and design of the manuscript and obtained images of investigations included. AL contributed to drafting the manuscript and revising it for intellectual content. AG contributed by acquiring and analysing data from hospital records and the literature and also drafting the manuscript. All authors had final approval of the version submitted for publication and agreed to be accountable for the article.

**Funding** The authors have not declared a specific grant for this research from any funding agency in the public, commercial or not-for-profit sectors.

**Competing interests** None declared.

**Patient consent for publication** Obtained.

**Provenance and peer review** Not commissioned; externally peer reviewed.

This article is made freely available for use in accordance with BMJ's website terms and conditions for the duration of the covid-19 pandemic or until otherwise determined by BMJ. You may use, download and print the article for any lawful, non-commercial purpose (including text and data mining) provided that all copyright notices and trade marks are retained.

### REFERENCES

- 1 Caforio A. UpToDate [Internet]. Uptodate.com, 2020. Available: [https://www.uptodate.com/contents/coronavirus-disease-2019-covid-19-myocardial-injury?search=coronavirus&topicRef=4939&source=see\\_link](https://www.uptodate.com/contents/coronavirus-disease-2019-covid-19-myocardial-injury?search=coronavirus&topicRef=4939&source=see_link) [Accessed 24 May 2020].
- 2 Roberts CM, Levi M, McKee M, et al. COVID-19: a complex multisystem disorder. *Br J Anaesth* 2020;125:238–42.
- 3 GOV.UK. Stay at home: guidance for households with possible coronavirus (COVID-19) infection [Internet], 2020. Available: <https://www.gov.uk/government/publications/covid-19-stay-at-home-guidance/stay-at-home-guidance-for-households-with-possible-coronavirus-covid-19-infection> [Accessed 25 May 2020].
- 4 Barohn RJ, Saperstein DS. Guillain-Barré syndrome and chronic inflammatory demyelinating polyneuropathy. *Semin Neurol* 1998;18:49–61.
- 5 Dimachkie MM, Barohn RJ. Guillain-Barré syndrome and variants. *Neurol Clin* 2013;31:491–510.

- 6 Chen S, Andary M, Buschbacher R, *et al.* Electrodiagnostic reference values for upper and lower limb nerve conduction studies in adult populations. *Muscle Nerve* 2016;54:371–7.
- 7 Wang W, Xu Y, Gao R, *et al.* Detection of SARS-CoV-2 in different types of clinical specimens. *JAMA* 2020;323:1843–4.
- 8 Kuwabara S, Ogawara K, Misawa S, *et al.* Does *Campylobacter jejuni* infection elicit "demyelinating" Guillain-Barre syndrome? *Neurology* 2004;63:529–33.
- 9 Stübgen J-P. Lymphoma-associated dysimmune polyneuropathies. *J Neurol Sci* 2015;355:25–36.
- 10 Anderson D, Beecher G, Steve TA, *et al.* Neurological Nuance: Hodgkin lymphoma presenting with Guillain-Barré syndrome. *Muscle Nerve* 2017;55:601–4.
- 11 Recoverytrial.net. Welcome — recovery trial [Internet], 2020. Available: <https://www.recoverytrial.net/> [Accessed 24 May 2020].
- 12 Zhao H, Shen D, Zhou H, *et al.* Guillain-Barré syndrome associated with SARS-CoV-2 infection: causality or coincidence? *Lancet Neurol* 2020;19:383–4.
- 13 Sedaghat Z, Karimi N. Guillain Barre syndrome associated with COVID-19 infection: a case report. *J Clin Neurosci* 2020;76:233–5.
- 14 Toscano G, Palmerini F, Ravaglia S, *et al.* Guillain-Barré syndrome associated with SARS-CoV-2. *N Engl J Med* 2020;382:2574–6.
- 15 Sampathkumar P, Temesgen Z, Smith TF, *et al.* Sars: epidemiology, clinical presentation, management, and infection control measures. *Mayo Clin Proc* 2003;78:882–90.
- 16 McCarthy N, Giesecke J. Incidence of Guillain-Barré syndrome following infection with *Campylobacter jejuni*. *Am J Epidemiol* 2001;153:610–4.
- 17 McGrogan A, Madle GC, Seaman HE, *et al.* The epidemiology of Guillain-Barré syndrome worldwide. *Neuroepidemiology* 2009;32:150–63.

Copyright 2020 BMJ Publishing Group. All rights reserved. For permission to reuse any of this content visit <https://www.bmj.com/company/products-services/rights-and-licensing/permissions/>  
 BMJ Case Report Fellows may re-use this article for personal use and teaching without any further permission.

Become a Fellow of BMJ Case Reports today and you can:

- ▶ Submit as many cases as you like
- ▶ Enjoy fast sympathetic peer review and rapid publication of accepted articles
- ▶ Access all the published articles
- ▶ Re-use any of the published material for personal use and teaching without further permission

#### Customer Service

If you have any further queries about your subscription, please contact our customer services team on +44 (0) 207111 1105 or via email at [support@bmj.com](mailto:support@bmj.com).

Visit [casereports.bmj.com](http://casereports.bmj.com) for more articles like this and to become a Fellow