

# Pediatric Gastrointestinal Basidiobolomycosis: Case Report and Review of Literature

Alaa Al-Juaid, Abdulqader Al-Rezqi, Walaa Almansouri, Hatim Maghrabi<sup>1</sup>, Mohamed Satti<sup>1</sup>

Departments of Pediatrics-Infectious Diseases and <sup>1</sup>Histopathology, King Khalid Medical City, National Guard Hospital, Jeddah, Saudi Arabia

**Correspondence:** Dr. Alaa Al-Juaid, Department of Pediatrics-Infectious Disease, King Khalid Medical City, National Guard Hospital, P.O. Box 9515, Jeddah 21423, Saudi Arabia. E-mail: juaidal@ngha.med.sa

## ABSTRACT

*Basidiobolus ranarum* is an environmental saprophyte found worldwide. It is a member of the order *Entomophthorales* of the class zygomycete. The infection is generally restricted to subcutaneous tissues. However, the disease can involve visceral organs, causing gastrointestinal basidiobolomycosis (GIB). GIB usually has nonspecific clinical manifestations and its diagnosis is challenging. Missed and delayed diagnosis of GIB increases the risk of morbidity and mortality, especially in pediatric patient. Previously, most of the cases in Saudi Arabia have been reported from southern region (Tohama, Aseer Region); the current study reports cases from different regions. We report a case of severe GIB and four other cases of pediatric GIB in western region of Saudi Arabia. The aim of our report is to describe the wide range of clinical presentations, diagnosis, management and outcomes. Our case series includes the youngest case report of GIB, a 16-month-old infant and highlights two important points. First, the need of high index of suspicious for diagnosis of GIB and its inclusion in the differential diagnosis of any abdominal mass, fever and eosinophilia. Second, it gives additional supportive evidence that medical management with voriconazole without surgical intervention (intervention if the condition is diagnosed early) is curative.

**Key words:** Basidiobolomycosis, gastrointestinal, pediatrics

ملخص البحث:

تعتبر *Basidiobolus ranarum* من الرنارومييات البيئية التي توجد في مختلف أنحاء العالم. ويقتصر هذا المرض على الأنسجة تحت الجلدية، ولكنه قد يمتد للأعضاء مما يتسبب في التهابها. لا توجد علامات سريرية محددة لهذا المرض الذي يشكل تشخيصه تحدياً. ويزيد عدم القدرة على تشخيصه من المرض والوفيات خصوصاً لدى الأطفال. كانت أغلب الحالات تأتي من جنوب المملكة العربية السعودية ولكن هناك حالات موثقة الآن من مختلف المناطق. يعرض الباحثون حالة لهذا المرض وأربعة حالات أخرى لدى الأطفال في المنطقة الغربية من المملكة. بهدف عرض هذه الحالات لوصف الأشكال المتعددة للمرض وتشخيصه وعلاجه. تضمنت الحالات التي يعرضها الباحثون حالة لطفل يبلغ من العمر سنة وأربعة أشهر. يشير الباحثون لنقطتين مهمتين: الأولى الحاجة إلى مؤشر مرتفع للاشتباه في التشخيص والأخرى أن هناك أدلة داعمة على أن استخدام عقار فيريكونازول (voriconazole) يغني عن التدخل الجراحي لهذه الحالات.

## INTRODUCTION

*Basidiobolus ranarum* is a fungal infection that causes unusual chronic, skin infections and is increasingly being recognized as a causative agent of gastrointestinal

basidiobolomycosis (GIB), especially in pediatric populations from tropical and subtropical regions. Unlike other fungi, *B. ranarum* can cause significant

This is an open access article distributed under the terms of the Creative Commons Attribution-NonCommercial-ShareAlike 3.0 License, which allows others to remix, tweak, and build upon the work non-commercially, as long as the author is credited and the new creations are licensed under the identical terms.

For reprints contact: reprints@medknow.com

**How to cite this article:** Al-Juaid A, Al-Rezqi A, Almansouri W, Maghrabi H, Satti M. Pediatric gastrointestinal basidiobolomycosis: Case report and review of literature. Saudi J Med Med Sci 2017;5:167-71.

### Access this article online

Quick Response Code:



Website:

www.sjmms.net

DOI:

10.4103/sjmms.sjmms\_138\_15

diseases, especially in immunocompetent hosts.<sup>[1]</sup> Of all the pediatric GIB cases reported, almost 70% are from Saudi Arabia.<sup>[2]</sup> Saudi Arabia also has the second highest overall reported GIB patient pool.<sup>[3]</sup> However, basidiobolomycosis is almost always misdiagnosed as other chronic granulomatous diseases, malignancies or inflammatory bowel diseases.<sup>[4]</sup> Therefore, to better understand pediatric GIB, here, we retrospectively review the medical records of five basidiobolomycosis patients who were diagnosed between January 2012 and March 2014 at the King Khalid National Guard Hospital, Jeddah, Saudi Arabia.

## CASE REPORT

A 5-year-old boy was transferred to King Abdulaziz Medical City, Jeddah, in December 2012, with prolonged fever of 30-day duration, diarrhea, vomiting and weight loss. He originally visited the children hospital on the 10<sup>th</sup> day of his illness because his mother had noticed progressive abdominal distention accompanied by a persistent fever. He had a computed tomography (CT) scan of the abdomen that revealed a large retroperitoneal mass with mesenteric lymph node enlargement, consistent with intestinal lymphoma.

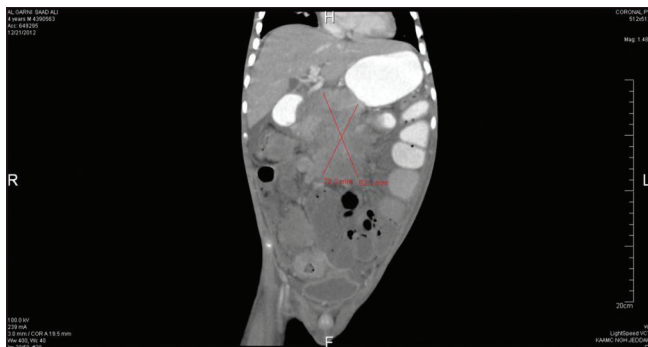
When he was transferred to King Abdulaziz Medical City, the patient had low-grade temperature of 37.5°C, heart rate 110/bpm, respiratory rate 28/min and O<sub>2</sub> saturation 99% at room temperature. The patient was cachectic, pale and his weight was below the fifth percentile. His abdominal examination revealed significant abdominal distention with visible dilated veins and palpable mass in the lower left quadrant. His white blood cell count was 29.9, eosinophils 0.27 (0.08%), neutrophils 22 (84.8%), platelets 1014, hemoglobin 5.6, erythrocyte sedimentation rate > 140 and C-reactive protein 269. The CT scan of his abdomen showed circumferential bowel

wall thickening of the terminal ileum, cecum, ileocecal valve with dilated small bowel loop and collapsed distal colon. A large infiltrative hypodense mass was seen in the upper abdomen (7.9 × 8.2 cm), which had infiltrated the pancreas, with portal vein thrombosis and multiple enlarged retroperitoneal lymph node [Figures 1 and 2]. This radiological finding of the huge bowel mass and mechanical bowel obstruction initially indicated the possibility of intestinal lymphoma versus intestinal tuberculosis.

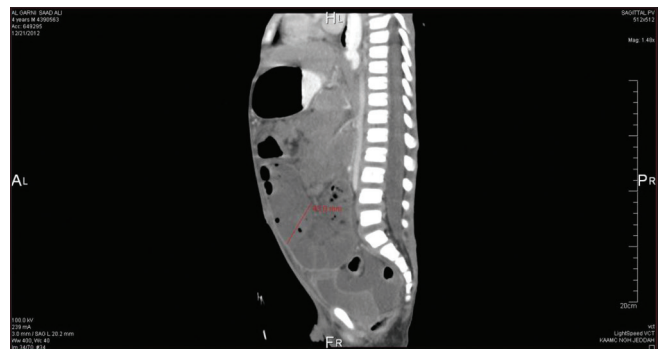
Oncology and pediatric surgery were involved in the care of the patient, and a surgical biopsy was planned to confirm the diagnosis, as well as a bone marrow aspiration and biopsy. Unfortunately, the patient developed hypokalemia and was admitted to the Pediatric Intensive Care Unit (PICU) for potassium chloride infusion. A heparin infusion was started for the portal vein thrombosis. Bone marrow aspiration and biopsy were undertaken the following day, which showed no malignant cells. On the third day in the PICU, the patient's fever spiked and reached 39°C. The patient was prescribed piperacillin/tazobactam with gentamicin intravenous (IV) to control his fever and as he also developed hypertension, he was prescribed lisinopril.

By the eighth day in the PICU, the patient's condition had improved and he underwent exploratory laparotomy for resection of the mass. As the intraoperative findings showed multiple segments of gangrenous bowel, resection and anastomosis were undertaken. A biopsy was taken for the histopathological examination. The surgeon decided that the best course of action was to conduct a repeat laparotomy in the next 24–48 h.

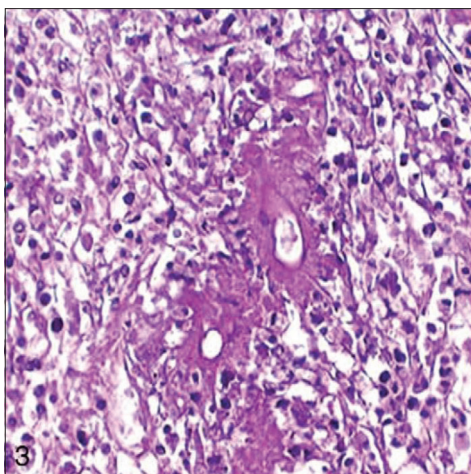
On the 10<sup>th</sup> day in the PICU, the second laparotomy revealed that the small bowel was not viable. Resection from jejunum (40 cm) and part of the duodenum,



**Figure 1:** Computed tomography scan coronal Section shows huge mass 7.2 cm × 8.2 cm. The mass is inseparable and compressing 3 edition part of the duodenum and infiltrating the pancreas



**Figure 2:** Circumferential wall thickening of the terminal ileum, cecum and ileocecal valve with dilated bowel



**Figure 3:** Fungal hyphae with Splendore–Hoeppli phenomenon (necrotizing center containing eosinophils) (H and E stain)

anastomosis and jejunostomy were completed and a colostomy was inserted. Two days later, histopathology findings identified necrotizing granuloma (comprising epithelioid histiocytes and multinucleated giant cells with necrotizing center containing eosinophils “Splendore–Hoeppli phenomenon” surrounded by oval-shaped organisms with septated hyphae, consistent with colonic basidiobolomycosis) [Figure 3 ]. IV voriconazole was started.

The patient remained critically ill in the PICU. His follow-up CT abdomen showed multiple air-fluid levels that are often associated with intestinal obstruction. He had another exploratory laparotomy to release the postsurgical adhesions and washing of the abdomen. His PICU course was complicated by two methicillin-resistant *Staphylococcus aureus* line sepsis, which required removal of the line.

On the 35<sup>th</sup> day in the PICU, the patient’s condition had stabilized and he was transferred to the ward and prescribed total parenteral nutrition (TPN) because of short bowel syndrome (total bowel length 47 cm). The pediatric gastroenterology service felt that this patient would require lifelong TPN because of the short bowel unless he had an intestinal transplant, which is not available in Saudi Arabia. He remained on TPN for 1 year, and overall, he was doing very well and gaining weight. A follow-up CT scan of his abdomen showed regression of the size of the mass. A serial transverse enteroplasty procedure was performed to elongate the bowel, which was successful. The patient started on nasogastric tube (NGT) feeding that was well tolerated with progressive weight gain. After 6 weeks of NGT feeding, PO voriconazole was started.

After 15 months of hospitalization, he was sent home on NGT feeding in addition to PO voriconazole, as the last CT scan of his abdomen showed a persistent mass measuring 2.2 × 1.7 cm. Once discharged, the patient was followed up very closely. However, he did not attend all his appointments, and 3 months after his initial discharge, he was admitted to another hospital with hypernatremia. Few days later, he died because of neurologic sequelae of severe hypernatremia.

## DISCUSSION

*Basidiobolus ranarum* is a fungal infection that has been classified as *Zygomycota* (*Entomophthorales*) and causes unusual chronic skin infections.<sup>[1]</sup> Currently, this fungus is increasingly being recognized as a causative agent of gastrointestinal basidiobolomycosis (GIB), especially in pediatric populations from tropical and subtropical regions. Unlike other fungi, *B. ranarum* can cause significant diseases, primarily in immunocompetent hosts.

To date, there are approximately 28 case reports of pediatric GIB, with the majority being from Saudi Arabia (19 cases). Others have been reported from Iran, Iraq, Brazil, Nigeria and Oman.<sup>[2]</sup> A review by Vikram *et al.* reported that the worldwide occurrence of GIB cases between 1964 and 2010 was 44 cases, with 19 from the USA.<sup>[3]</sup> The other larger patient pool case report from Saudi Arabia had 11 cases.<sup>[3]</sup>

Almost all cases of basidiobolomycosis were misdiagnosed as other chronic granulomatous diseases, malignancies or inflammatory bowel diseases.<sup>[4]</sup> Clinical presentations can vary from abdominal mass and fever with eosinophilia to severe bowel ischemia, necrosis and shock. Severe forms of basidiobolomycosis, as in our patient, are rarely reported. Abdominal examination typically reveals intra-abdominal masses in all cases, which needs to be confirmed by abdominal ultrasonography or CT. Most cases, when first admitted to the hospital, require a workup to rule out lymphoma because of very high inflammatory markers. Subsequent diagnostic procedures to obtain tissue and either histopathology or culture will lead to a correct diagnosis [Table 1]. This is vital as delaying a correct diagnosis could be fatal especially in pediatric patients.<sup>[5,6]</sup> A high index of suspicion is crucial, and diagnosis of basidiobolomycosis should be added to the differential diagnosis of an abdominal mass with eosinophilia. Most of our cases were initially admitted to rule out lymphoma except the last case (Case 5). In

**Table 1: Demographic, clinical, radiological presentations, histopathology, treatment and outcome of all our five cases of gastrointestinal basidiobolomycosis**

	Case 1	Case 2	Case 3	Case 4	Case 5
Age	8 years	4 years	19 months	22 months	16 months
Sex	Male	Male	Male	Male	Male
Year of presentation	2012	2012	2013	2013	2014
Region of residency	History of visiting Southern R	Southern R (Tohama)	Western R	Western R	Southern R
<b>Symptoms</b>					
Abdominal pain	Y	Y	-	-	Y
Abdominal mass	Y	-	Y	Y	Y
Fever	Y	Y	Y	Y	Y
Diarrhea	-	Y	Y	-	-
Vomiting	-	-	-	-	Y
Wight loss	Y	-	-	-	-
<b>Labs</b>					
WBCs	36.6	29.9	38	39.8	26
Eosinophils	26% (10)	0.27	18.7% (20.4)	12% (2.68)	20%
Neutrophils	40% (17)	48% (22)	48.5% (19.5)	28.5% (18.5)	
Platelets	1170	1014	1057	1251	1150
Haemoglobin	7.2	5.6	6.7	7.4	9
ESR/CRP	99/134	>140/269	82/385	51/	137/
<b>Organ involved</b>					
Small intestine	Cecum and	Terminal ileum and	Splenic flexure	Proximal	Terminal ileum
Large intestine	ascending	ileocecal valve	and descending	ascending	and ileocecal
Liver/gallbladder	colon 10 ×	7.9 × 8.2 cm	colon 11 × 7.1	colon and	valve with small
Pancreas	5.4 × 7.6 cm	epigastric region	× 7.2 cm	cecum	bowel obstruction
Stomach			Body and tail of pancreas	6.5 × 4.4 cm	
<b>Initial impression</b>					
Lymphoma	Y	Y	Y	Y	-
TB	-	Y	-	-	-
IBD	-	-	-	-	-
<b>Diagnosis</b>					
Procedure	FNA	Laparotomy	FNA biopsy	FNA biopsy	Laparotomy
Histopathology*	Necrotizing granuloma and fungal hyphae	Granulomatous inflammation consistant with Basidiobolomycosis	Necrotizing granuloma and fungal hyphae	Necrotizing granuloma and fungal hyphae	Necrotizing granuloma and fungal hyphae
<b>Treatment</b>					
Itraconazole	-	-	Y	-	-
Voriconazole	Y	-	-	Y	Y
Voriconazole + Surgical resection of the mass	-	Y	-	-	-
<b>Outcomes</b>					
Survived	Y	-	Y	Y	Y
Died	-	Y	-	-	-
Complication	-	Ischemic bowel Short bowel syndrome + TPN dependent + Hypernatremia	-	-	-
Length of the course	Finished 1 year		Finished 1 Year	Finished 1 Year	Still on medication

Y: Yes, N: No. \*all five cases were diagnosed on the present of characteristic necrotizing granuloma (consist of epithelioid, histiocytes and multinucleated giant cells with necrotizing center containing eosinophils "spendore-Hoepli phenomenon")



this case, basidiobolomycosis was suspected due to the abdominal mass and high eosinophil counts. The patient was started on voriconazole immediately on admission.

The gold standard for the diagnosis is culture, but histopathology is almost equivalent to the culture when the typical features of *B. ranarum* are present, which includes chronic granulomas rich in eosinophils, and the Splendore–Hoeppli phenomenon was the usual diagnostic histological criteria.<sup>[7]</sup> El-Shabrawi *et al.* described a molecular method of DNA sequencing using an 18sRNA for diagnosis of *Basidiobolus*, which can precisely confirm the diagnosis from tissue specimens.<sup>[2]</sup>

Specific therapy is usually started once the diagnosis has been confirmed. Until recently, a trend toward the early surgical resection of fungal mass has been a cornerstone in managing basidiobolomycosis.<sup>[3]</sup> Some centers even adopted a philosophy of the early surgical intervention in patients with GIB who presented with inflammatory masses to minimize morbidity and mortality,<sup>[8]</sup> although many reports show that antifungal therapy alone is sufficient in treating such a cases.<sup>[9]</sup> Combination antifungal therapy has been used with amphotericin-B and itraconazole, although the failure rate with amphotericin-B has been documented in many reports.<sup>[5,10]</sup> Itraconazole has been considered the drug of a choice,<sup>[3]</sup> but some reports from tissue biopsy have demonstrated some resistance to itraconazole and because of its side effects, some interest in using the second-generation azoles (voriconazole) to replace itraconazole in management of GIB has occurred. Many reports showed successful treatment of GIB with voriconazole alone without surgical resection. In our report, our experience with voriconazole has been positive (used in 4/5 cases) and was successful in curing our patients, with no relapses. Posaconazole also has been tried for treatment of GIB with successful results.<sup>[11,12]</sup>

Basidiobolomycosis has a good prognosis based on the available data. Most of the mortalities are attributable to younger age groups, delays in diagnosis and initiation of appropriate antifungal therapy as well as complications of this illness. The only mortality in our cases was secondary to severe hypernatremia and dehydration, along with a delay in diagnosis.

Our case series highlight two important points. First, GIB is an increasingly recognized cause of abdominal mass and eosinophilia that can mimic other diseases. Second, it gives additional clinical experience that voriconazole

without surgical intervention can be curative without relapses, thus avoiding unnecessary major surgeries.

## Acknowledgment

We would like to acknowledge Dr. Sergio Fanella, MD, FRCPC, DTM and H., Assistant Professor and Program Director, Pediatric Infectious Diseases, University of Manitoba, College of Medicine, for reviewing this manuscript and Dr. Abdulrahman Abutaleb, Chairman of Pediatrics Department, King Khalid National Guard Hospital, for his support in conducting this study.

## Financial support and sponsorship

Nil.

## Conflicts of interest

There are no conflicts of interest.

## REFERENCES

- Hibbett DS, Binder M, Bischoff JF, Blackwell M, Cannon PF, Eriksson OE, *et al.* A higher-level phylogenetic classification of the *Fungi*. *Mycol Res* 2007;111:509-47.
- El-Shabrawi MH, Kamal NM, Kaerger K, Voigt K. Diagnosis of gastrointestinal basidiobolomycosis: A mini-review. *Mycoses* 2014;57:138-43.
- Vikram HR, Smilack JD, Leighton JA, Crowell MD, De Petris G. Emergence of gastrointestinal basidiobolomycosis in the United States, with a review of worldwide cases. *Clin Infect Dis* 2012;54:1685-91.
- Khan ZU, Khoursheed M, Makar R, Al-Waheeb S, Al-Bader I, Al-Muzaini A, *et al.* *Basidiobolus ranarum* as an etiologic agent of gastrointestinal zygomycosis. *J Clin Microbiol* 2001;39:2360-3.
- El-Shabrawi MH, Kamal NM. Gastrointestinal basidiobolomycosis in children: An overlooked emerging infection? *J Med Microbiol* 2011;60(Pt 7):871-80.
- van den Berk GE, Noorduyn LA, van Ketel RJ, van Leeuwen J, Bemelman WA, Prins JM. A fatal pseudo-tumour: Disseminated basidiobolomycosis. *BMC Infect Dis* 2006;6:140.
- Ribes JA, Vanover-Sams CL, Baker DJ. Zygomycetes in human disease. *Clin Microbiol Rev* 2000;13:236-301.
- Al-Shanafey S, AlRobean F, Bin Hussain I. Surgical management of gastrointestinal basidiobolomycosis in pediatric patients. *J Pediatr Surg* 2012;47:949-51.
- Albaradi BA, Babiker AM, Al-Qahtani HS. Successful treatment of gastrointestinal basidiobolomycosis with voriconazole without surgical intervention. *J Trop Pediatr* 2014;60:476-9.
- Al Jarie A, Al Azraki T, Al Mohsen I, Al Jumaah S, Almutawa A, Mohd Fahim Y, *et al.* Basidiobolomycosis: Case series. *J Mycol Med* 2010;21:37-45.
- Zabolinejad N, Naseri A, Davoudi Y, Joudi M, Aelami MH. Colonic basidiobolomycosis in a child: Report of a culture-proven case. *Int J Infect Dis* 2014;22:41-5.
- Rose SR, Lindsley MD, Hurst SF, Paddock CD, Damodaran T, Bennett J. Gastrointestinal basidiobolomycosis treated with posaconazole. *Med Mycol Case Rep* 2012;2:11-4.