



Contents lists available at ScienceDirect

## International Journal of Surgery Case Reports

journal homepage: [www.casereports.com](http://www.casereports.com)

# Congenital pseudarthrosis of the forearm treated with induced membrane technique: A case report

Ahmed Amine Mohseni\*, Rim Boussetta, Walid Saied, Mohamed Zairi, Ahmed Msakni, Sami Bouchoucha, Mohamed Nabil Nessib

Children's Hospital Béchir Hamza, Tunis Tunisia Pediatric Orthopedic Surgery Department, Tunisia

## ARTICLE INFO

### Article history:

Received 26 August 2020

Received in revised form 14 October 2020

Accepted 15 October 2020

Available online 4 November 2020

### Keywords:

Pseudarthrosis  
Induced membrane  
Forearm  
Neurofibromatosis  
Pediatric  
Case report

## ABSTRACT

Congenital pseudarthrosis of the forearm (CPF) is an uncommon entity frequently described in association with neurofibromatosis type 1. Surgical treatment is required. This is a challenging pathology in pediatric orthopedic surgery due to the difficulty of achieving a satisfying result in terms of bone defect healing. Many techniques are described such as free vascularized fibula, ilizarov and induced membrane. We describe a first case of the forearm non union associated with neurofibromatosis type 1 successfully treated with 2 steps of induced membrane. Whatever the technique selected it's remain challenging problem in pediatric orthopaedic.

© 2020 Published by Elsevier Ltd on behalf of IJS Publishing Group Ltd. This is an open access article under the CC BY-NC-ND license (<http://creativecommons.org/licenses/by-nc-nd/4.0/>).

## 1. Introduction

Congenital pseudarthrosis of the forearm (CPF) is an uncommon entity oftently described in association with neurofibromatosis type 1 (less than 100 hundred cases described in the literature). This is a challenging pathology in pediatric orthopedic surgery due to the difficulty of achieving a satisfying result in terms of bone defect healing. Many surgical procedures are described in the literature, like the use of vascularized fibular graft, a surgery that requires technical skills especially with young children where microsurgery is performed. Another method that has shown remarkable progress as well as promising results is Masquelet technique (Induced membrane) [1].

We describe a case of congenital pseudarthrosis of the forearm in context of neurofibromatosis (NB) type 1 treated successfully with induced membrane.

### 1.1. Presentation of case

A 10-year-old boy presented with a problem of failure to consolidate his both bone forearm fracture that had been treated with cast

**Table 1**

Diagnostic of Neurofibromatosis Type 1 (NF1)(1).

1. Six or more café au lait macules over 5 mm in greatest diameter in prepubertal individuals and over 15 mm in greatest diameter in postpubertal individuals
2. Two or more neurofibromas of any type or one plexiform neurofibroma
3. Freckling in the axillary or inguinal regions (Crowe's sign)
4. Optic glioma
5. Two or more Lisch nodules (iris harmartomas)
6. A distinctive osseous lesion such as sphenoid dysplasia or thinning of long bone cortex with or without pseudoarthrosis
7. A first-degree relative (parent, sibling, or offspring) with NF1 by the above criteria

immobilization (Fig. 1). No associated deformity of the other limbs was observed. No family history including any relevant genetic information. Clinical examination revealed multiple “café-au-lait” spots and subcutaneous neurofibromatosis. MRI was performed showing pathological tissue in the Radius and the Ulna (Fig. 2). The diagnosis of NF 1 was made according the NIH 1988 Criteria [2] Table 1. After discussion, the medical staff decided to use the induced membrane by experienced operator. The patient agree with this technique. The first stage consists of excision of the pseudarthrosis (Fig. 3) until visualization of normal bleeding bone in both proximal and distal ends of the bone. Intramedullary pinning was then performed bridging the excised atrophic zone. A polymethyl methacrylate cement spacer was placed in the gap to induce the formation of pseudo membrane. Syringes split along

\* Corresponding author.

E-mail addresses: [ahmedaminemohsni@hotmail.com](mailto:ahmedaminemohsni@hotmail.com) (A.A. Mohseni), [boussettarim@hotmail.fr](mailto:boussettarim@hotmail.fr) (R. Boussetta), [drsaiedwalid@gmail.com](mailto:drsaiedwalid@gmail.com) (W. Saied), [mohammed.zairi@hotmail.fr](mailto:mohammed.zairi@hotmail.fr) (M. Zairi), [dr.ahmedmsakni@gmail.com](mailto:dr.ahmedmsakni@gmail.com) (A. Msakni), [bouchoucha.sami@yahoo.fr](mailto:bouchoucha.sami@yahoo.fr) (S. Bouchoucha), [nabil.nessib@rns.tn](mailto:nabil.nessib@rns.tn) (M.N. Nessib).

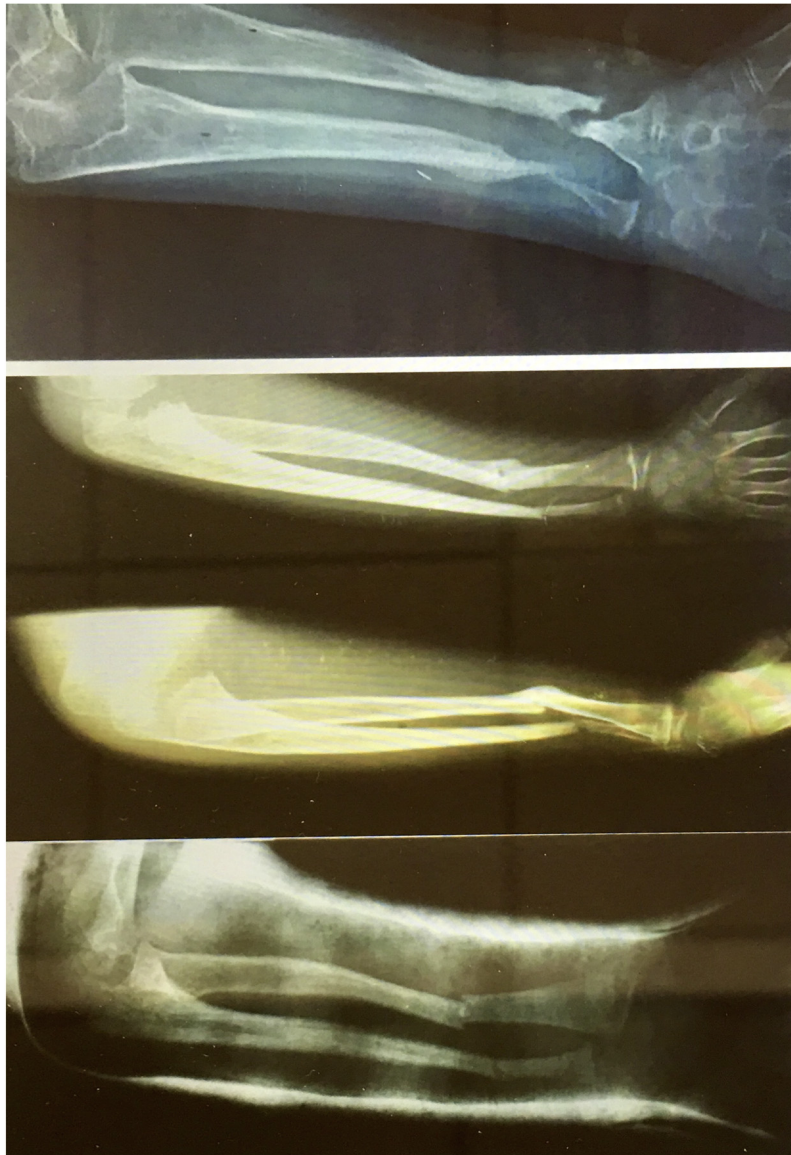
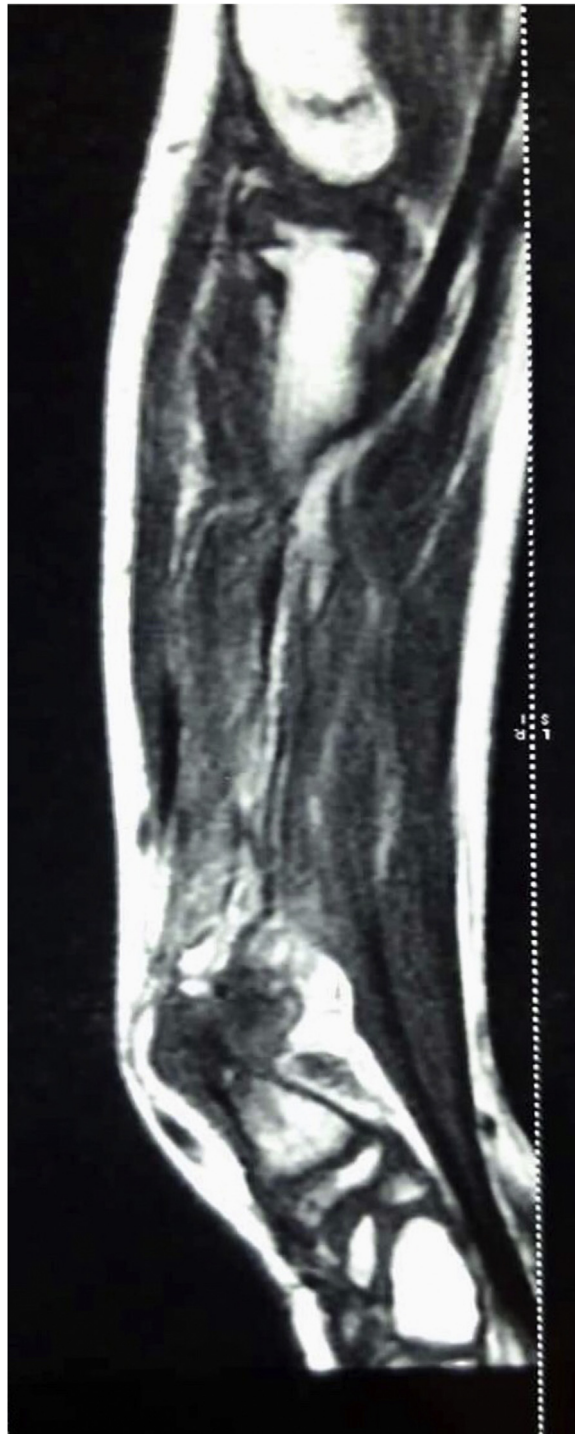

Fig. 1. X-ray showing pseudarthrosis of the ulna and the radius.



**Fig. 2.** MRI of the forearm showing a pathological tissue in the Radius and the Ulna.

their length are placed temporarily to protect the surrounding tissues from the thermal effect of the polymerization. This procedure is performed first in the ulna then in the radius to restore the length of the forearm. The stabilization is done by plate with interlocking screws in the radius and k-wire in the ulna (Fig. 4). Then a cast immobilization is applied. The second stage of induced membrane is planned for two months later.

The first step of the second stage is to harvest the posterior cortico-cancellous crest autograft. After that, in the supine posi-

tion the forearm was approached through the prior incisions and the cement is carefully removed taking precautions to not injure or disturb the induced membrane (Fig. 5). The intramedullary canal is recanalized at each side. The graft is morselized and mixed with blood harvested from iliac crest grafting and interposed in the membrane cavity. An elbow cast was applied for 3 months. Solid union was achieved after 7 months (Fig. 6) and he had a full range of motion of the elbow 0° of extension and 120° of flexion, and a mild limitation in the prono-supination 45°/45° of the forearm.

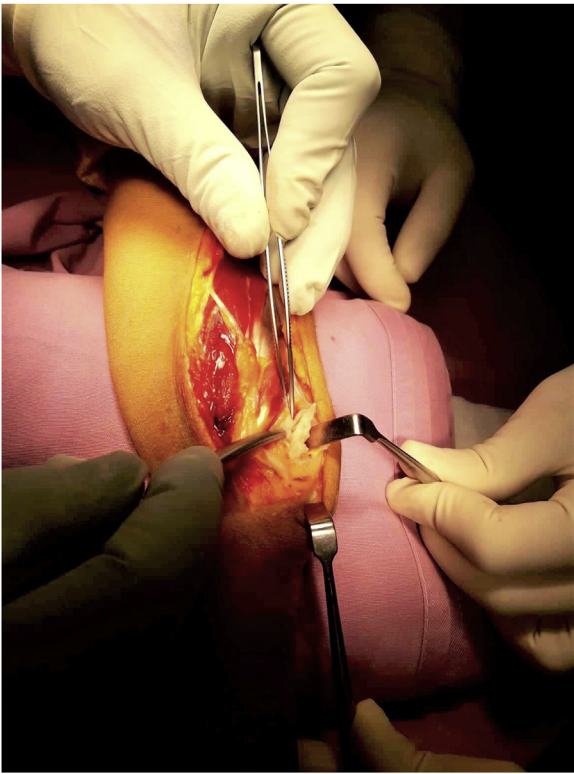


Fig. 3. Resection of pathologic tissue.

The K-Wire and the plate were removed 18 months later (Fig. 7). At final follow-up of 32 months of the second procedure the patient is satisfied with the function of the upper limb.

## 2. Discussion

Congenital pseudarthrosis of the forearm (CPF) is an uncommon pathology less than 65 cases described in the literature [3]. CPF is still challenging condition in pediatric orthopedic surgery. The ulna occur in 44%, the radius in 30%, and both bones are fractured in 26% [4]. The etiology is not completely understood. Bayne [5] suggest that the origin of the pathology occur in the 5th week of gestation with anomalies of the neural crest with faulty development in mesodermal structures [5]. Sequelae of trauma may be the first symptom to present of an underlying problem (Fig. 1). Cast immobilization fail usually to union fracture [4] in CPF associates with NF. Many techniques Illizarov [6] and vascularized fibula grafting [7] are described and have demonstrate good result with union. The superiority of each specific procedure is difficult to determine due to the lower number of cases studied and the variability of the localization of the pseudarthrosis.

Vascularized fibula grafting brings his own vascular supply and can bridge the gap after the large resection of the pseudarthrosis [7]. However, this technique require specialized surgery with the technical difficulties of microsurgery especially in young children. Vascularized fibula graft has the inconvenient of the valgus deformity at the donor site with ankle instability [8], the residual ankle pain and a random of hypertrophy of the fibula [9]. Although the Illizarov technique appears to be safe with a 75% rate of union in the tibia [10], its utility in the forearm is not in commonly performed in young children.

The use of the induced membrane(Masquelet Technique)in children in congenital disease is innovative technique and has demonstrated a high rate of bony union in the management of pseudarthrosis of the leg [11] and clavicle [12] although its has only been

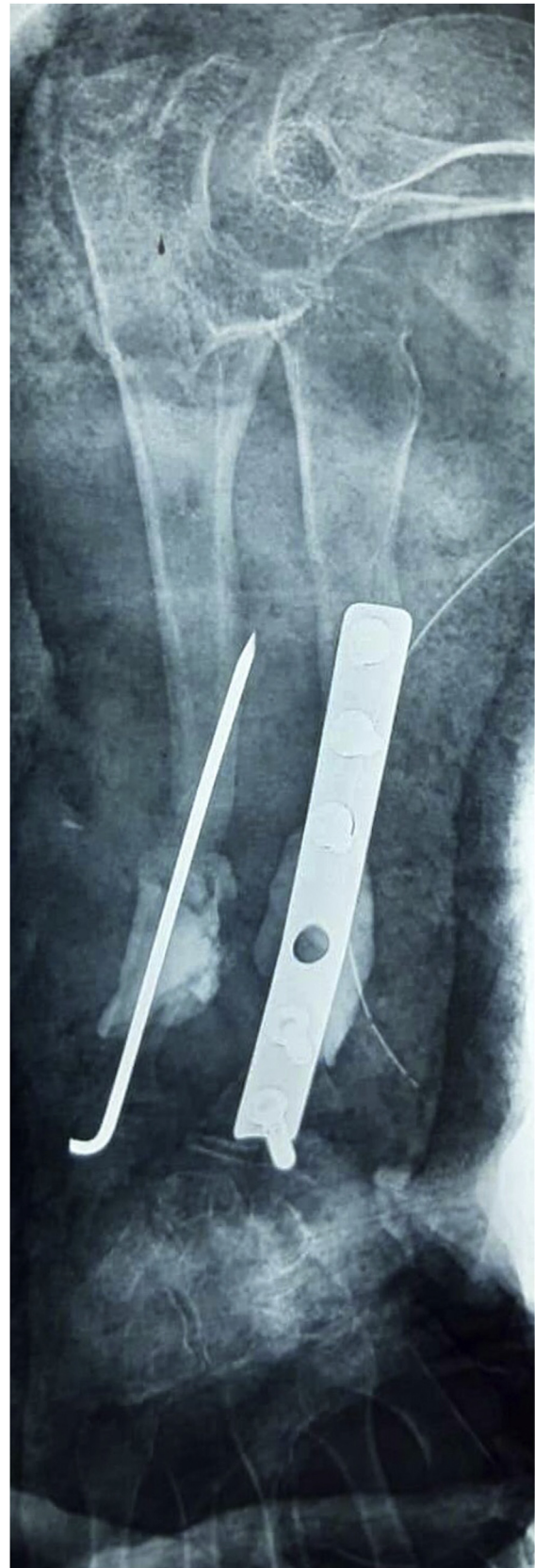
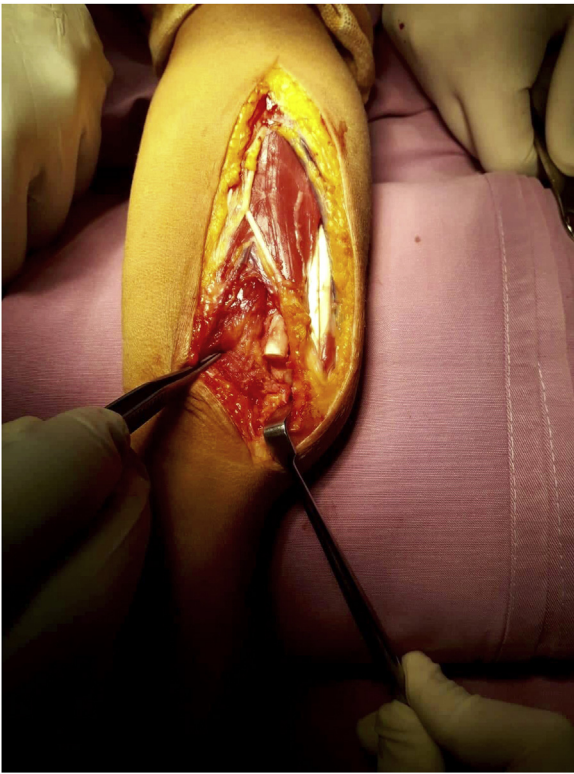


Fig. 4. X-Ray after the first procedure of the Induced membrane.



**Fig. 5.** Exposition of the induced membrane.

reported infrequently in the forearm. This is a two-stage procedure which avoids the complication of the vascular fibular grafting and external fixation.

Based on our experience, we find the induced membrane technique useful for the treatment of pseudarthroses of the forearm in children. Indeed the induced membrane prevents resorption of the bone graft by creating a biological chamber and producing many growth factors that promote vascularity, bone anabolism and consolidation [4].

We believe that mechanical stability is an essential factor for successful reconstruction. The plate stabilization is an interesting way to achieve this condition in most locations.

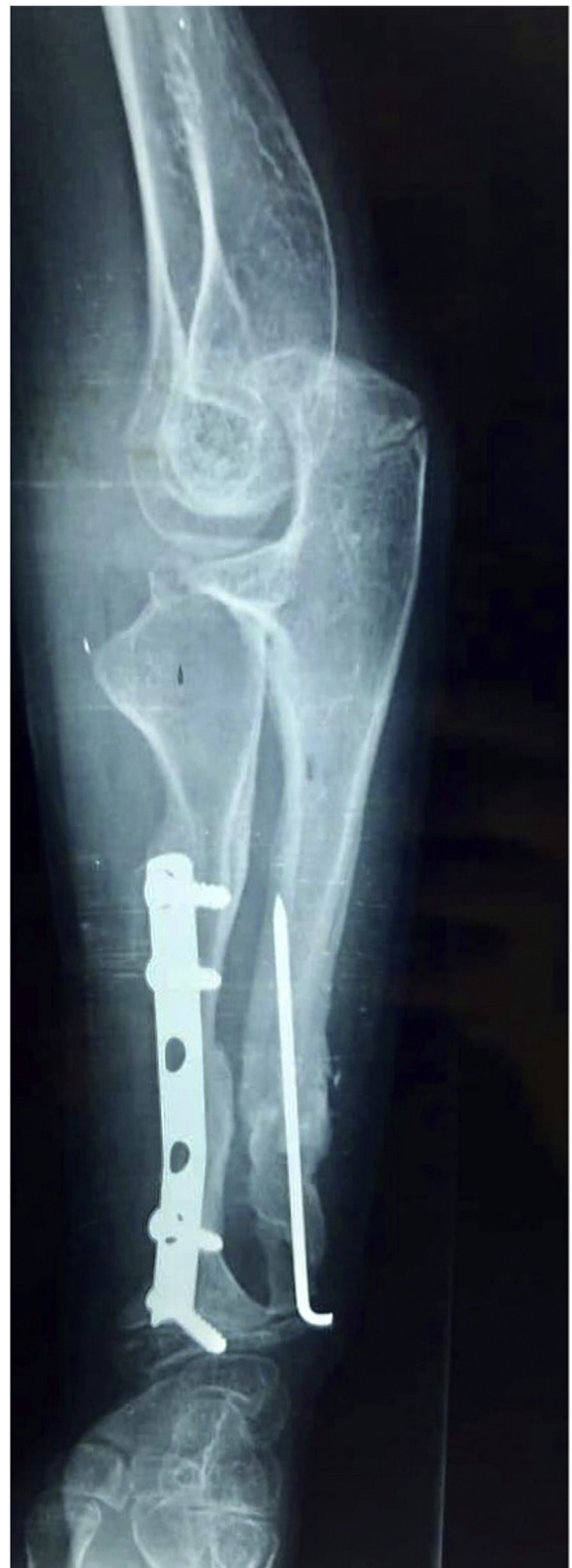The optimal age of indication for surgical treatment of pseudarthrosis of the forearm is still debated. Some authors suggest the treatment should be performed early to avoid progressive deformities of the forearm [7]. On the other hand the society of European Pediatric Orthopedic recommend that surgery should not be performed under the age of three years [10] with high risk of anesthesia.

We join the opinion of Cheng [13] that PCF should be operated before the beginning of the deformity that leads to radial head dislocation and loss function of the elbow.

Our result support that the induced membrane technique ensures satisfactory reconstruction of the congenital pseudarthrosis of the forearm. It should be considered and adds a new seductive and interesting procedure due to its his simplicity and reproductivity.

The limitations of our study are that this is a single case report with short term follow-up and it is early to conclude the real efficiency of this method.

Whatever the technique selected for the management of congenital pseudarthrosis of forearm we believe that it still challenging in orthopedic pediatric surgery. This work has been reported in line with the SCARE criteria [14].



**Fig. 6.** X-Ray after 7 months showing union of the pseudarthrosis.

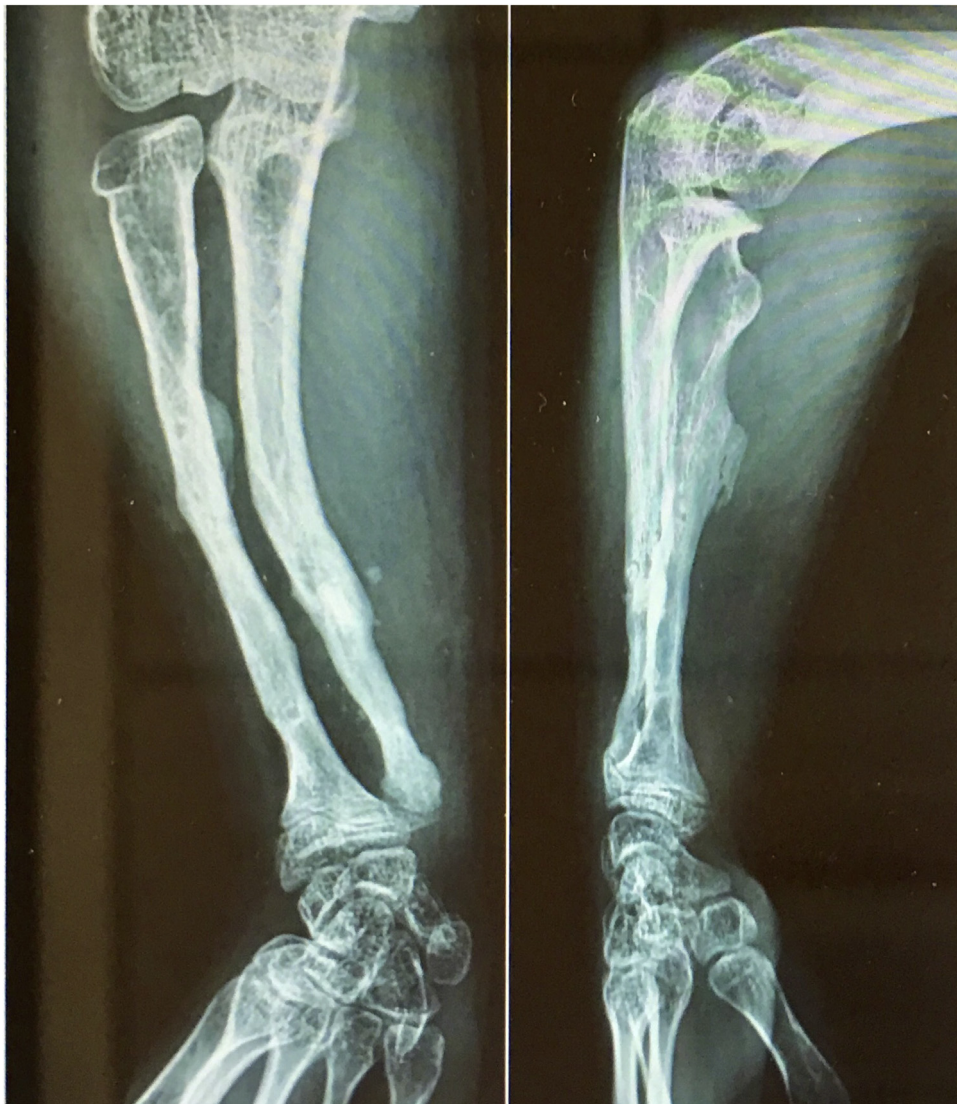

Fig. 7. X-Ray after removing the plate and the plate and the K-wire.

### 3. Conclusion

Surgical treatment is necessary in order to obtain better bone consolidation of congenital pseudarthrosis of the forearm when associated with neurofibromatosis. Masquelet technique is an attractive option for this challenging problem, and has shown promising results.

### Funding

No.

### Ethical approval

Our research study mad with ethical approval.

### Consent

Written informed consent was obtained from the patient for publication of this case report and accompanying images. A copy of the written consent is available for review by the Editor-in-Chief of this journal on request.

### Registration of research studies

N/A.

### Guarantor

Ahmed Amine Mohseni.

### Provenance and peer review

Not commissioned, externally peer-reviewed.

### CRedit authorship contribution statement

**Ahmed Amine Mohseni:** Writing - original draft, Writing - review & editing. **Rim Boussetta:** Supervision. **Walid Saied:** Supervision. **Mohamed Zairi:** Supervision. **Ahmed Msakni:** Supervision. **Sami Bouchoucha:** Supervision. **Mohamed Nabil Nessib:** Supervision.

### Declaration of Competing Interest

The authors report no declarations of interest.

## References

- [1] A.C. Masquelet, Muscle reconstruction in reconstructive surgery: soft tissue repair and long bone reconstruction, *Langenbecks Arch. Surg.* 388 (October (5)) (2003) 344–346.
- [2] National Institutes of Health Consensus Development Conference, Neurofibromatosis conference statement, *J. Natl. Cancer Inst.* 45 (1988) 575–578.
- [3] A.S. Bauer, A.K. Singh, D. Amanatullah, J. Lerman, M.A. James, Free vascularized fibular transfer with langenskiöld procedure for the treatment of congenital pseudarthrosis of the forearm, *Tech. Hand Up. Extrem. Surg.* 17 (2013), nov.
- [4] R. Kohler, F. Solla, S. Pinson, C. Romana, E. Chau, B. Dohin, Pseudarthrose congénitale de l'avant-bras associée à la neurofibromatose, *Rev. Chir. Orthop. Réparatrice Appar. Mot.* 91 (8) (2005) 773–781, déc.
- [5] L. Bayne, Congenital pseudarthrosis of the forearm, *Hand Clin.* 1 (3) (1985) 457–461.
- [6] In Ho Choi, T.-J. Cho, H.J. Moon, Ilizarov treatment of congenital pseudarthrosis of the tibia: a multi-targeted approach using the ilizarov technique, *Clin. Orthop. Surg.* 3 (1) (2011) 1.
- [7] F. Solla, J. Lemoine, C. Musoff, C. Bertocelli, V. Rampal, Surgical treatment of congenital pseudarthrosis of the forearm: review and quantitative analysis of individual patient data, *Hand Surg. Rehabil.* 38 (September (4)) (2019) 233–241.
- [8] M. Ghert, N. Colterjohn, M. Manfrini, The use of free vascularized fibular grafts in skeletal reconstruction for bone tumors in children, *J. Am. Acad. Orthop. Surg.* 15 (October (10)) (2007) 577–587.
- [9] M.C. McCullough, A. Arkader, R. Ariani, N. Lightdale-Miric, V. Tolo, M. Stevanovic, Surgical outcomes, complications, and long-term functionality for free vascularized fibula grafts in the pediatric population: a 17-year experience and systematic review of the literature, *J. Reconstr. Microsurg.* 36 (June (5)) (2020) 386–396.
- [10] F. Grill, G. Bollini, Treatment approaches for congenital pseudarthrosis of tibia: results of the EPOS multicenter study, *J. Pediatr. Orthop.* 9 (2) (2000) 75–89, European Paediatric Orthopaedic Society (EPOS).
- [11] S. Pannier, P. Zagorka, Induced membrane technique for the treatment of congenital pseudarthrosis of the tibia: preliminary results of five case, *J. Child Orthop.* 7 (2013) 477–485.
- [12] B. Haddad, S. Zribi, E. Haraux, F. Deroussen, R. Gouron, C. Klein, Induced membrane technique for clavicle reconstruction in paediatric patients: report of four cases, *Orthop. Traumatol. Surg. Res.* 105 (June (4)) (2019) 733–737.
- [13] J. Cheng, L. Hung, Congenital pseudarthrosis of the ulna, *J. Hand Surg.* (19B) (1994) 238–243.
- [14] R.A. Agha, M.R. Borrelli, R. Farwana, K. Koshy, A. Fowler, D.P. Orgill, For the SCARE Group, The SCARE 2018 statement: updating consensus surgical CAse REport (SCARE) guidelines, *Int. J. Surg.* (60) (2018) 132–136.

## Open Access

This article is published Open Access at [sciencedirect.com](https://www.sciencedirect.com). It is distributed under the [IJSCR Supplemental terms and conditions](#), which permits unrestricted non commercial use, distribution, and reproduction in any medium, provided the original authors and source are credited.