

Prosthetic rehabilitation in patient with achalasia cardia — A rare case report

Sudheer Kondaka, Bathala L. Rao, Juturi R. Reddy, Rajesh Akula

Department of Prosthodontics, Lenora Institute of Dental Sciences, Rajanagaram, Rajahmundry, Andhra Pradesh, India

Corresponding author (email: <dr.sudheer17@gmail.com>)

Dr. Sudheer Kondaka, Department of Prosthodontics, Lenora Institute of Dental Sciences, Rajanagaram, Rajahmundry, Andhra Pradesh, India.

Received: 19-04-16

Accepted: 09-05-16

Published: 25-07-16

Abstract

Achalasia Cardia is an idiopathic esophageal motor disorder distinguished by the loss of esophageal peristalsis and insufficient relaxation of the lower esophageal sphincter. The oral manifestation of the disease is dental erosion caused by the regurgitation of the gastric contents and vomiting. A female patient aged 14 years reported to the Department of Prosthodontics, Lenora Institute of Dental Sciences, with complaints concerning aesthetics and pain in relation to several teeth. Patient gave history of loss of tooth structure over the past few years with associated sensitivity and pain in several teeth. Patient also gave history of inability to consume sufficient amount of food owing to the repeated vomiting. This paper aims to present a rare case report of achalasia cardia by rehabilitating the remaining teeth with overlay denture.

Key words: *Achalasia cardia, dental erosion, gastric regurgitation, overlay denture*

INTRODUCTION

Achalasia is a primary esophageal motility disorder caused by damage to the myenteric plexus, which is denoted by the lack of lower esophageal sphincter (LES) relaxation and esophageal peristalsis.^[1,2] This was first reported by Sir Thomas Williams in 1674. The condition was termed achalasia (Greek for “lack of relaxation”) by Arthur Hurst in 1927.

Achalasia is prevalent in both genders at 0.8% with an incidence of 1 in 1,00,000 population per year at 0.05% with no age barrier, however, incidence peaks in the 3rd and 7th decade of life.^[3,4]

The symptoms include regurgitation of bland undigested food or saliva due to dysphagia to solids

and liquids with occasional weight loss, heart burn, and chest pain.^[5] These are often misdiagnosed as gastroesophageal reflux disease (GERD).^[6,7]

CASE REPORT

A 14-year-old female patient reported to the Department of Prosthodontics with the chief complaint of pain and sensitivity in multiple teeth and aesthetics. Patient also gave a history of repeated vomiting and inability to swallow both solid and liquid foods.

On general examination, there was stunted growth and reduced vertical height of the face; on intraoral examination, multiple erosive lesions and multiple pulpally involved teeth with extensive destruction of enamel and dentin were present.

Access this article online	
Quick Response Code:	Website: www.jispcd.org
	DOI: 10.4103/2231-0762.186793

This is an open access article distributed under the terms of the Creative Commons Attribution-NonCommercial-ShareAlike 3.0 License, which allows others to remix, tweak, and build upon the work non-commercially, as long as the author is credited and the new creations are licensed under the identical terms.

For reprints contact: reprints@medknow.com

How to cite this article: Kondaka S, Rao BL, Reddy JR, Akula R. Prosthetic rehabilitation in patient with achalasia cardia — A rare case report. *J Int Soc Prevent Communit Dent* 2016;6:383-6.

Patient was referred the Department of Gastroenterology, and routine blood investigations were done which were found to be normal. Thyroid profile showed increased T₄ levels. Endoscopy revealed dilated esophagus with no peristalsis. Based on these investigations, a diagnosis of achalasia cardia was made. After balloon dilatation, the patient was relieved of symptoms.

In order to preserve the remaining tooth structure, we planned to go for overdenture. Intraoral periapical radiographs and OPG were taken [Figure 1]. Primary impressions were made with irreversible hydrocolloid material, i.e., Alginate impression material and poured cast with Type III dental stone [Figure 2]. Extraction of 15 14 11 21 24 25 26 36 45 46 was done under antibiotic coverage as the teeth eroded to the level of crest of the ridge and were not suitable for using it as abutments to avoid secondary infections. Root canal treatment was done in relation to 16 13 12 22 23 35 34 33 32 31 41 42 43 44 47 for pulpally involved teeth [Figure 3] and then tooth preparation was done in relation to 13 12 22 23 35 34 33 32 31 41 42 43 44. Final impression was made with polyvinyl siloxane light body consistency [Figure 4]. Then, metal copings were fabricated on working cast by using Co-Cr metal alloy. These copings were permanently cemented with glass ionomer

cement on 13 12 22 23 in the maxillary arch and 35 34 33 32 31 41 42 43 44 in the mandibular arch [Figure 5]. On that conventional overlay denture was fabricated [Figure 6]. Then, the denture was relined at regular intervals with a soft liner [Figure 7].

DISCUSSION

Inhibitory neurons are responsible for the coordination of lower esophageal sphincter relaxation and peristaltic contractions of the esophagus. In achalasia cardia, the inhibitory neurons are affected by the degeneration of the plexus myentericus with unknown origin of genetic, autoimmune, or infectious cause.^[1] In the present case, the symptoms included severe vomiting while consuming food that causes dental erosion, leading to severe sensitivity of many teeth. Various etiological factors of dental erosion in children are caused by consumption of acidic and carbonated beverages, such as citric fruit juices and soft drinks; vomiting and gastroesophageal reflux; and frequent swimming in heavily chlorinated water.^[8,9] Heavy alcohol intake and spicy food consumption are other risk factors in adults.

In this case, the dental erosion was caused by repeated regurgitation of food. We planned for overdenture where we selected 12 13 22 23 31 32 33 34 35 41 42

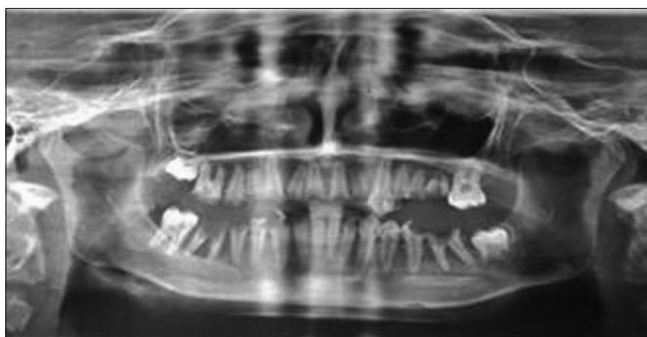

Figure 1: Preoperative orthopantomogram

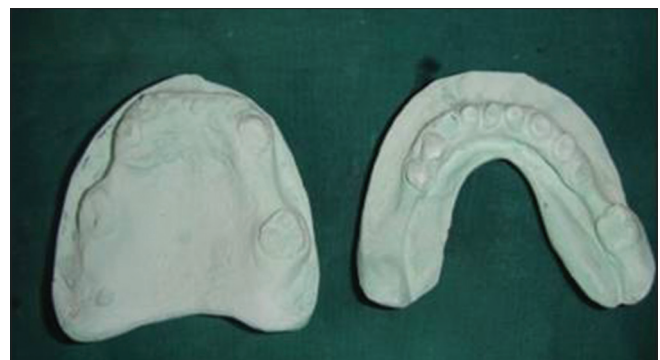

Figure 2: Primary cast

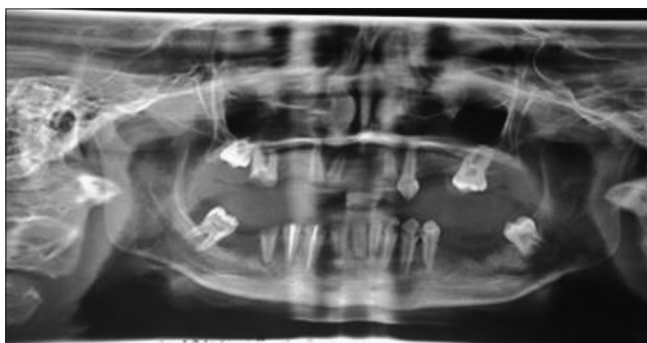

Figure 3: Orthopantomogram: During treatment

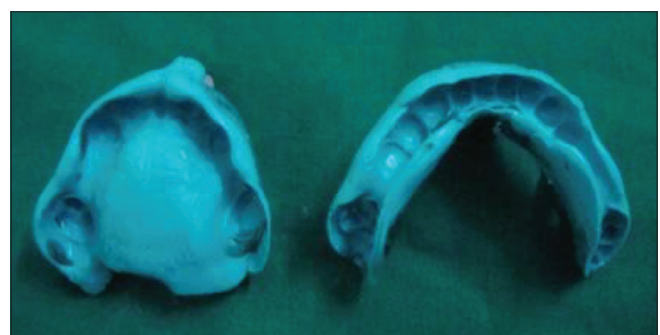


Figure 4: Final Impressions with polyvinyl siloxane (light body)

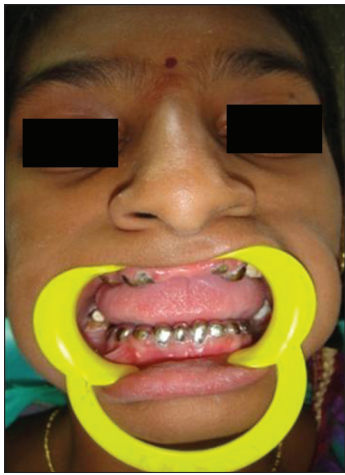


Figure 5: Metal copings cemented with glass ionomer cement: intraoral view

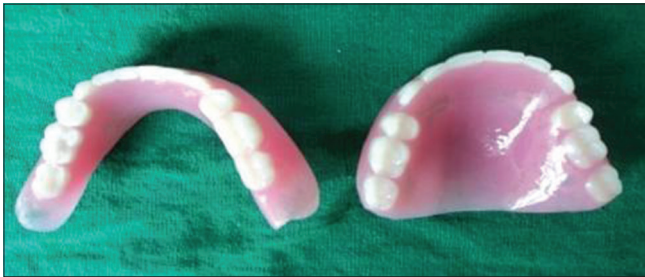

Figure 6: Final finishing of overlay dentures set

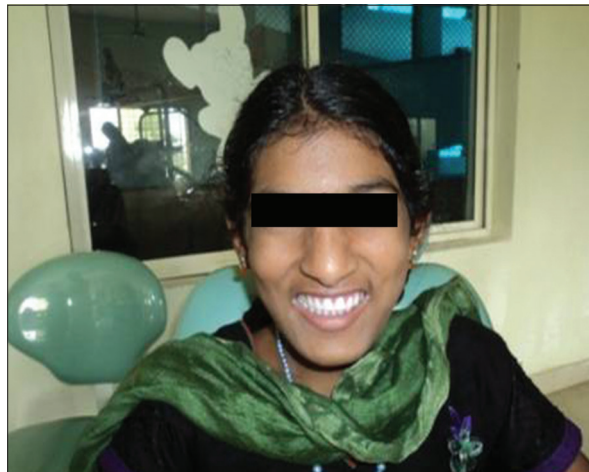

Figure 7: Rehabilitation with overlay dentures: extraoral view

43 44 as abutments because they contain larger roots compared to the posterior teeth. In a 4-year study by Renner *et al.*, it was found that 50% of the roots used as overdenture abutments remained immobile.^[10] A Chamfer finish line was planned for getting metal copings. Metal copings are more protective and retentive than the tooth supported prosthesis. Finally, overdenture was constructed and denture was relined every 6 months during postinsertion check-up.

CONCLUSION

DeVan golden statement of “Perpetual preservation of what remains is more important than the meticulous replacement of what is missing” still rings true. Overdenture is definitely a better option as compared to a conventional removable prosthesis particularly in achalasia cases because we preserve the remaining tooth structures with metal copings and reconstruct the remaining.

However, early diagnosis of achalasia cardia plays a major role in preventing the teeth from erosion. However, it is anytime advisable to use occlusal splints and fluoride application during the treatment phase of achalasia cardia with balloon dilatation. Once the patient is relieved of symptoms, prosthetic rehabilitation can be carried out based upon the severity of erosion.

Declaration of patient consent

The authors certify that they have obtained all appropriate patient consent forms. In the form the patient(s) has/have given his/her/their consent for his/her/their images and other clinical information to be reported in the journal. The patients understand that their names and initials will not be published and due efforts will be made to conceal their identity, but anonymity cannot be guaranteed.

Financial support and sponsorship

Nil.

Conflicts of interest

There are no conflicts of interest.

REFERENCES

1. Pandolfino JE, Gawron AJ. Achalasia: A systematic review JAMA 2015;18:1841-52.
2. Gyawali CP. Achalasia: New perspectives on an old disease. Neurogastroenterol Motil 2016;28:4-11.
3. Mayberry JF. Epidemiology and demographics of achalasia. Gastrointest Endosc Clin N Am 2001;11:235-48.
4. Podas T, Eaden J, Mayberry M, Mayberry J. Achalasia: A critical review of epidemiological studies. Am J Gastroenterol 1998;93:2345-47.
5. Patel DA, Kim HP, Zifodya JS, Vaezi MF. Idiopathic (primary) achalasia: A review. Orphanet J Rare Dis 2015;10:89.
6. Richter JE. The diagnosis and misdiagnosis of Achalasia: It does not have to be so difficult. Clin Gastroenterol Hepatol 2011;9:1010-1.
7. Abdel Jalil AA, Castell DO. Ineffective esophageal motility (IEM): The old-new frontier in esophagology. Curr Gastroenterol Rep 2015;18:1.

8. Moazzez R, Bartlett D, Anggiansah A. Dental erosion, gastro-oesophageal reflux disease and saliva: How are they related?. *J Dent* 2004;32:489-94.
9. Linnett V, Seow WK. Dental erosion in children: A literature review. *Pediatr Dent* 2001;23:37-43.
10. Samra RK, Bhide SV, Goyal C, Kaur T. Tooth supported overdenture: A concept overshadowed but not yet forgotten!. *J Oral Res Rev* 2015;7:16-21.