

Forehead and Hairline Surgery for Gender Affirmation

Kamol Pansritum, MD

Background: With the improvement of the results of surgical treatment for facial transformation globally, many female transgender individuals seek surgical management for their faces, especially the forehead and hairline. These are critical aspects in the surgical management of the frontonasal-orbital area because the anatomy of the frontal sinuses is complicated and shows a high variation.

Methods: The author presents a grid method to measure the boundary of the frontal sinus in the female transgender forehead contouring and reconstruction. The surgical technique of forehead set back and simultaneous hairline advancement is described.

Results: Between January 2015 and December 2017, there were 23 cases of forehead and hairline feminization procedures by the author. Patient age was between 20 and 74 years (mean 32.56). There were 11 Asians and 12 White patients. Eleven patients underwent supraorbital ridge contouring, and 12 underwent forehead reconstruction. Hairline advancement was simultaneously performed in 9 patients, and 3 underwent forehead augmentation at the supraorbital ridge. The postoperative follow-up time ranged from 3 weeks to 18 months.

Conclusions: The key to the success of forehead contouring surgery in female transgender patients is the precise measurement of the boundary of the frontal sinus. This technique offers a practical way to estimate the frontal sinus sizes and shapes to avoid intraoperative complications and reduces the possibility of surface irregularity. (*Plast Reconstr Surg Glob Open* 2021;9:e3486; doi: 10.1097/GOX.0000000000003486; Published online 22 March 2021.)

INTRODUCTION

With an increased social acceptance of transgender people following improved results of surgical treatment of facial transformation globally, many such individuals seek surgical management for their faces. The quality of life following facial surgery has to support the substantial impact of these procedures. These procedures should improve the overall well-being and reduce psychosocial sequelae in these patients.¹ Fundamental differences between male and female facial features referring to bony and soft tissues have been described in the literature.² Basically, testosterone hormone induces male facial features (such as a prominent supraorbital ridge, prominent nasal angle, broad nose, flat cheeks, and squarer chin and jaw) which differs from those in women. The main characteristic facial features are related to the bony structures.^{3,4} In men, one of the most obvious masculine facial features is the forehead

and the hairline. The forehead is flat and steep, with prominent and robust supraorbital ridges, deep-set orbits, and a high frontal and M-shaped hairline (usually baldness).⁵

Typically, the female face is oval or heart-shaped and has smooth lines. The forehead is vertically high and round with a smooth gentle arc and minimal supraorbital ridges. The frontal hairline is round and well proportional to the middle and lower parts of the face.

Surgical treatment to alter facial features is in practice. This surgery was initially termed as facial feminization surgery by Ousterhout, and variant terms of facial surgery for female transgenders were used, including facial feather remodeling surgery^{3,6} and facial gender confirmation surgery.⁷ Most forehead feminization surgeries are performed by well-trained surgeons in the field of craniofacial surgery. The credit goes to Dr. Paul Tessier, a global pioneer of craniofacial surgery.⁸ Several surgeons perform hairline advancement or hair transplantation, combined with forehead feminization surgery.^{9,10}

METHODS

Study Design and Patients

This was a retrospective study involving male-to-female transgender patients who underwent forehead and

Disclosure: The author has no financial interest to declare in relation to the content of this article. No funding was received for this study.

From the Kamol Cosmetic Hospital, Kwaeng Plabpla, Khet Wangthonglang, Bangkok, Thailand.

Received for publication September 9, 2020; accepted January 26, 2021.

Copyright © 2021 The Author. Published by Wolters Kluwer Health, Inc. on behalf of The American Society of Plastic Surgeons. This is an open-access article distributed under the terms of the [Creative Commons Attribution-Non Commercial-No Derivatives License 4.0 \(CCBY-NC-ND\)](https://creativecommons.org/licenses/by-nc-nd/4.0/), where it is permissible to download and share the work provided it is properly cited. The work cannot be changed in any way or used commercially without permission from the journal.

DOI: 10.1097/GOX.0000000000003486

hairline surgeries (the grid method) at Kamol Cosmetic Hospital, by the author between January 2015 and December 2017. Patients with incomplete medical records were excluded.

Preoperative Investigations

Preoperative anteroposterior view (AP) skull x-ray was taken with a metal grid consisting of multiple squares (1 × 1 cm). The lower part of the metal grid was placed on an imaginary horizontal line at the upper part of the orbital rim (Fig. 1). In cephalogram, the preoperative forehead bossing length (FBL) was measured according to the distance between the most projected point of the supra-orbital ridge and the level of nasion by using the SN (midpoint of the sella turcica to the nasion) as the reference. The preoperative FBL minus postoperative FBL was the forehead reduction distance (FRD) (Fig. 2). The frontal sinuses were then divided into 2 groups:

- Group 1: Small size, frontal sinus height of ≤1 cm.
- Group 2: Large size, frontal sinus height of >1 cm.

To manage the frontal bone bossing and the shape of the entire forehead, the author used surgical procedures depending upon the height of the frontal sinuses and the shape and convexity of the areas superior to the supra-orbital ridge according to Ousterhout’s classification, as follows³:

- Type I: Minimal or absent frontal sinuses. Contouring with burring can be achieved.
- Type II: Foreheads have protruding anterior walls of the frontal sinus with normal frontonasal angles. Augmentation of the area superior to the protrusion with a prosthesis is recommended.
- Type III: Foreheads have over-projected anterior walls of the frontal sinus. Anterior wall osteotomy to set back the forehead is necessary.
- Type IV: Foreheads are small with under-projection of the brow. Augmentation procedures are recommended.

If the height of the frontal sinuses in clinical type I and II is <1 cm, supraorbital ridge shaving with or without augmentation at the area above the orbital ridge is used. If the frontal sinuses in clinical type III or even type I and II with the height of the frontal sinus are >1 cm, frontal bone reconstruction is performed.

Surgical Procedure

The incisions were divided into 3 types as follows (Fig. 3):

- I. Standard bi-coronal incision: For forehead reconstruction without hairline advancement.
- II. Extended hairline incision (pretrichial): Supraorbital ridge shaving or forehead reconstruction with hairline advancement.

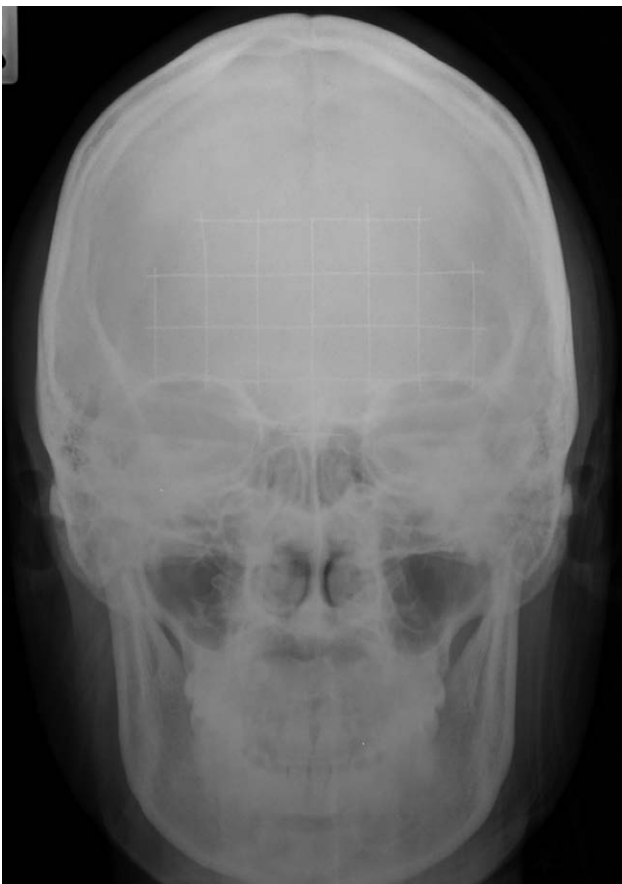

Fig. 1. Grid method: x-ray with a grid.

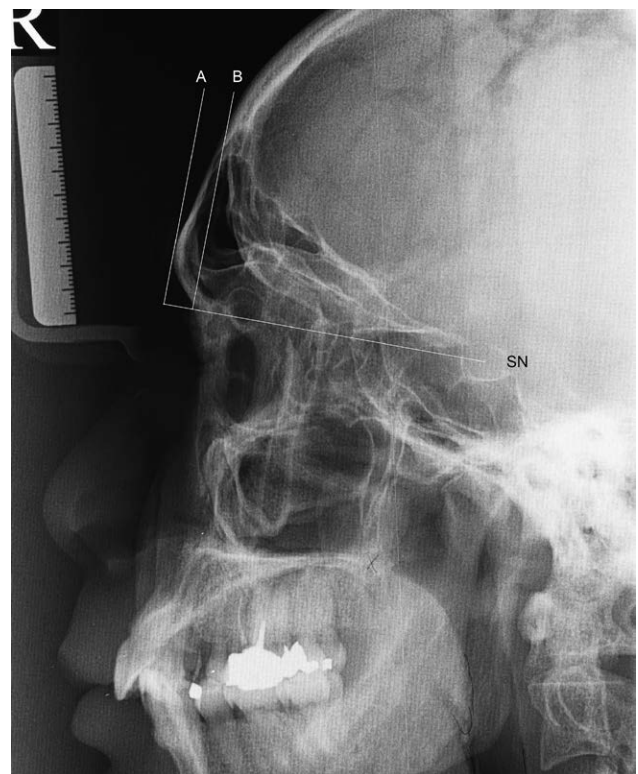


Fig. 2. Measurement of forehead bossing distance on cephalometric x-ray: the midpoint of the sella turcica to the nasion (SN line), the most projected forehead bossing (A), and a perpendicular line of SN (B). The FBL is the distance between lines A and B.

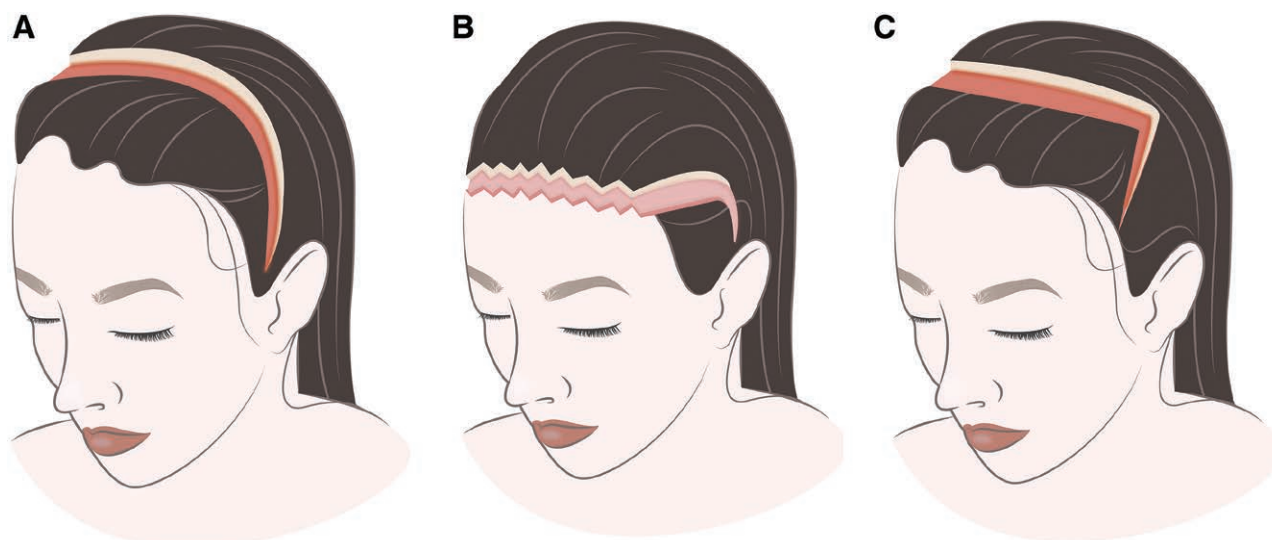


Fig. 3. Incision: standard bi-coronal incision (A), inverted-U trichial incision (B), and extended hairline incision (C).

III. Inverted-U trichial incision: For simple supraorbital ridge shaving with or without augmentation.

The subperiosteal flap was elevated anteriorly at the level of the frontal hairline and then moved inferiorly to 1–2 cm beyond the frontonasal suture. The supraorbital and supratrochlear nerves were protected. Marking of the frontal sinus boundary was made using the grid method. The osteotomy was started at the frontonasal suture, and then directly lateral at the level of the superior orbital rims to the lateral margin of the sinuses with the mini oscillating saw. Then, osteotomy was continued superiorly with the reciprocal saw and then across to connect to the other side. The supraorbital nerves were protected. The sinus septum was carefully divided before the bone segment and then was elevated. The free bone segment and the frontal bone were contoured with gliding tools. The superior orbital rim and the lateral orbital to the sinuses were re-contoured and then reassembled. Permanent sutures were used to fix the bone graft. The closed suction drainage was retained under the frontal skin flap for 24h. In cases where hairline lowering was performed simultaneously, the author used an extended hairline incision with posterior subgaleal dissection and advancement. Then, the posterior scalp flap was anchored to the monocortical bone tunnels. The excess skin was excised approximately by 10–20 mm. In cases of combined hair transplantation, the procedure was delayed to the second stage, under local anesthesia (Figs. 4, 5).

RESULTS

Patients

Between January 2015 and December 2017, there were 23 cases of forehead and hairline feminization procedures performed by the author. The mean age of the patients was 32.56 years (range, 20–74 years). There were 11 Asian patients and 12 White patients. There were 9, 3, and 11 patients with clinical types I, II, and III supraorbital ridges,

respectively. The mean sinus height was 14.3 cm (range, 7–26 mm). Eleven patients underwent supraorbital ridge contouring and 12 underwent forehead reconstruction. Hairline advancement was simultaneously performed in 9 patients. Two patients underwent forehead augmentation at the supraorbital ridge with carved expanded polytetrafluoroethylene, and 1 patient had a customized polymethyl methacrylate prostheses. The postoperative follow-up time ranged from 3 weeks to 18 months. Some overseas patients had follow-ups through video calls. The mean FRD in the bone contouring and forehead reconstruction groups was 2.7 mm (range, 2.3–3.0 mm) and 4.53 mm (range, 3.0–5.7 mm), respectively.

No intraoperative complications were noted. The postoperative complications were reviewed. In 1 case with bi-coronal incision, there was a widened scar (>5 mm) in the middle of the scalp. In 2 cases, there was temporal hair loss of >5 mm at the peri-surgical scar in the mid-scalp area. One patient presented with an irregular surface of the forehead prosthesis warranting minor revisions. No patient had frontal muscle weakness. Hypesthesia of the superior forehead was found in all patients with bi-coronal incision and 2 patients with inverted-U trichial incision; however, it spontaneously recovered in 3–6 months. In 2 patients with bi-coronal and inverted-U trichial scars, a minor degree of hair loss was reported. Infected prosthesis found in 1 case was successfully treated with antibiotics and implant revision. The clinical data and complications are shown in Tables 1 and 2, respectively. The results are shown in Figures 6 and 7.

DISCUSSION

The anatomy of the frontal sinus is the main factor responsible for forehead osteotomy and reconstruction. It is well known that the configuration of the frontal sinus is unique and varies widely among individuals.¹¹ The sinuses stretch like wings transversely over the anterior portion of the orbit. The frontal sinus is always asymmetrical in all

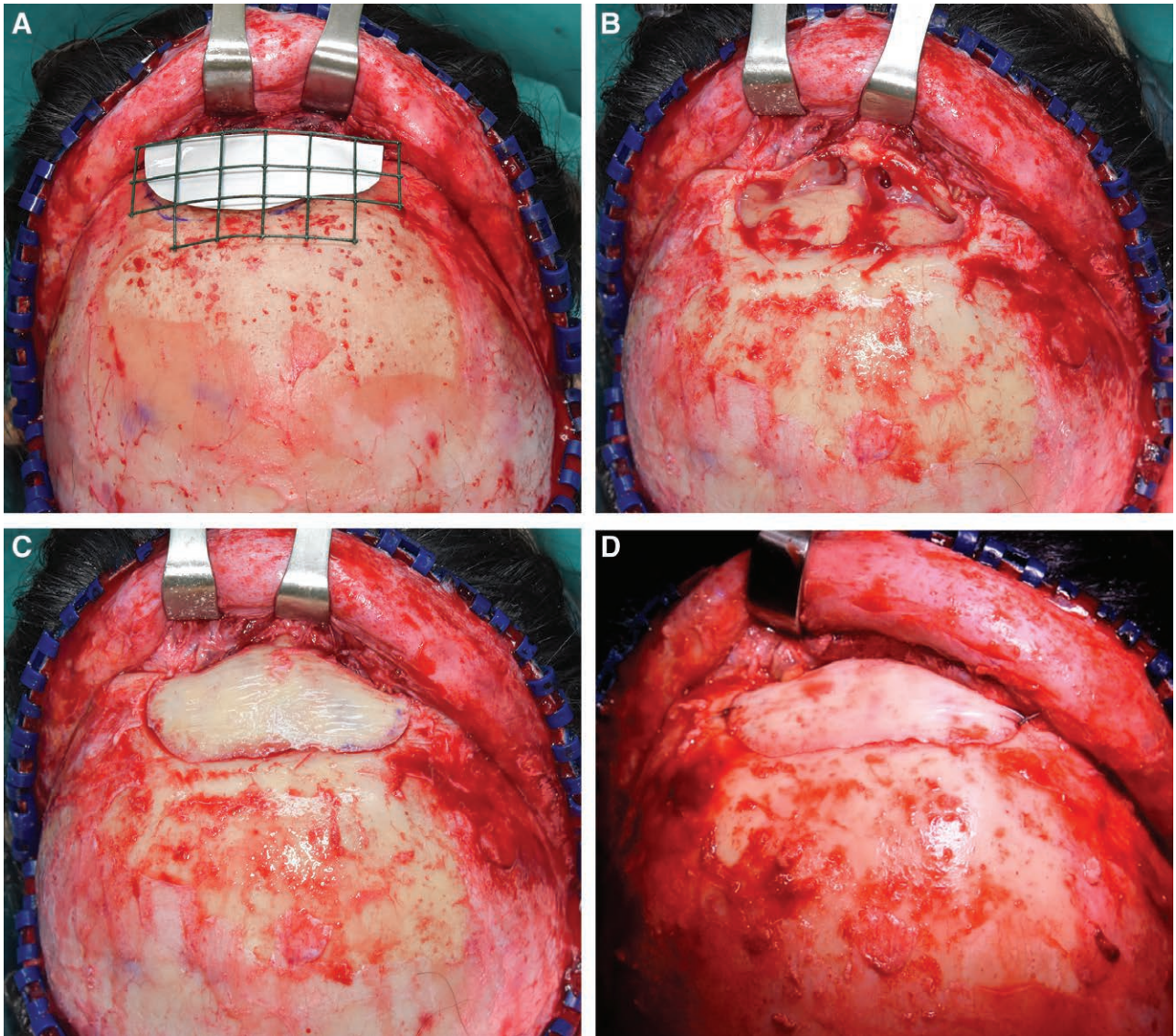


Fig. 4. Intraoperative forehead reconstruction (unrelated example results): marking the line of the boundary of the frontal sinus with a grid (A), frontal sinus after osteotomy (B), reassembled bone flap (C), and bone fixation after gliding (D).

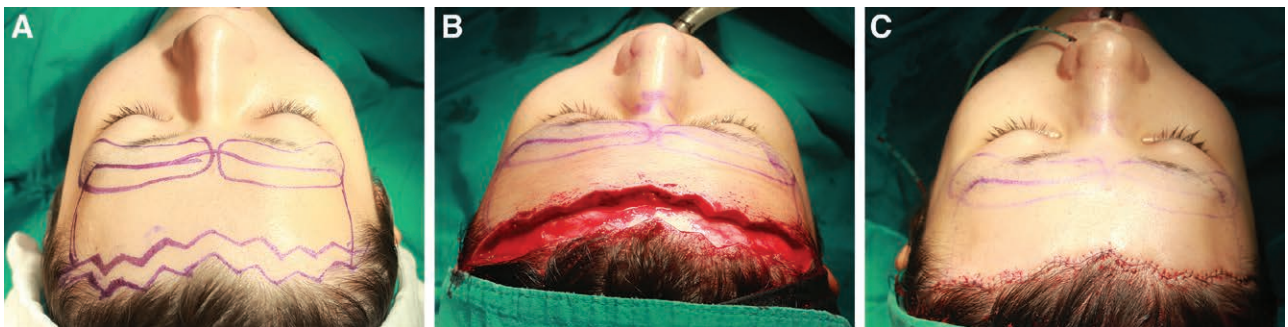

Fig. 5. Hairline lowering procedure (unrelated example results): surgical marking (A), skin excision (B), posterior scalp flap advancement, and wound closure (C).

dimensions. In this study, we found that the limitation of supraorbital ridge contouring is the thickness of the anterior table of the frontal bone.

The height of the frontal sinus should play a major role in creating a plan for osteotomy because the space in the AP dimension is narrow. Further, it is asymmetrical and the

Table 1. Clinical Data

Patient	Age	Race	Classification	Sinus Height (mm)	Procedure	Preoperative/ Postoperative FBL (mm)	FRD (mm)	Follow-up
1	24	White	I	10.0	Supraorbital ridge contouring	5.5/3.0	2.5	4 weeks
2	21	Asian	I	9.0	Supraorbital ridge contouring	6.0/3.2	2.8	12 weeks
3	26	White	I	7.5	Supraorbital ridge contouring	5.5/2.5	3.0	3 weeks
4	20	Asian	I	10	Supraorbital ridge contouring	6.0/3.1	2.9	6 months
5	74	White	I	8	Supraorbital ridge contouring with hairline advancement	6.5/4.0	2.5	4 weeks
6	31	Asian	I	9	Supraorbital ridge contouring with hairline advancement	7.5/5.0	2.5	6 weeks
7	60	Asian	I	10	Supraorbital ridge contouring with hairline advancement	7.4/4.5	2.9	6 months
8	28	White	III	15	Forehead reconstruction	6.6/2.9	3.7	9 months
9	26	White	I	10	Supraorbital ridge contouring with hairline advancement	6.3/3.3	3.0	12 months
10	33	White	III	12	Forehead reconstruction with hairline advancement	6.0/2.9	3.1	18 months
11	25	White	III	20	Forehead reconstruction	7.5/2.3	5.2	8 months
12	50	White	III	15	Forehead reconstruction	5.1/2.1	3.0	12 months
13	20	White	II	8	Supraorbital ridge contouring with augmentation	6.2/3.2	3.0	4 weeks
14	23	Asian	III	22	Forehead reconstruction	8.5/3.4	5.1	12 months
15	24	White	II	12	Forehead reconstruction with hairline advancement	7.7/2.8	4.9	12 weeks
16	37	Asian	III	25	Forehead reconstruction	8.7/3.5	5.2	8 months
17	35	Asian	III	21	Forehead reconstruction	8.6/4.1	4.5	12 months
18	50	White	III	26	Forehead reconstruction	9.4/5.1	4.3	16 months
19	26	Asian	III	23	Forehead reconstruction with hairline advancement	7.4/2.8	4.6	3 months
20	29	White	III	25	Forehead reconstruction	8.8/3.1	5.7	8 months
21	37	Asian	III	24	Forehead reconstruction with hairline advancement	8.1/3.0	5.1	12 months
22	23	Asian	II	9	Supraorbital ridge contouring with augmentation	6.5/4.2	2.3	8 months
23	27	Asian	II	10	Supraorbital ridge contouring with augmentation	7.5/4.8	2.7	18 months

Table 2. Complications

Procedure	Incision	Hypesthesia	Frontalis Muscle Weakness	Widening Scar	Hair Loss	Conjunctivitis	Wound Infection
Forehead reconstruction (N = 12)	Bi-coronal (N = 9)	12	—	1	1	1	—
	Pretrichial (N = 3)	—	—	—	—	1	—
Supraorbital shaving (N = 8)	Inverted-U (N = 2)	2	—	—	—	—	—
	Pretrichial (N = 6)	—	—	—	—	—	—
Supraorbital shaving with augmentation (N = 3)	Trichial-inverted-U (N = 2)	2	—	—	1	—	1
	Pretrichial (N = 1)	—	—	—	—	—	—

posterior surface is irregular. Osteotomy at the superior parts involves more risks of dura mater injury, whereas that at lateral parts has a high chance of maintaining lateral recesses. By computed tomography (CT) scan, Tatlisumak et al determined that the height of right and left frontal sinus ranges from 4.0 to 50.0 mm and from 7.0 to 55 mm, respectively in an adult population. The width of the right and left frontal sinus ranges from 4.0 to 48.0 mm and from 8.0 to 45.0 mm, respectively. The superior limit of the frontal sinuses is crucial because the AP dimension of the upper part of the right frontal sinus can be maximally narrowed (1 mm).¹² The thickness of the anterior table of the frontal bone is the limitation of supraorbital ridge contouring. Lee et al reported that the anterior table thickness ranged from 2.6 to 4.1 mm, and was thinnest at 10 mm left and right of the midline.¹³ Thus, it was necessary to preserve

1–2 mm of the remaining anterior table to maintain bone integrity. In this study, the frontal reduction distance using the burr technique ranged from 2.3 to 3.0 mm.

The limitation of forehead reconstruction is at the level of the frontonasal suture. Therefore, the total distance of the forehead set back is the total of the bony setback and the anterior table shaving. The FRD by this method ranged from 3.0 to 5.7 mm (mean, 4.53 mm). To set back the supraorbital ridge posterior beyond the frontonasal suture, the nasal bone reduction procedure is required simultaneously, as described by Marcelo.⁶ By personal observation, the author has noted that the width of the frontal sinuses is usually related to the height of the sinuses; therefore, using the height as one parameter is simpler and more practical.

Ousterhout's classification has taken into consideration the shape of the forehead and the supraorbital

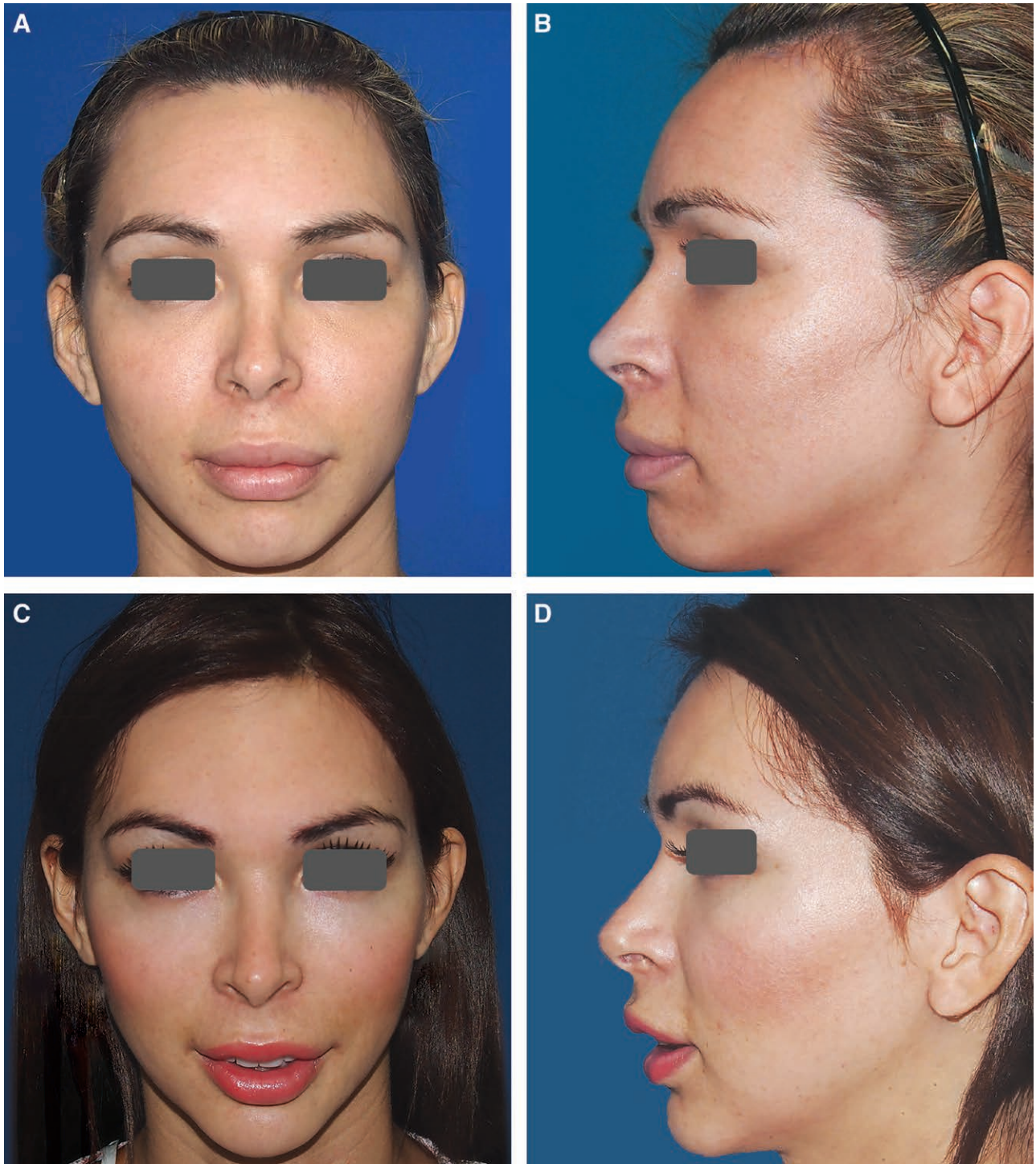

Fig. 6. Results of supraorbital ridge shaving with hair transplantation: preoperative front and side views (A, B), and postoperative (18 months) front and side views (C, D).

ridge, as determined by clinical examination without measuring the bone thickness. According to personal observation, when the height of the frontal sinus is <1 cm, the supraorbital ridge correction tends to benefit from the bone shaving method (Ousterhout's types I and II). When the height of the frontal sinus is ≥ 1 cm and the forehead appearance tends to be marked projected (Ousterhout's

type III), anterior frontal osteotomy and reconstruction can achieve good results. The author believes that a grid method combined with clinical classification successfully achieves the overall forehead feminization. In this study, Ousterhout's classification was used to make a plan for surgery in the majority of patients. Nevertheless, some patients with type II might have high and large frontal

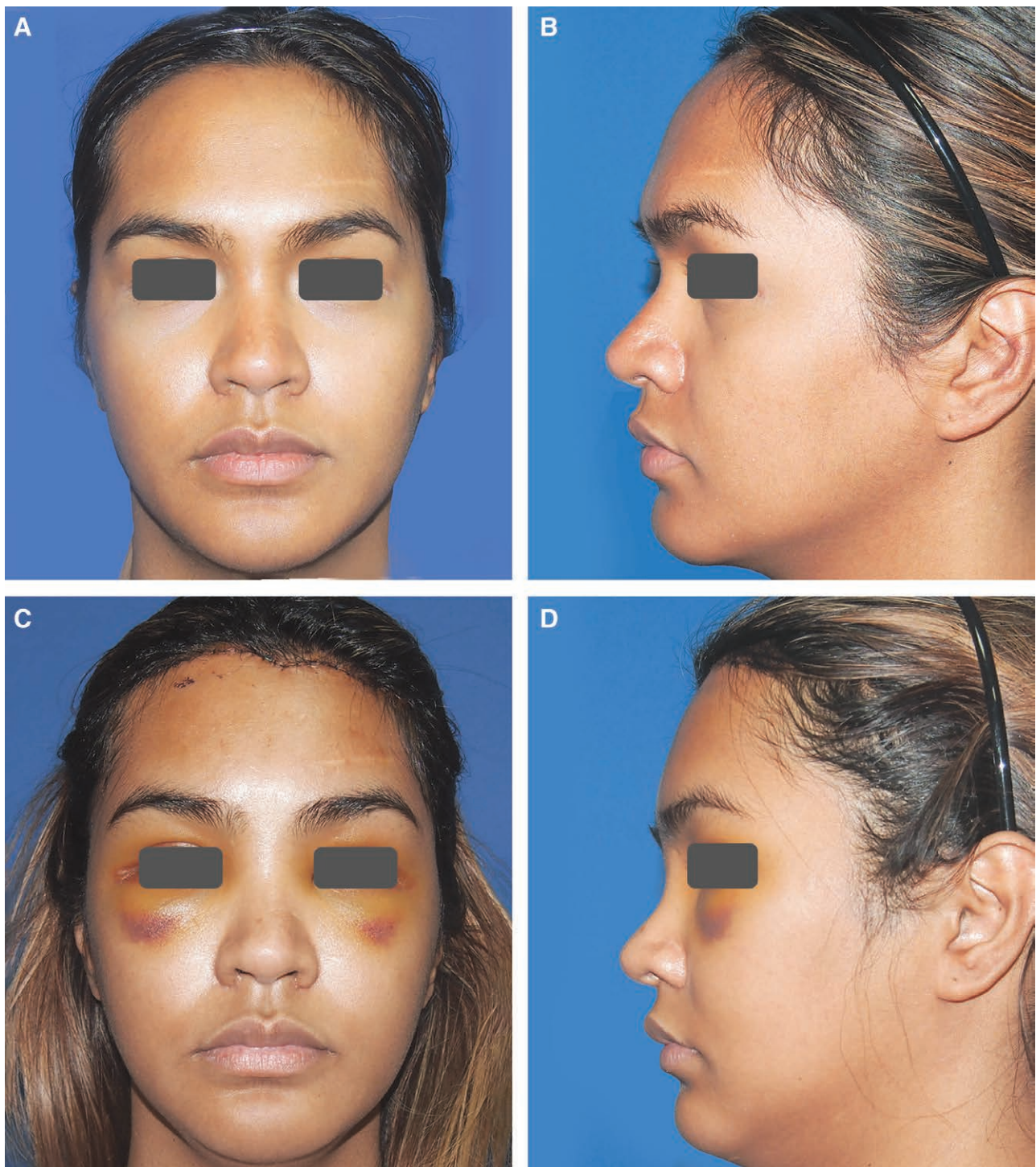

Fig. 7. Results of forehead reconstruction with hairline advancement: preoperative front and side views (A, B) and postoperative (3 weeks) front and side views (C, D).

sinuses (as in patient no. 15), and forehead reconstruction is advantageous.

Frontal osteotomy at the superior parts has a greater risk of intracranial injury due to the narrow space and irregular surface of the posterior wall of the sinuses. Inferior osteotomy tends to have an incomplete cut due to the wide base and asymmetry of the sinuses and tends

to bring unfavorable results due to the bony irregularity from the multi-segment osteotomy. Several methods have described the preoperative and intraoperative techniques for assisted osteotomy. Gilde et al¹⁴ and Mirco et al¹⁵ presented the intraoperative frontal sinus illumination to estimate the extension of the frontal sinus and as a supervision guide. Although useful, it has some limitations; it

is more complicated to apply instruments via frontonasal ducts.

The application cutting guide created from 3-dimensional printing presented by Mandelbaum et al is useful but requires a CT scan and is expensive.¹⁶ The grid method is a better alternative and it helps determine the size and dimension of the frontal sinus preoperatively and intraoperatively. This technique is simple and does not increase the risk to the patients. This technique is adapted from the principle of the grid drawing method that allows surgeons to improve the accuracy of the outline of the frontal sinus. The grid provides common reference points between the reference x-ray and the frontal bone intraoperatively. Thus, grid drawing on the frontal bone can meticulously copy the reference sinus shape and size segment-by-segment. This technique allows surgeons to perform a 1-piece osteotomy of the frontal bone to stabilize the bone flap. It reduces the chance of surface irregularity and also the incidence of dura mater injury. Furthermore, a simple cutting guide can be created using a grid method, preoperatively. The limitation of this technique is the possibility of inaccuracy due to human error by x-ray technicians and the operator. The preoperative and intraoperative teams should be familiar with it. Preoperative CT scans or 3-dimensional CT scans are still necessary and important for complicated or revision surgeries. Regarding fronto-orbital bar reassembly and fixation, most operators use titanium plates or mesh with bone powder to fill the areas of bony gaps and irregular bony surfaces.¹⁷ At this point, the author stresses the primary bone contact and recommends maintaining a reduced bone gap as much as possible. For this reason, bone powder was rarely used, and sutures or small wires were used instead of fixation with plates and screws.

In this study, the bi-coronal approach showed more postoperative complications (including hypesthesia, widening scar, and hair loss) than did the pretrichial (anterior hairline) approach. There was a patient with a previous history of filler injection in the areas superior to the supraorbital ridge (classification II) who had a wound infection (patient no. 23). The infection was successfully treated conservatively with surgical drainage and partial removal of the expanded polyethyl fluoroethylene implant. Pretrichial incision also offers more benefits for simultaneous hairline advancement and brow lift in 1-stage operation. Nevertheless, hair transplantation is usually performed in another stage under local anesthesia to reduce the risks of long operation time. Hairline advancement with secondary hair transplantation usually requires less hair follicles than in a single procedure. Because this study focused on forehead and hairline feminization surgery, some patients in this study who had forehead surgery still showed masculinity in other body parts.

CONCLUSIONS

The key to the success of forehead contouring surgery is the precise measurement of the boundary of the frontal sinus. This technique provides a practical way to estimate the frontal sinus sizes and shapes in the female transgender forehead to avoid intraoperative complications and

reduces the possibility of the multi-segment osteotomy. More studies are required to evaluate the relationship between the frontal sinus and the degree of protrusion of the supraorbital ridge. The esthetic concerns still vary depending on race, culture, and social acceptance in each global area.

Kamol Pansritum, MD

1223 Ladpraow 94, Intraporn Road
Kwaeng Plabpla, Khet Wangthonglang
Bangkok 10310
Thailand

E-mail: kamol.p@mtfsurgery.com

PATIENT CONSENT

The patients provided written consent for the use of their images.

REFERENCES

- Berli JU, Capitán L, Simon D, et al. Facial gender confirmation surgery—review of the literature and recommendations for version 8 of the WPATH Standard of Care. *Int J Transgender.* 2017;18:264–270.
- Ousterhout DK. Dr. Paul Tessier and facial skeletal masculinization. *Ann Plast Surg.* 2011;67:S10–S15.
- Ousterhout DK. Feminization of the forehead: contour changing to improve female aesthetics. *Plast Reconstr Surg.* 1987;79:701–713.
- Hage JJ, Becking AG, de Graaf FH, et al. Gender-confirming facial surgery: consideration on the masculinity and femininity of faces. *Plast Reconstr Surg.* 1997;99:1799–1807.
- Spiegel JH. Facial determinants of female gender and feminizing forehead cranioplasty. *Laryngoscope.* 2011;121:250–261.
- Di Maggio M. Forehead and orbital rim remodeling. *Facial Plast Surg Clin North Am.* 2019;27:207–220.
- Capitán L, Simon D, Berli JU, et al. Facial gender confirmation surgery: a new nomenclature. *Plast Reconstr Surg.* 2017;140:766e–767e.
- Deschamps-Braly JC. Facial gender confirmation surgery: facial feminization surgery and facial masculinization surgery. *Clin Plast Surg.* 2018;45:323–331.
- Cho SW, Jin HR. Feminization of the forehead in a transgender: frontal sinus reshaping combined with brow lift and hairline lowering. *Aesthetic Plast Surg.* 2012;36:1207–1210.
- Altman K. Facial feminization surgery: current state of the art. *Int J Oral Maxillofac Surg.* 2012;41:885–894.
- Tunis JP. Some variations in the anatomy of the frontal sinus. *Laryngoscope.* 1908;18:883–890.
- Tatlisumak E, Ovali GY, Asirdizer M, et al. CT study on morphometry of frontal sinus. *Clin Anat.* 2008;21:287–293.
- Lee MK, Sakai O, Spiegel JH. CT measurement of the frontal sinus – gender differences and implications for frontal cranioplasty. *J Craniomaxillofac Surg.* 2010;38:494–500.
- Gilde JE, Shih CW, Kleinberger AJ. Frontal sinus transillumination in cranioplasty for facial feminization surgery. *JAMA Facial Plast Surg.* 2019;21:566–567.
- Raffaini M, Perello R, Tremolada C, et al. Evolution of full facial feminization surgery: creating the gendered face with an all-in-one procedure. *J Craniofac Surg.* 2019;30:1419–1424.
- Mandelbaum M, Lakhiani C, Chao JW. A novel application of virtual surgical planning to facial feminization surgery. *J Craniofac Surg.* 2019;30:1347–1348.
- Villepelet A, Jafari A, Baujat B. Fronto-orbital feminization technique. A surgical strategy using fronto-orbital burring with or without eggshell technique to optimize the risk/benefit ratio. *Eur Ann Otorhinolaryngol Head Neck Dis.* 2018;135:353–356.