



Contents lists available at ScienceDirect

## International Journal of Surgery Case Reports

journal homepage: [www.casereports.com](http://www.casereports.com)

# Successful treatment of recurrent stoma prolapse after Hartmann's procedure through ileorectal anastomosis: A case report

Noriya Takayama, Shingo Tsujinaka\*, Nao Kakizawa, Soutoku Someya, Jun Takahashi, Fumi Hasegawa, Rina Kikugawa, Yasuyuki Miyakura, Toshiki Rikiyama

Department of Surgery, Saitama Medical Center, Jichi Medical University, Japan

## ARTICLE INFO

## Article history:

Received 17 November 2017

Accepted 20 November 2017

Available online 24 November 2017

## Keywords:

Stoma prolapse  
Parkinson's disease  
Constipation  
Hartmann's procedure  
Ileorectal anastomosis  
Case report

## ABSTRACT

**INTRODUCTION:** Treatment strategy for recurrent stoma prolapse has not been well-established because of the rarity and complexity of the condition. We report a case of recurrent stoma prolapse that was successfully managed using unique surgical treatments.

**PRESENTATION OF CASE:** A 72-year-old man with a history of Parkinson's disease presented with transverse (T3N0M0) and sigmoid (T3N0M0) colon cancer. Considering the status of large bowel obstruction, Hartmann's procedure was indicated. Four months after surgery, stoma prolapse occurred, which became irreducible. Six months after surgery, local resection of the prolapsed bowel was performed. The patient continued to receive laxatives for bowel movement control and his abdomen remained distended. Ten months later, stoma prolapse recurred with evident bowel dilatation. Initially, we planned Hartmann's reversal. However, as the patient had intractable constipation secondary to Parkinson's disease, resection of the proximal colon and ileorectal anastomosis were considered as the treatment choices. Therefore, we performed right colectomy with ileorectal anastomosis. At 1.5 years after the last surgery, complications such as small bowel obstruction, difficulty in defecation, or fecal incontinence were not detected.

**DISCUSSION:** The cause of stoma prolapse is generally ascribed to various anatomical factors such as redundant intestine, high intra-abdominal pressure, and intraperitoneal route. Stoma prolapse is also influenced by other factors, including old age, obesity, and the severity of illness that necessitated stoma creation. In this case, the decision regarding surgical management was complicated by colonic motility disorder with concomitant Parkinson's disease.

**CONCLUSION:** We suggest that ileorectal anastomosis may be an optimal surgical treatment for patients with recurrent stoma prolapse and concomitant colonic motility disorder who have undergone Hartmann's procedure.

© 2017 The Authors. Published by Elsevier Ltd on behalf of IJS Publishing Group Ltd. This is an open access article under the CC BY-NC-ND license (<http://creativecommons.org/licenses/by-nc-nd/4.0/>).

## 1. Introduction

Stoma prolapse is one of the most common late complications after stoma construction [1] and occurs in 2% of colostomies [2]. When stoma prolapse occurs repeatedly despite manual reduction, surgical treatment is needed to fit the stoma pouch appliance and avoid bowel incarceration and strangulation. Surgical treatment options for stoma prolapse include stoma reversal, local resection, or relocation [3]. Stoma prolapse can be treated with local surgical procedures in most cases.

However, treatment strategy for recurrent stoma prolapse with colonic motility disorder has not been well-established because of the rarity and complexity of this condition. We report a case of

recurrent stoma prolapse with colonic motility disorder that was successfully managed using unique surgical treatments in line with the SCARE criteria [4].

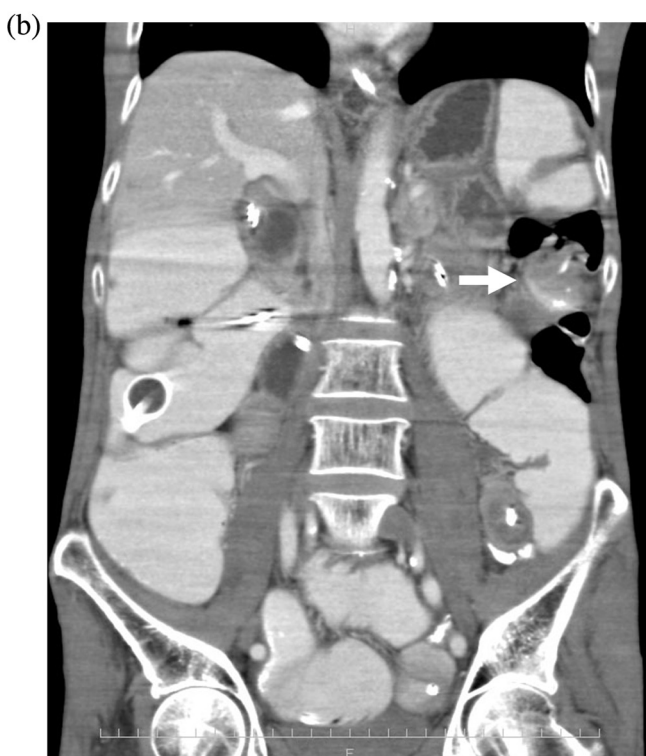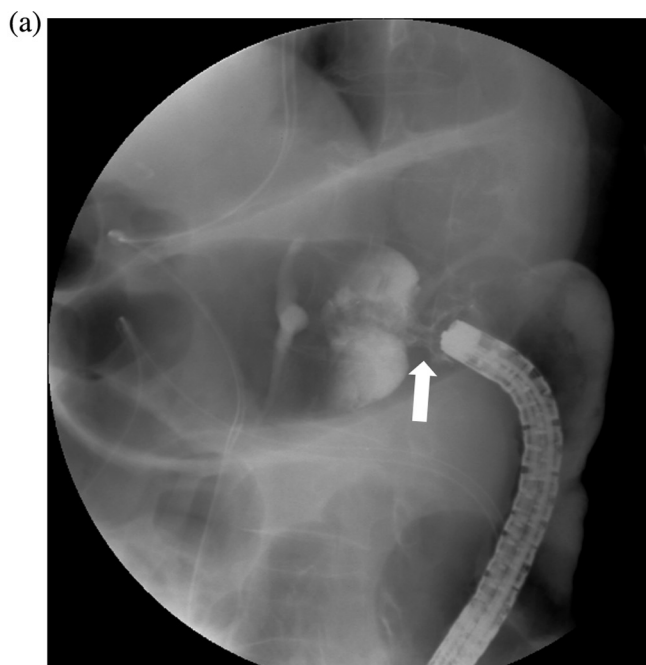
## 2. Presentation of case

We present the case of a 72-year-old man who was diagnosed with Parkinson's disease at the age of 70 years and treated with medications, including levodopa/carbidopa, amantadine, and dopamine agonist. He had intractable constipation secondary to Parkinson's disease, and several laxatives had been prescribed. He also had a significant history of hypertension that was controlled with angiotensin II receptor blockers and calcium channel blockers.

He visited a local hospital for abdominal distension. He was initially treated with medications; however, the symptoms did not improve, and he started to vomit after 10 days. He was diagnosed with bowel obstruction and was admitted to the local hospital. A nasointestinal tube was inserted for decompression. The patient

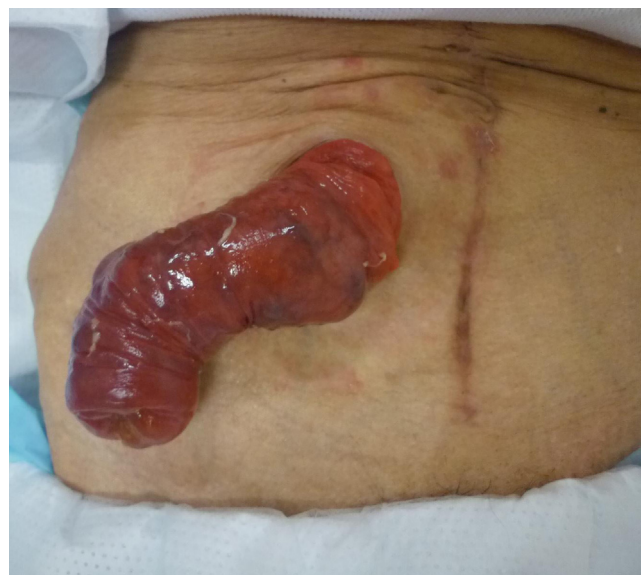\* Correspondence to: Shingo Tsujinaka, 1-847, Amanumacho, Omiya, Saitama-shi, Saitama 330-8503, Japan.

E-mail address: [tsujinakas@omiya.jichi.ac.jp](mailto:tsujinakas@omiya.jichi.ac.jp) (S. Tsujinaka).



**Fig. 1.** A contrast enema study revealed an apple core sign (arrow) at the splenic flexure of the colon (a) and CT revealed a thickened wall (arrow) at the splenic flexure of the transverse colon and dilatation of the proximal colon (b).

was transferred to our hospital for surgical treatment. A contrast enema study revealed an apple core sign at the splenic flexure of the colon, and computed tomography (CT) revealed a thickened wall at the splenic flexure of the transverse colon and dilatation of the proximal colon (Fig. 1). We concluded that the nasointestinal tube was insufficient for effective decompression, and a colonic stent was placed endoscopically. Colonoscopy showed advanced tumors in the transverse (T3N0M0) and sigmoid (T3N0M0) colon. Therefore, the patient was diagnosed with synchronous colon cancer, and



**Fig. 2.** Stoma prolapse occurred with congestion of its wall.

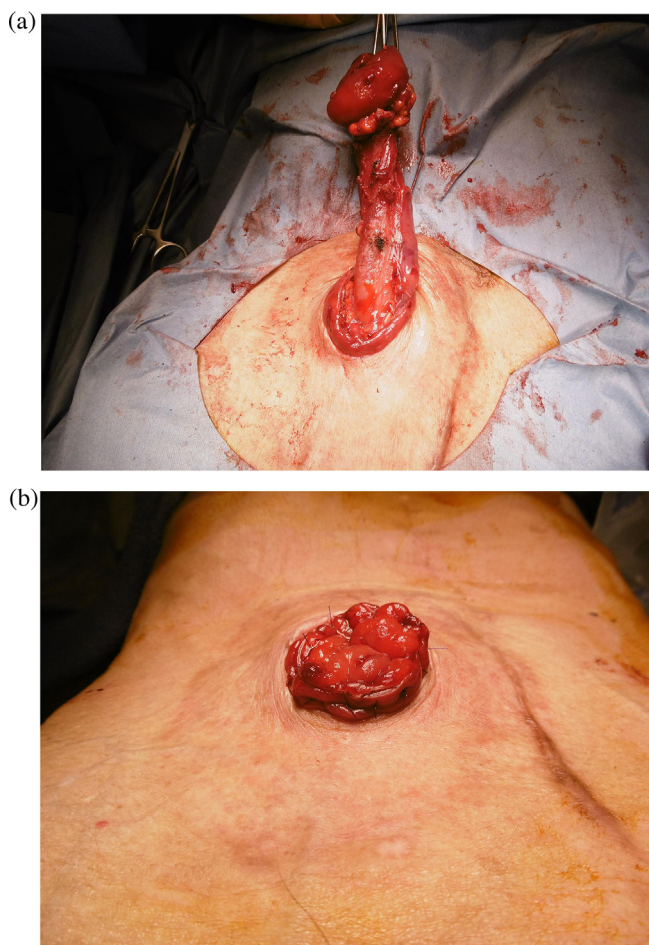
Hartmann's procedure (left hemicolectomy with partial resection of transverse colon and transverse end colostomy) was performed. The patient was discharged on the 11th postoperative day. He was followed up at an ambulatory care center without adjuvant chemotherapy. He continued to receive laxatives for bowel movement control and his abdomen remained distended. Because he had intractable constipation secondary to Parkinson's disease, we assumed that Hartmann's reversal could again lead to intractable constipation and difficulty in defecation because of his low activities of daily living (ADL). Given these clinical presentations and assumptions, Hartmann's reversal was not planned at that time.

Four months after surgery, stoma prolapse occurred and was treated with manual reduction. Six months after surgery, manually irreducible stoma prolapse occurred again and needed surgical intervention (Fig. 2). We performed stomaplasty with full thickness bowel resection, which is similar to the Altemeier procedure (Fig. 3).

Eight months after stomaplasty, stoma prolapse recurred with evident bowel dilatation (Fig. 4). We considered stoma reversal to be a favorable treatment option for recurrent stoma prolapse because of the failure of the local procedure in this case. However, we believed that stoma reversal alone potentially led to worsening of intractable constipation. Therefore, we concluded that the resection of the remnant colon with ileorectal anastomosis could be an optimal treatment option to resolve these problems. We performed right colectomy and ileorectal anastomosis instead of Hartmann's reversal (colorectal anastomosis). At 1.5 years after the last surgery, complications such as small bowel obstruction, difficulty in defecation, or fecal incontinence were not detected.

### 3. Discussion

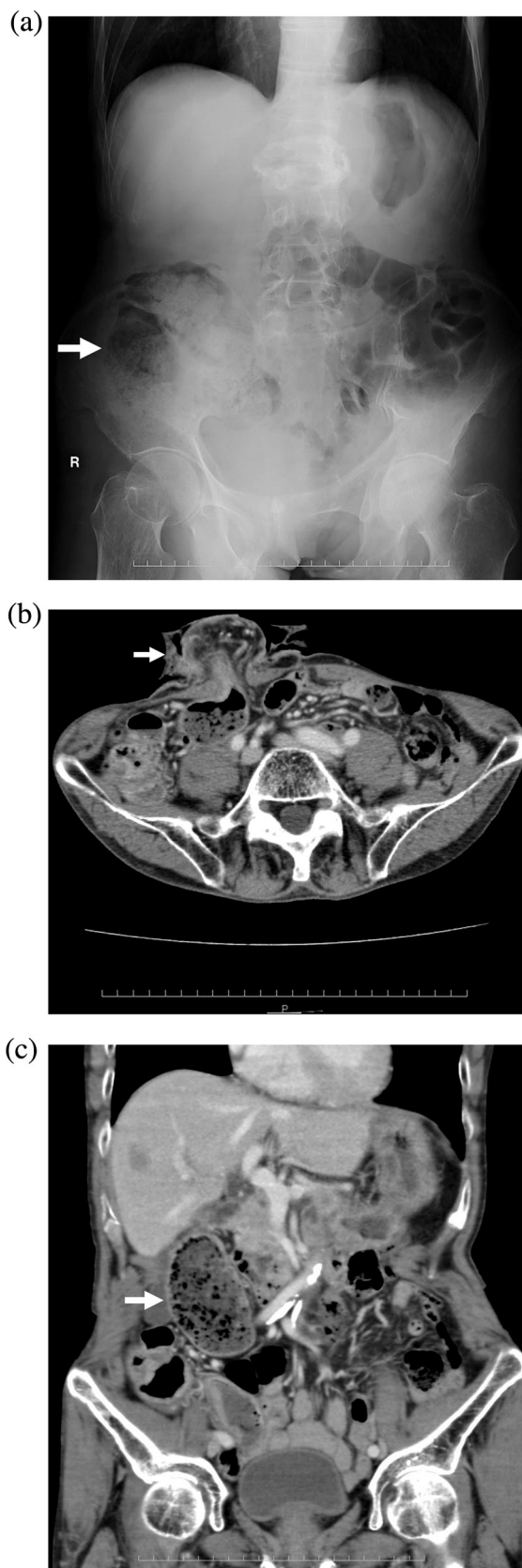
The cause of stoma prolapse is generally ascribed to various anatomical factors such as redundant intestine, high intra-abdominal pressure, and intraperitoneal route. Stoma prolapse is also influenced by other factors, including old age, obesity, stoma constriction during bowel obstruction, and the lack of preoperative site markings by the enterostomal nurse [5]. In this case, risk factors for stoma prolapse included old age, transverse colostomy, and stoma construction during large bowel obstruction. Additionally, continuously increasing intra-abdominal pressure was a result



**Fig. 3.** A full-thickness circumferential incision was made on the bowel 1–2 cm from the mucocutaneous junction (a). The prolapsed bowel was excised and an anastomosis was performed (b).

of intractable constipation secondary to Parkinson's disease, which might have played a crucial role in the recurrence of stoma prolapse.

Constipation is one of the initial nonmotor symptoms affecting approximately 50%–80% of patients with Parkinson's disease. Constipation often occurs early during the disease and may precede the appearance of motor symptoms by several years [6,7]. In the early stages of Parkinson's disease, decreased gastrointestinal motility has been associated with neuronal loss in the myenteric and submucosal plexi and inclusions of Lewy bodies in the dorsal motor nucleus of the vagus, emphasizing their potential role in slowing intestinal peristalsis [8]. Our patient had intractable constipation since the diagnosis of Parkinson's disease. Furthermore, CT after the initial surgery showed dilatation of the remnant colon with fecal mass, which might be attributable to chronic colonic motility disorder. The nonmotor symptoms of Parkinson's disease were considered the primary cause of intractable constipation; however, colonic dysmotility could also be explained by decreased ADL due to Parkinson's disease. We detected recurrent stoma prolapse after Hartmann's procedure in the patient with a pathological background. We initially indicated a local procedure (stomoplasty) because the patient had already adapted to his lifestyle with stoma and did not intend to undergo invasive surgery. We considered maintaining the colostomy as a permanent stoma a more favorable treatment option than performing Hartmann's reversal in this case. However, our treatment strategy was complicated by recurrent stoma prolapse. Redo stomoplasty was regarded as one of the options because an easy and effective



**Fig. 4.** Abdominal X-ray visualized dilatation of remnant colon with fecal mass (a) and CT revealed prolapsed colostomy (b) and dilatation of oral side of the colon (c).

technique for local procedure by using a stapler device has been recently reported [9]. However, assuming that the local procedure alone might lead to large bowel dilatation and intractable constipation secondary to Parkinson's disease, we believed that redo stomaplasty would have led to the re-recurrence of stoma prolapse. Subtotal colectomy for constipation secondary to Parkinson's disease has not been previously reported. Nevertheless, subtotal colectomy and ileorectal anastomosis are one of the optimal treatment choices for intractable constipation [10,11]. Although Parkinson's disease may influence motility of all gastrointestinal tract [8], the patient had not developed any signs of small bowel dilatation or obstruction. This finding suggested that the colon was mainly attributed to his intractable constipation, and the small bowel motility was not affected by the disease or his medication including levodopa/carbidopa, amantadine and dopamine agonist. Therefore, we expected that the resection of the dilated proximal colon was a reasonable option for our patient with intractable constipation secondary to Parkinson's disease. Therefore, we assumed that the resection of the remnant proximal colon with ileorectal anastomosis was a more favorable surgical treatment option than anastomosis of the remnant colon and rectum. We subsequently performed ileorectal anastomosis as a sequential surgical treatment for recurrent stoma prolapse.

#### 4. Conclusion

In cases of unsuccessful stoma prolapse treatment using a local procedure, ileorectal anastomosis may be an optimal surgical treatment for stoma prolapse after Hartmann's procedure, particularly in patients with concomitant colonic motility disorder.

#### Conflicts of interest

All authors declare that there is no conflict of interest.

#### Funding

This research did not receive any specific grant from any funding agency in the public, commercial, or not-for-profit sectors.

#### Ethical approval

The institutional ethics committee considers that an ethical approval is not necessary for a case report.

#### Consent

A written consent for the publication of this case report with accompanying images was obtained from the patient. The consent can be provided to the editors of this journal on request.

#### Authors contribution

Study conception and design; Takayama, Tsujinaka.

Data acquisition and interpretation; Takayama, Tsujinaka, Kakizawa, Takahashi.

Surgery and patient follow-up; Tsujinaka, Kakizawa, Someya, Hasegawa.

Preparation of images; Hasegawa, Kikugawa

Drafting the paper; Takayama, Tsujinaka.

Critical revision; Miyakura, Rikiyama.

Final approval of submitting the manuscript; Takayama, Tsujinaka, Kakizawa, Someya, Takahashi, Hasegawa, Kikugawa, Miyakura, Rikiyama.

#### Guarantor

Shingo Tsujinaka, the corresponding author of this paper.

#### References

- [1] S.G. Husain, T.E. Cataldo, Late stomal complications, *Clin. Colon Rectal Surg.* 21 (2008) 31–40.
- [2] D.M. Krishnamurty, J. Blatnik, M. Mutch, Stoma complications, *Clin. Colon Rectal Surg.* 30 (2017) 193–200.
- [3] A.C. Bafford, J.L. Irani, Management and complications of stomas, *Surg. Clin. N. Am.* 93 (2013) 145–166.
- [4] R.A. Agha, A.J. Fowler, A. Saeta, I. Barai, S. Rajmohan, D.P. Orgill, for the SCARE Group, The SCARE statement: consensus-based surgical case report guidelines, *Int. J. Surg.* 34 (2016) 180–186.
- [5] J.J. Park, A. Del Pino, C.P. Orsay, R.L. Nelson, R.K. Pearl, J.R. Cintron, H. Abcarian, Stoma complications: the cook county hospital experience, *Dis. Colon Rectum* 42 (1999) 1575–1580.
- [6] K. Wolters, Constipation in Parkinson's disease, *Ann. Indian Acad. Neurol.* 14 (2011) S15–16.
- [7] W.H. Jost, Gastrointestinal dysfunction in Parkinson's disease, *J. Neurol. Sci.* 289 (2010) 69–73.
- [8] A.A. Poirier, B. Aubé, M. Côté, N. Morin, T. Di Paolo, D. Soulet, Gastrointestinal dysfunctions in Parkinson's disease: symptoms and treatments, *Parkinsons Dis.* 2016 (2016) 6762528.
- [9] K. Masumori, K. Maeda, T. Hinai, Short-term outcomes of local correction of stoma prolapse with a stapler device, *Tech. Coloproctol.* 17 (2013) 437–440.
- [10] J. Pfeifer, Surgical options to treat constipation: a brief overview, *Rozhl. Chir.* 94 (2015) 349–361.
- [11] C.H. Knowles, U. Grossi, M. Chapman, Surgery for constipation: systematic review and practice recommendations: results I: colonic resection, *Colorectal Dis.* 19 (Suppl. 3) (2017) 17–36.

#### Open Access

This article is published Open Access at [sciencedirect.com](https://www.sciencedirect.com). It is distributed under the [IJSCR Supplemental terms and conditions](#), which permits unrestricted non commercial use, distribution, and reproduction in any medium, provided the original authors and source are credited.