

Received: 2013.10.08
Accepted: 2013.12.05
Published: 2014.02.14

Authors' Contribution:

- A** Study Design
- B** Data Collection
- C** Statistical Analysis
- D** Data Interpretation
- E** Manuscript Preparation
- F** Literature Search
- G** Funds Collection

Congenital vascular malformations in scintigraphic evaluation

Stanisław Pilecki^{1,2ABDEFG}, Marcin Gierach^{2ABDEFG}, Joanna Gierach^{2BDEF},
Cyprian Świętaszczyk^{1BDF}, Roman Junik^{2BDF}, Władysław Lasek^{3DF}

¹ Laboratory of Nuclear Medicine, Regional Specialist Hospital in Grudziądz, Grudziądz, Poland

² Laboratory of Nuclear Medicine, Department of Endocrinology and Diabetology, Nicolaus Copernicus University in Toruń, Collegium Medicum in Bydgoszcz, Bydgoszcz, Poland

³ Department and Institute of Imaging Diagnostics, Nicolaus Copernicus University in Toruń, Collegium Medicum in Bydgoszcz, Bydgoszcz, Poland

Author's address: Marcin Gierach, Department of Endocrinology and Diabetology of Ludwik Rydygier, Collegium Medicum in Bydgoszcz, Nicolaus Copernicus University in Toruń, M. Skłodowskiej-Curie 9 Str., 85-094 Bydgoszcz, Poland, e-mail: marcin_gierach@wp.pl

Background:

Congenital vascular malformations are tumour-like, non-neoplastic lesions caused by disorders of vascular tissue morphogenesis. They are characterised by a normal cell replacement cycle throughout all growth phases and do not undergo spontaneous involution.

Here we present a scintigraphic image of familial congenital vascular malformations in two sisters.

Material/Methods:

A 17-years-old young woman with a history of multiple hospitalisations for foci of vascular anomalies appearing progressively in the upper and lower right limbs, chest wall and spleen. A Parkes Weber syndrome was diagnosed based on the clinical picture. Due to the occurrence of new foci of malformations, a whole-body scintigraphic examination was performed.

A 12-years-old girl reported a lump in the right lower limb present for approximately 2 years, which was clinically identified as a vascular lesion in the area of calcaneus and talus. Phleboscintigraphy visualized normal radiomarker outflow from the feet via the deep venous system, also observed in the superficial venous system once the tourniquets were released. In static and whole-body examinations vascular malformations were visualised in the area of the medial cuneiform, navicular and talus bones of the left foot, as well as in the projection of right calcaneus and above the right talocrural joint.

Conclusions:

People with undiagnosed disorders related to the presence of vascular malformations should undergo periodic follow-up to identify lesions that may be the cause of potentially serious complications and to assess the results of treatment. Presented scintigraphic methods may be used for both diagnosing and monitoring of disease progression.

Keywords:

congenital vascular malformations • scintigraphy • ^{99m}Tc-RBC

PDF file:

<http://www.polradiol.com/download/index/idArt/889874>

Background

Congenital vascular malformations (CVM) are tumour-like, non-neoplastic lesions caused by disorders of vascular tissue morphogenesis. They are characterised by a normal cell replacement cycle throughout all growth phases and do not undergo spontaneous involution. The degree of vessel

density determines the classification of vascular malformations into capillary, venous, arterial, lymphatic and mixed types [1,2].

Although these lesions are inborn, they may remain occult until puberty and adulthood. The lesions usually occur singly. Familial occurrence was reported sporadically, e.g.,




Figure 1A. Phleboscintigraphy: proper radiomarker outflow from the feet, mainly via the deep venous system, also after tourniquet release in the 5th minute of examination.

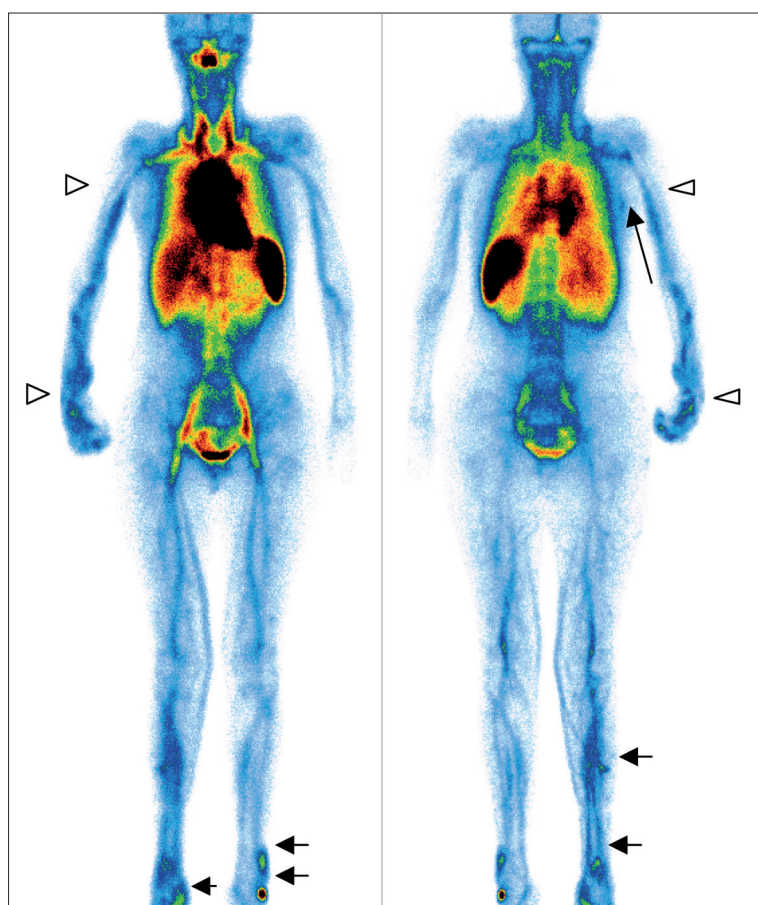


Figure 1B. Whole-body examination using ^{99m}Tc-RBC. Vascular malformation detected in the projection of the right tarsus, in the distal end and in the middle part of the right crus, as well as above the lateral malleolus of the lower left limb (short arrows). Visible deformation of the upper right limb; vascular malformations are visible mainly in the hand and forearm, reaching the proximal 1/3 of the forearm length (arrowheads). A small vascular lesion was also visualised in the posterolateral part of the chest on the right side (long arrow).

involving congenital venous malformations caused by a particular mutation in the VMCM-1 gene on chromosome 9p [3].

We present a scintigraphic pictures of congenital vascular malformations occurring familiarly in two sisters.

Material and Methods

In both cases, scintigraphic examinations were conducted in two stages.

Stage one: phleboscintigraphy of lower limbs. Pyrophosphate was administered intravenously to sensitise red blood cells and subsequently, following application of tourniquets above the ankles, 100 MBq sodium pertechnetate [^{99m}Tc]⁻ was administered into the dorsal veins of both feet. The field of view of the gamma camera in anterior projection covered the feet and the crura. Duration of dynamic examination was 7 minutes, with tourniquets released in the 5th minute. Subsequently, 100 MBq sodium pertechnetate was administered into the dorsal veins of both feet for the second time and radiation detector was positioned at

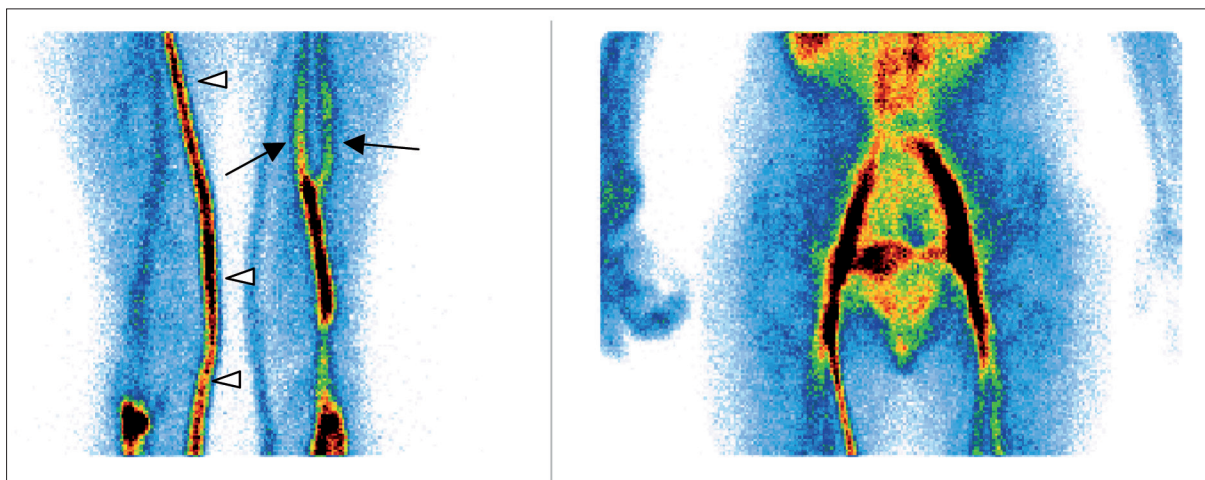


Figure 1C. Static image of the thighs and pelvis. Elimination of the radiotracer from feet, on the right side mainly via the saphenous vein (arrowheads), on the left side via the deep venous system, left femoral vein conduplicated (arrows).

the level of the knees and thighs (static examination lasted 5 minutes). A 100-MBq marker dose was administered again for imaging of pelvic veins (duration of static examination was 5 minutes).

Stage two: examination of the whole body. A whole-body examination, which involved the presence of erythrocytes labelled with ^{99m}Tc -RBC in the organism, was conducted 30 minutes after pyrophosphate administration.

Scintigraphic examinations were conducted using a single-head gamma camera. Technical specifications of the camera were: rectangular crystal, detector field of view: 39×53 , detector diagonal: 65, number of photomultipliers: 59. A low-energy, high-resolution collimator (?) was used.

Case 1

A 17-years-old girl with a history of multiple hospitalisations (since the age of 6) for foci of vascular anomalies progressively appearing in the upper and lower right limbs, chest wall and spleen. The lesions were accompanied by pain and visible deformation of affected areas. In the last 10 years, growth retardation of the upper right limb was observed (probably caused by ischemia due to the steal syndrome) along with increased dolorific sensations. Parkes Weber syndrome was diagnosed based on the clinical picture. Due to the occurrence of new foci of malformations, a whole-body scintigraphic examination was performed.

Correct radiomarker outflow from the feet via the deep venous system was visualised in phleboscintigraphy (Figure 1A). In the subsequent static scintigrams the marker also appeared in the superficial system, mainly in the saphenous veins, demonstrating better radiomarker elimination via the right saphenous vein. In the whole-body examination, vascular malformations were detected in the projection of the right tarsus, in the distal end and in the middle part of the right crus, as well as in the left tarsus and above the lateral malleolus of the lower left limb (Figure 1B). Visible vascular malformations in the upper right limb were present mainly in the hand and forearm, reaching proximal 1/3 of the forearm (Figure 1B). A small

vascular lesion was also visualised in the posterolateral part of the chest, on the right side (Figure 1B). Static examination also allowed us to detect an anatomic variant, femoral vein duplication, in the upper part of the right thigh (Figure 1C).

Case 2

A 12-years old girl reported a lump of the lower right limb, which had been present for approximately 2 years and was clinically identified as a vascular lesion in the area of calcaneus and talus. Several months before the examination, a new vascular malformation appeared near the left knee.

In phleboscintigraphy, a correct radiomarker outflow from the feet via the deep venous system was visualised, which was also observed in the superficial venous system once the tourniquets were released. Vein enlargement was observed at that stage in both feet, but proper assessment of those areas was unreliable due to the localisation of injection sites (Figure 2A). In the static and whole-body examinations, vascular malformations were visualised in the area of the medial cuneiform, navicular and talus bones of the left foot, as well as in the projection of the right calcaneus and above the right talocrural joint. A small haemangioma was also detected in the index finger of the right hand (Figure 2B). A vascular lesion in the area of the lateral epicondyle of the left femur was best visualised in the static examination of the thighs (Figure 2C). Moreover, accessory saphenous veins were identified.

Results

Congenital vascular (arteriovenous) malformations of the limbs are some of the greatest diagnostic and therapeutic challenges. Although vascular malformations are congenital, they are not always found in infants and may present at different times from birth. The most common localisations are head and neck (40%), limbs (40%) as well as corpus (20%) [1–3]. Clinical manifestations vary from lack of symptoms to life-threatening congestive heart failure [1–3].

The symptoms of Parkes Weber syndrome are similar to those of Klippel-Trénaunay syndrome, a rare congenital

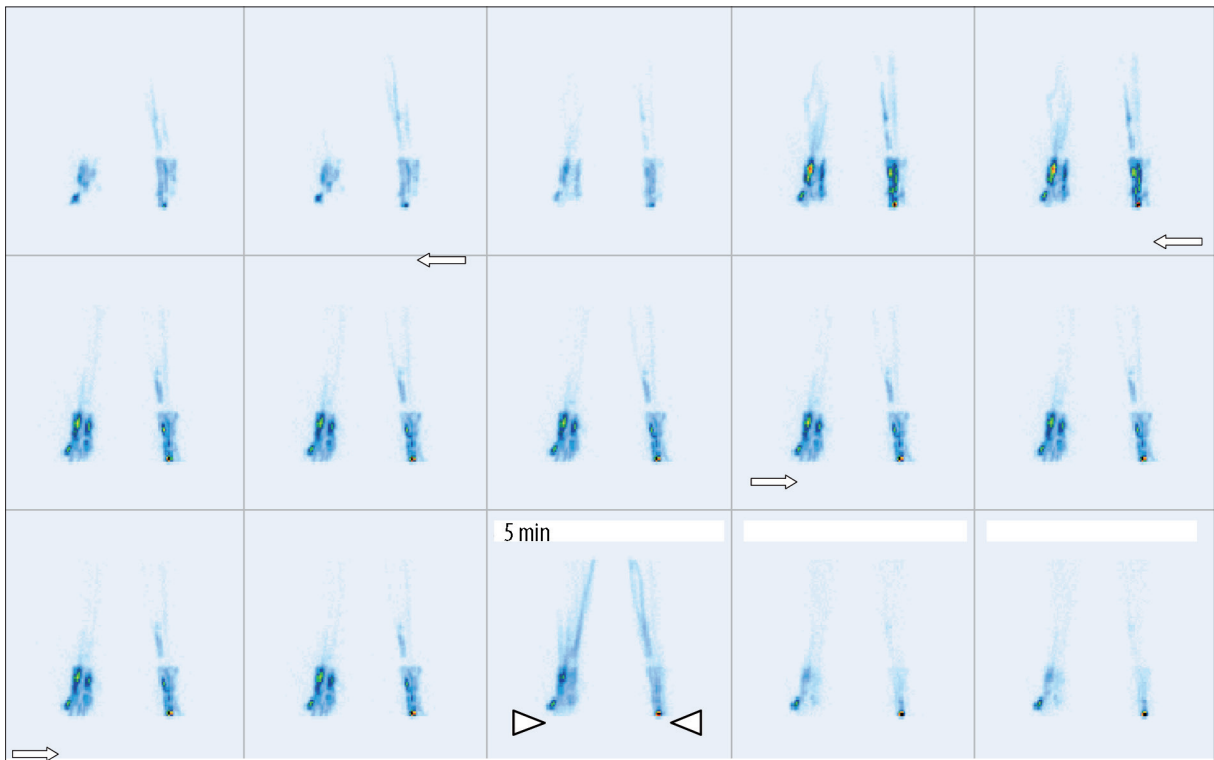


Figure 2A. Phleboscintigraphy. Proper radiotracer outflow from the feet was observed via the deep venous system and, after tourniquet release in the 5th minute of examination (arrowheads), also via the superficial venous system. Enlargement of pedal vessels may be observed (arrows).

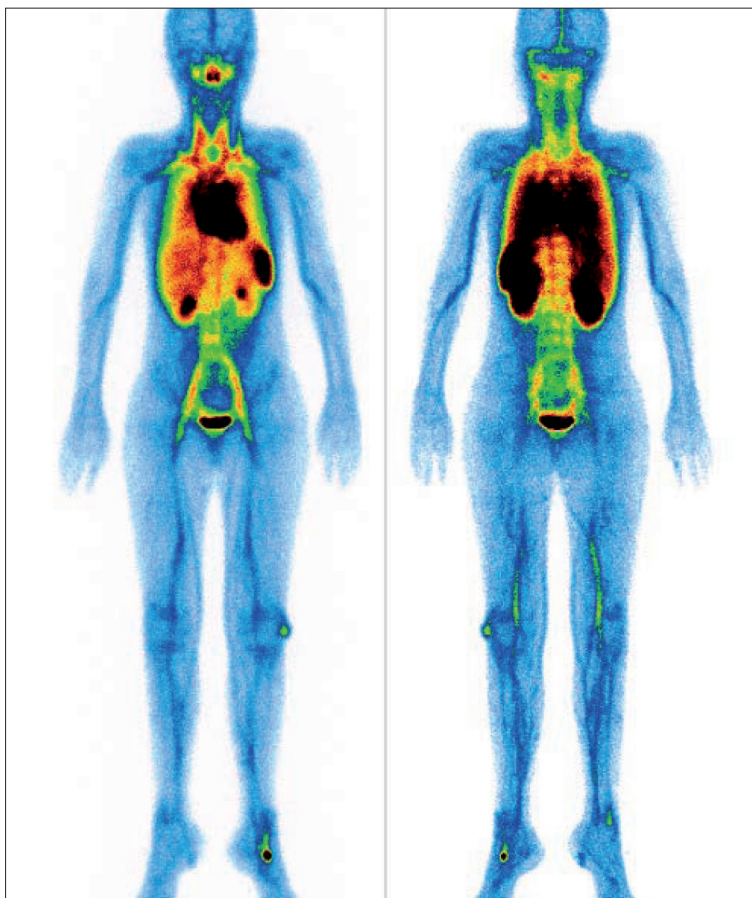


Figure 2B. Whole-body examination using ^{99m}Tc-RBC. Multiple vascular malformations are present in the left tarsus, in the projection of the right calcaneus bone and above the right talocrural joint, as well as in the area of the lateral epicondyle of the left femur and in the index finger of the right hand (arrows).

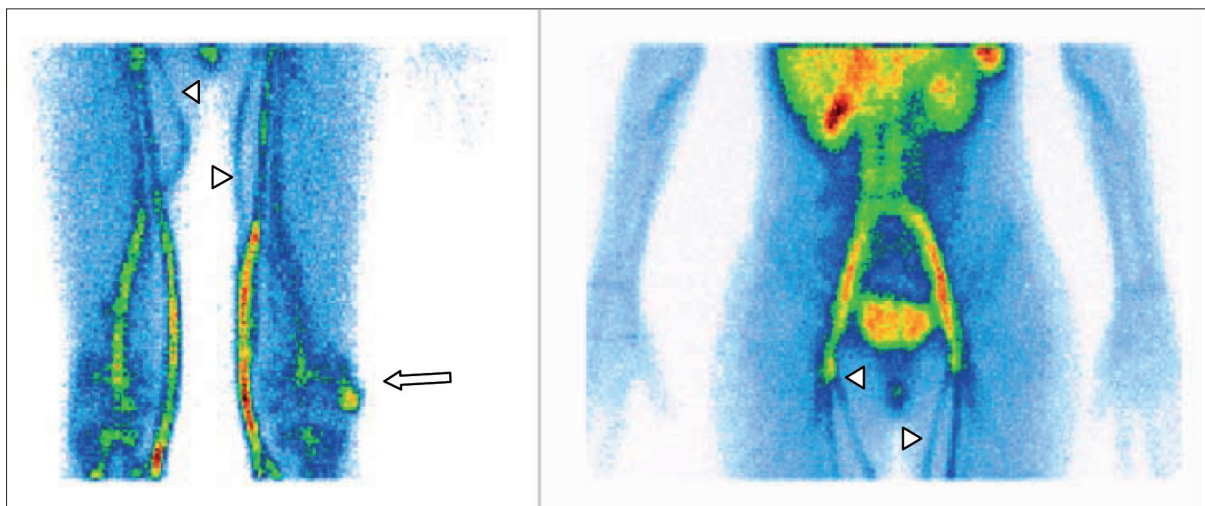


Figure 2C. Static image of the thighs and pelvis. A vascular lesion is visible in the region of lateral epicondyle of the left femur (arrow). Moreover, accessory saphenous veins are visualized (arrowheads).

disorder characterised by a triad of symptoms: capillary malformations (port-wine stains), varices, as well as soft tissue and bone hypertrophy. The syndrome may be diagnosed if 2 out of 3 criteria are met. Additionally, arteriovenous fistulas are present in Parkes Weber syndrome. Etiology of the disorder is unknown. It is believed that at the background of this disorder lies a mesodermal defect, which leads to local alteration of regulation and production of growth factors controlling the process of angiogenesis. Most cases are sporadic, although there are also cases of familial incidence of the disorder. The most variable trait of the disorder is hypertrophy, which occurs in approx. 70% cases. The lower, upper or both groups of limbs are affected in 95%, 5% and 15% of cases, respectively [4,5]. In most patients lesions appear unilaterally [4–6].

Presence of vascular malformations in body organs and tissues may cause clinical symptoms and may be visualised using various diagnostic imaging techniques. Proper diagnosis of those disorders is important, as they may involve multiple complications. The complications of Klippel-Trénaunay syndrome are usually related to the vascular system [6]. These include: stasis dermatitis, thrombophlebitis and inflammation of subcutaneous tissue (cellulitis). Among the most severe complications are the following: deep vein thrombosis, pulmonary embolism, coagulopathy and congestive heart failure (in patients with coexisting arteriovenous malformations) [6].

Various imaging techniques are used to assess the character of the lesions (e.g., size, blood flow rate and direction, ratio of malformations to the surrounding tissues, such as vessels, muscles, nerves, bones, skin).

Radiological methods such as phlebography and angiography are particularly important in preoperative assessment, also before vascular surgery procedures (sclerotherapy and embolisation), yet these techniques are invasive and involve radiation exposure.

However, nowadays there are many other methods available, mostly non-invasive, which offer the possibility to

formulate an accurate diagnosis of every CVM type, confirming clinical suspicion. CVM diagnosis may be given based on non-invasive and minimally invasive procedures, such as: Doppler ultrasonography (colour Doppler (CD) and power Doppler (PD)), whole-body blood pool scintigraphy (WBBPS), transarterial lung perfusion scintigraphy (TLPS) and radionuclide lymphoscintigraphy [7,8].

Conventional radiography plays a minor role in the process of diagnosis and classification of vascular lesions [1], but provides useful information on bone and joint infiltration by the disease. Signs, such as bone deformations, bone remodeling with foci of osteolysis or osteosclerosis, and pathological fractures suggesting bone infiltration by the disease are visualized.

Ultrasonography is a basic, non-invasive method widely used for the assessment of the vascular system. By using sonography methods employing Doppler phenomenon (CD and PD), the anatomy of both superficial and deep venous systems and arteriovenous fistulas may be assessed, along with the complications resulting from the disorder, such as venous thrombosis [6].

Computed tomography with intravenous contrast administration is a useful method of assessment of vascular malformation. However, CT examination involves exposure to a considerable dose of radiation, contrast agents are neurotoxic (nephrotoxic?), while the examination itself does not provide much information on blood flow.

MR is the most valuable method for classification of vascular malformations. By using arteriography and venography, MR may be used to assess both the type and the extent of vascular malformations in Parkes Weber syndrome. In particular, MR allows for differentiation between malformations with slow (venous) and fast (arteriovenous) blood flow. Arteriovenous malformations related to Parkes Weber syndrome are characterised by fast flow, as they are supplied by arteries. MR clearly visualizes anatomic relations between the vascular lesion and surrounding tissues.

Modern procedures in patients with CVM may be improved by using scintigraphic techniques. However, this type of examination rarely holds top positions in diagnostic algorithms. In case of CVM, scintigraphic techniques were initially used in addition to other basic diagnostic methods. Phleboscintigraphy employing pertechnetate ($^{99m}\text{TcO}_4^-$) is a cheap method. The radioisotope is available in every nuclear medicine institute and may be easily applied. Another advantage of this method is its administration site (foot), which is commonly accepted by the patients, low tracer volume, rare local and systemic complications related to radioisotope administration [8]. Whole-body blood pool scintigraphy (WBBPS) is an inexpensive, simple, safe and non-invasive examination, particularly useful in the assessment of venous and arteriovenous malformations. The method is efficient and accurate in determination of treatment outcome [9]. It may be used for screening in cases of CVMs disseminated in different body parts. It allows both qualitative and quantitative assessment of vascular malformations, especially during the multistage procedure of sclerotherapy. The method is an ideal tool for routine tests in the assessment of therapeutic progress and natural course of the disease [10]. It allows for obtaining images of the entire body, thus directing further, more detailed imaging, i.e. ultrasonography, to specific body regions. It implies a relatively low radiation burden to the patient, summing up to about 4.2 mSv per administrated 600 MBq of Tc-99m-pertechnetate.

References:

- Hyodoh H, Hori M, Akiba H et al: Peripheral vascular malformation: imaging, treatment approaches, and therapeutic issues. *Radio Graphics*, 2005; 25: 159–71
- Lee BB, Laredo J, Lee TS et al: Terminology and classification of congenital vascular malformations. *Phlebology*, 2007; 22: 249–52
- Domp Martin A, Vikkula M, Boon L et al: Venous malformation: update on etiopathogenesis, diagnosis and management. *Phlebology*, 2010; 25: 224–35
- Begum S, Nowosinska E, Buscombe J: Abnormal Tc99m sulesomab in Klippel-Trenaunay syndrome. *Nucl Med Rev Cent East Eur*, 2010; 13(2): 84–86
- Awad AN, Yang DC, Girgis M et al: Evaluation of Klippel-Trenaunay syndrome with radionuclide total body angiography. A case report. *Clin Nucl Med*, 1992; 17: 866–70
- Elsayes K, Menias C, Dillman J et al: Vascular malformation and hemangiomatosis syndromes: spectrum of imaging manifestations. *Am J Roentgenol*, 2008; 190(5): 1291–99
- Lee BB: Changing concept on vascular malformation: no longer enigma. *Ann Vasc Dis Vol*, 2008; 1: 11–19
- Pilecki S, Mackiewicz-Milewska M, Gierach M et al: Miejsce fleboscyntygrafii w diagnostyce obrazowej układu żylnego kończyn dolnych. *Polski Przegląd Chirurgiczny*, 2009; 81: 375–88 [in Polish]
- Lee BB, Mattassi R, Kim BT et al: Contemporary diagnosis and management of venous and arterio-venous shunting malformation by whole body blood pool scintigraphy. *Int Angiol* 2004, 23: 355–66
- Lee BB, Bergan J, Gloviczki P et al: Diagnosis and treatment of venous malformations. Consensus document of the International Union of Phlebology – 2009. *Int Angiol*, 2009; 28: 434–511

Conclusions

People with undiagnosed disorders related to the presence of vascular malformations should undergo periodic follow-up to identify lesions, which may be the cause of potentially serious complications and to assess results of treatment. Presented scintigraphic methods (phleboscintigraphy + whole-body examination using $^{99m}\text{Tc-RBC}$) may be used for both diagnosing and monitoring of disease progression.

Consent

Written informed consent was obtained from the patients for publication of this Case report and any accompanying images.

Competing interests

The authors assure that they have no conflicting interests.

Acknowledgements

We are grateful to the hospital staff of the Laboratory of Nuclear Medicine of the Department of Endocrinology and Diabetology, Nicolaus Copernicus University in Torun, Collegium Medicum in Bydgoszcz for making this study possible.