



Vascular Complications Related to Posterior Lumbar Disc Surgery

Hong Sung Jung, Dae Jung Kim, Hyo Shin Kim, Ho Kyun Lee, Soo Jin Na Choi, and Sang Young Chung

Department of Surgery, Chonnam National University Hospital, Gwangju, Korea

Purpose: To evaluate patients who underwent surgical or endovascular treatment after vascular injury related to posterior lumbar disc surgery.

Materials and Methods: We retrospectively reviewed seven cases of vascular injuries (four lacerations, one arteriovenous fistula [AVF], and two pseudoaneurysms) related to lumbar disc surgery by a posterior approach from January 1997 to December 2016 at Chonnam National University Hospital. Information of patient characteristics, diagnosis, treatment strategies, and outcomes were analyzed.

Results: Five out of seven cases were in-hospital cases. In three laceration cases, each patient instantly became hypotensive and a life-threatening arterial injury was suspected. Therefore, the patient was immediately turned to the supine position and surgical repair was performed. The patients with pseudoaneurysm and AVF were treated by endovascular intervention. Remaining two were referred cases under the impression of vascular injuries. One laceration case of them was in pre-shock condition, and the left common iliac artery was surgically repaired. The other referred patient showed pseudoaneurysm which was treated with stent graft insertion. There was no surgery or endovascular intervention related death and none of the patients suffered any sequela related to vascular injury.

Conclusion: Vascular injury associated with posterior lumbar disc surgery is not common, but can be fatal. Early recognition, diagnosis, and prompt treatment are essential to prevent fatal outcomes. Recently, endovascular intervention is increasingly and preferably used because of its low morbidity and mortality. However surgery is still the best option for the patients with unstable vital sign and endovascular approach can be applied to stable patients.

Key Words: Vascular system injuries, Dissectomy, Vascular surgical procedures, Endovascular procedures

Received November 23, 2017

Revised (1st) November 27, 2017

(2nd) November 29, 2017

Accepted November 29, 2017

Corresponding author: Sang Young Chung

Department of Surgery, Chonnam National University Hospital, 42 Jebong-ro, Dong-gu, Gwangju 61469, Korea
Tel: 82-62-220-6456

Fax: 82-62-227-1635

E-mail: sycpvts@chonnam.ac.kr

Conflict of interest: None.

Copyright © 2017, The Korean Society for Vascular Surgery

This is an Open Access article distributed under the terms of the Creative Commons Attribution Non-Commercial License (<http://creativecommons.org/licenses/by-nc/4.0>) which permits unrestricted non-commercial use, distribution, and reproduction in any medium, provided the original work is properly cited.

Vasc Spec Int 2017;33(4):160-165 • <https://doi.org/10.5758/vsi.2017.33.4.160>

INTRODUCTION

Lumbar disc surgery through a minimally invasive or open posterior approach is the most commonly performed neurosurgical procedure related to the spine. Vascular complications related to posterior lumbar disc surgery are not

common. Incidence of major vascular injury is rare (0.01%-0.05%) [1,2] but mortality rate is as high as 10% to 65% [2,3]. Early recognition, diagnosis, and prompt treatment are essential and can potentially prevent fatal outcomes of this life-threatening condition. Treatment choice depends on the type of injury, and it includes traditionally performed

surgical repair by Linton and White [4] and endovascular repair first reported by Zajko et al. [5].

In this study, we evaluated the patients who underwent surgical or endovascular treatment after vascular injury related to posterior lumbar disc surgery.

MATERIALS AND METHODS

From January 1997 to December 2016, seven patients with abdominal vascular injury following posterior lumbar disc operation were included in this study. We retrospectively analyzed the clinical characteristics, treatment modalities, and outcomes of these patients. Treatment option was chosen by the vascular surgeon according to the patient status. Abdominal computed tomography (CT) scanning was used for follow-up.

RESULTS

Four patients were male and the median age at the time of treatment was 56 years, with a range of 27 to 75 years. Discectomy through a posterior approach was performed for a herniated lumbar disc in all patients: between the fourth and fifth lumbar vertebrae in five patients and between the fifth lumbar and first sacral vertebrae in two patients. A conventional discectomy was performed in four patients and an endoscopic discectomy was performed in the other three patients. Types of injury include four laceration cases, two pseudoaneurysms and one arteriovenous fistula (AVF). Sites of injury were the right common iliac artery (CIA) in three patients and the left CIA in four patients. And solitary venous injury was not found in all cases except AVF. Five cases were in-hospital cases. In three laceration cases, each patient instantly became hypotensive, and a life-threatening arterial injury was suspected. Therefore, the patient was immediately turned to the supine position

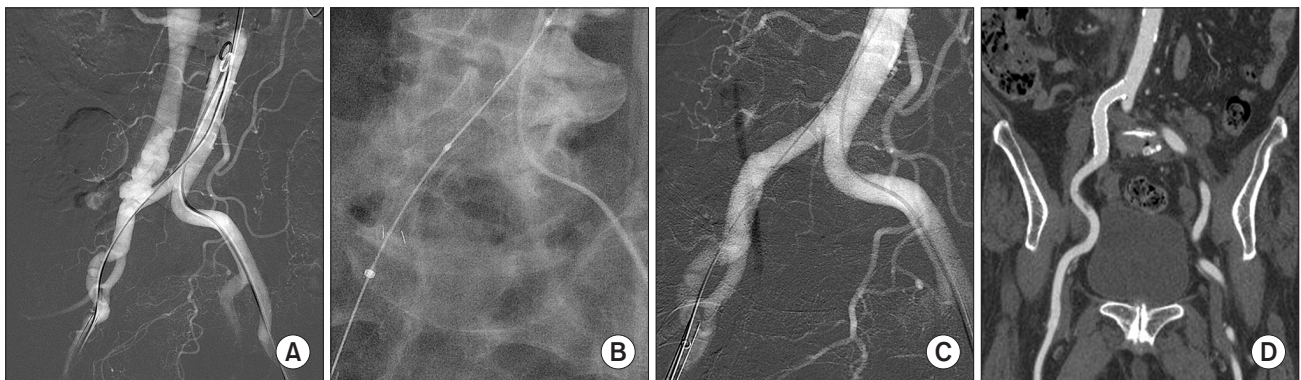


Fig. 1. (A) Sixty months after discectomy, angiography shows arteriovenous fistula between the right common iliac artery (CIA) and vein. (B) Covered stent deployment was performed. (C) Completion angiography showed no fistula between the right CIA and vein. (D) Two months after intervention, follow-up computed tomography shows no evidence of fistula.

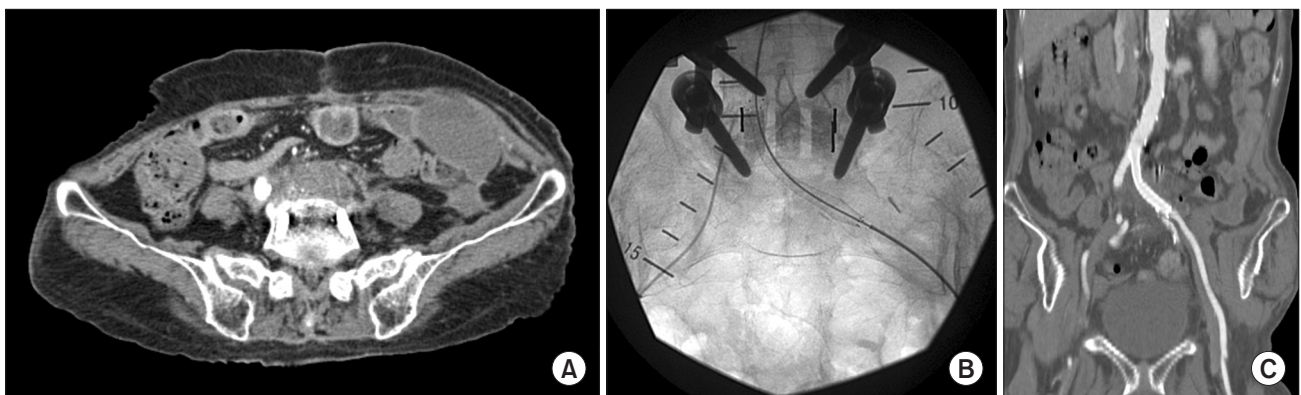


Fig. 2. (A) Twenty three months after discectomy. Computed tomography (CT) angiogram shows thrombosed pseudoaneurysm of left common iliac artery with total occlusion. (B) Covered stent deployment was performed. (C) Three days after intervention, follow-up CT shows complete exclusion of pseudoaneurysm.

and surgical repair was performed. AVF and pseudoaneurysm cases were treated by endovascular repair (Fig. 1, 2). Remaining two cases were referral cases under the impression of vascular injuries. One laceration case of them was in preshock condition. Laceration of the left CIA was surgically repaired with graft interposition (Fig. 3). The other case was a pseudoaneurysm case which was treated with endovascular stent graft insertion (Fig. 4). For the patients who underwent endovascular stent graft insertion or graft interposition, we used prostaglandin E1 and unfractionated heparin or low molecular weight heparin for 1-week as post-procedural anti-thrombotic treatment. Also aspirin and cilostazol were used as antiplatelet agent. Clinical characteristics of seven patients are summarized in Table 1. The time intervals between the discectomy and recognition of the vascular injury were during the operation in three cases, two weeks in two cases, 23 months in one case, and 60 months in one case. Median follow-up period was eight years, with a range of six years to 20 years. There was no surgery or endovascular intervention related death and none of the patients suffered any sequela from vascular injury.

DISCUSSION

Abdominal vascular injury following an operation for a herniated lumbar disc is a major complication because of the close anatomical relation between the lumbar vertebrae and major vessels. Although Szolar et al. [6] reported an

incidence of 0.05% (4/8,099) for vascular complications in herniated lumbar disc operation, iatrogenic vascular injuries might be underestimated since pseudoaneurysm and AVF can be clinically silent as shown fiveyear late detection case in our series. Seventy-five percent of vascular injuries resulted from surgery for herniated lumbar disc at the level of the fourth to fifth lumbar vertebral interspace. In addition to the anatomical relation between the large vessels and lumbar vertebrae, discectomy between the fourth and fifth lumbar vertebrae is the most commonly performed procedure for this disorder and the vessels at this level are particularly vulnerable to injury because of their relative immobility and proximity to the vertebrae when the patient is in the prone position. Distance between the fourth and fifth lumbar intervertebral space and common iliac vessel was less than 5 mm in 66% of female. Such proximity of fifth lumbar and first sacral intervertebral space and the vessel was observed in 23% of female and 19% of male [7,8].

During an operation for a herniated lumbar disc, laceration can be formed when the anterior spinal ligament is penetrated and the adjacent artery and vein are perforated as surgical instruments enter the disc space. The first sign of vascular injury is hemorrhage. However, hemorrhage may first be tamponed in the retroperitoneal space and the AVF and/or pseudoaneurysm may form later. Papadoulas et al. [2] reported incidence of vascular injury complicating lumbar disc surgery is 66%, 33%, and 3% for AVF, laceration, and pseudoaneurysm, respectively. According to van Zitteren et al. [9], lacerations were the most commonly reported

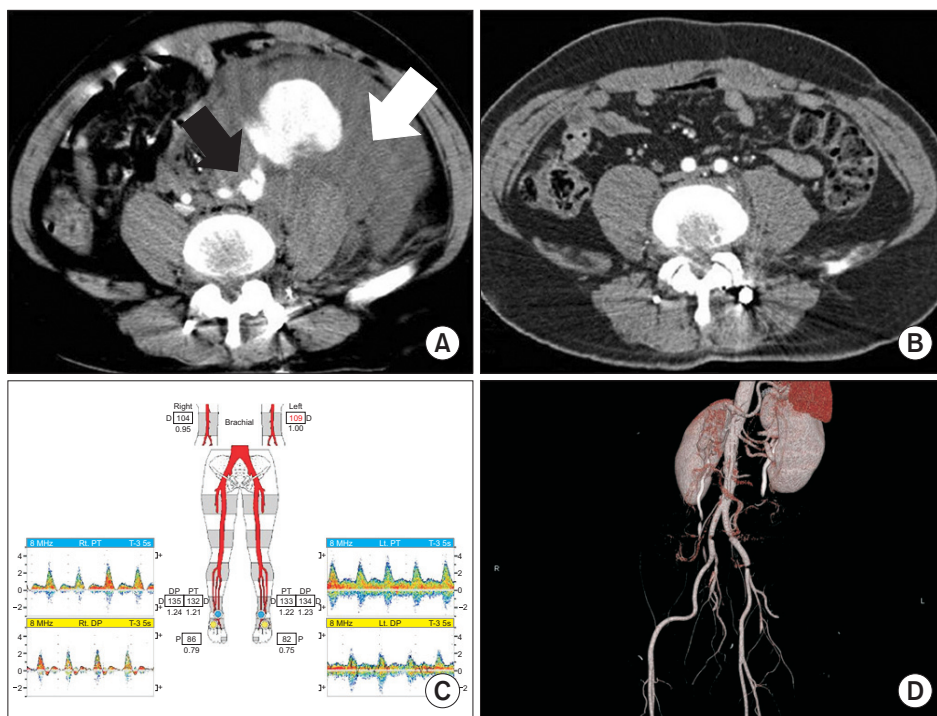


Fig. 3. (A) After discectomy, computed tomography (CT) shows hematoma in retroperitoneum (white arrow) and extravasation with a leakage of dye at the left common iliac artery (CIA) (black arrow). (B) After exploration and primary repair of the left CIA, CT shows no evidence of extravasation and aneurysm. (C) Fifteen years after surgery, follow-up vascular lab finding shows no evidence of abnormal finding. (D) Also CT angiography shows no evidence of abnormal finding. PT, posterior tibial; DP, dorsalis pedis.

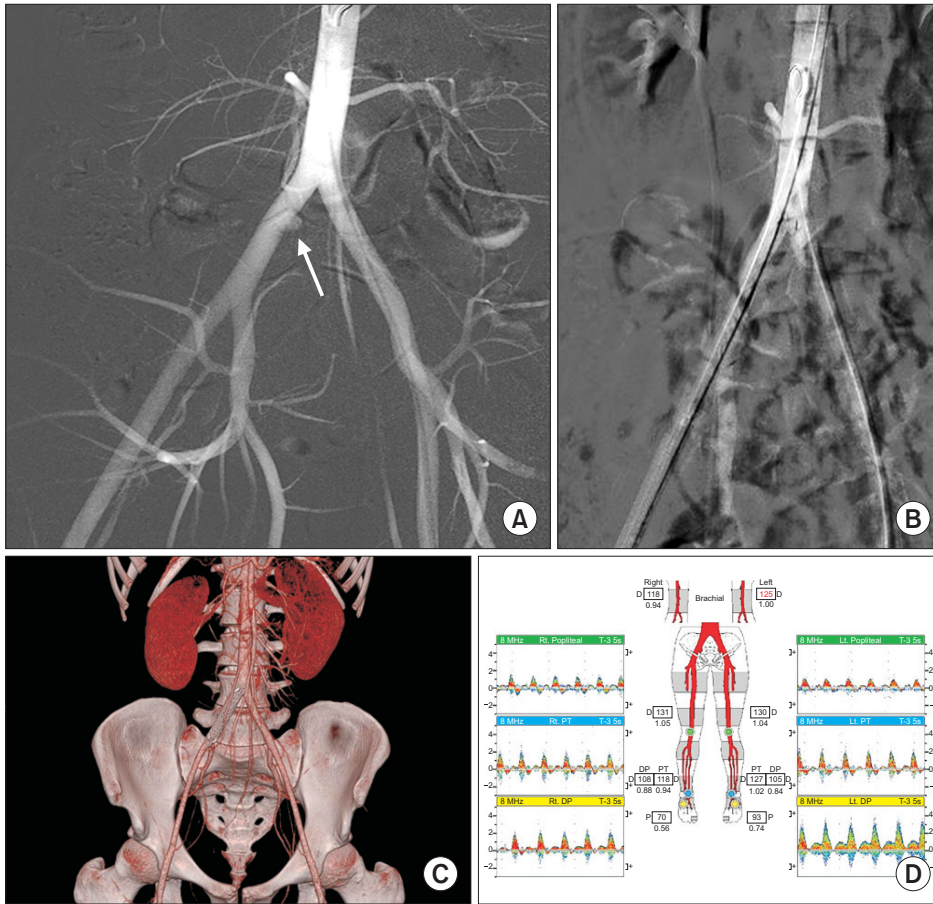


Fig. 4. (A) Two weeks after discectomy, angiography shows pseudoaneurysm of the right common iliac artery (CIA) (arrow). (B) Covered stent deployment was performed. (C) One week after intervention, computed tomography angiogram shows successful exclusion of pseudoaneurysm of right CIA. (D) 10 days after intervention, follow-up vascular lab shows no abnormal finding. PT, posterior tibial; DP, dorsalis pedis.

Table 1. Clinical characteristics of seven consecutive patients

| Patient | Sex/age (y) | Laminectomy (level) | Interval | Pathology | Site | Treatment |
|---------|-------------|----------------------|----------------------|----------------|-----------|-----------------|
| 1 | M/67 | Conventional (L4-5) | During the operation | Laceration | Left CIA | Surgical repair |
| 2 | M/40 | Conventional (L4-5) | During the operation | Laceration | Right CIA | Surgical repair |
| 3 | F/56 | Endoscopic (L5-S1) | During the operation | Laceration | Left CIA | Surgical repair |
| 4 | F/75 | Endoscopic (L4-5) | 60 mo | AVF | Right CIA | Covered stent |
| 5 | F/70 | Endoscopic (L4-5) | 23 mo | Pseudoaneurysm | Left CIA | Covered stent |
| 6 | M/34 | Conventional (L5-S1) | Day of the operation | Laceration | Left CIA | Surgical repair |
| 7 | M/27 | Conventional (L4-5) | 2 wk | Pseudoaneurysm | Right CIA | Covered stent |

M, male; F, female; L, lumbar; S, sacral; AVF, arteriovenous fistula; CIA, common iliac artery.

type of injury because they were present in more than half of the cases, followed by arteriovenous, pseudoaneurysm, and combinations of arteriovenous and pseudoaneurysm. A total of 86 vessels were affected in 58 patients, wherein the CIA was the most frequently injured vessel (51.2%) followed by the common iliac vein (23.3%), the inferior vena cava (9.3%), and the abdominal aorta (4.7%). Symptoms and findings most commonly related to lacerations included hypotension (84.4%), tachycardia (34.4%), active bleeding (43.8%), decrease in hemoglobin level (25.0%), a tense abdomen (18.8%), an abdominal mass (6.3%), or abdomi-

nal pain (15.6%), whereas AVF and pseudoaneurysm were mostly accompanied by audible bruits (40.7%), abdominal pain (33.3%), an abdominal mass (14.8%), or signs of heart failure (14.8%) [9].

If bleeding occurs and vascular injury is suspected, blood and fluid replacement should be initiated without waiting for development of symptoms of hypovolemic shock, such as hypotension or tachycardia. The operation wound should be immediately closed and followed by an urgent abdominal exploration. In our cases, pulsatile hemorrhage was the first finding. After termination of the operation and closure

of the surgical wound, signs of hypovolemia appeared during the fluid replacement, and urgent abdominal exploration was performed. Therefore, operator should be aware that retroperitoneal or peritoneal bleeding may not be visible from the disc space and may not give a clear warning. In the suspected bleeding patient, intraoperative angiography should be considered.

Many risk factors have been defined in the vascular injury that may develop during surgery for lumbar disc disease; however, no single dominant factor has been noted. The defects in the anterior longitudinal ligament increase the risk of abdominal vascular injury in delayed intra-abdominal surgery, abdominal radiotherapy, peridiscal fibrosis, recurrent disc surgery and ventral disc herniation [10].

Diagnosis of vascular injury was based on clinical symptoms and confirmed through radiologic imaging for all types of injuries or through direct surgical intervention in lacerations. All lacerations were recognized within 24 hours after surgery and were repaired in acute settings, whereas most AVF and pseudoaneurysm were recognized beyond the 24-hour post-operative period (ranging from one day to several years) and were mostly repaired in elective settings [9]. Diagnosis of an AVF or pseudoaneurysm is suspected when early signs of retroperitoneal hemorrhage appear but may often be delayed for weeks or years. Formation of a pseudoaneurysm or an AVF may be gradual and initially produce only a few subtle symptoms [11]. The diagnosis of traumatic iliac AVF is dependent on recognition of its clinical features. The clinical features, such as a large, pulsating abdominal mass and a machinery-like abdominal bruit have been well described by many authors. However, classic features of this pathology may be absent in up to one half of the patients. Absence of characteristic findings, together with the rarity of such lesions and resultant lack of awareness may lead to delay in diagnosis. In patients with iatrogenic AVF, history of the intraoperative massive bleeding episode is one of the most important clues to its diagnosis [12]. Noninvasive diagnostic studies, including color Doppler ultrasound, dynamic CT scanning, or magnetic resonance imaging, can confirm the diagnosis. Angiography is indicated when the clinical findings are unclear or endovascular stent placement is considered an

alternative to a surgical procedure.

Angiography with the intention of intervention is considered the first step in treatment of a large vessel injury following surgery for a herniated lumbar disc at the level between the fourth and fifth lumbar or the fifth lumbar and first sacral intervertebral space. Even if the condition is emergent, a definitive treatment can be achieved when a readymade stent graft is immediately available. Placement of an occlusion balloon proximal to the arterial injury can help the surgeon isolate the lesion with minimal blood loss. The need for awareness of the risk of possible abdominal vascular injury during an operation for a herniated lumbar disc cannot be overemphasized, since the injury is associated with substantial mortality and morbidity rates [2,13,14].

Treatment choice depends on the type and site of injury. Lacerations are repaired in acute settings because of rapid blood loss, whereas AVF and pseudoaneurysm are suitable to be repaired in elective settings. The open approach to control acute bleeding has been traditionally described and recommended to repair lacerations [15]. However, endovascular repair has become an increasingly applied technique for the repair of lacerations, AVF, and pseudoaneurysm because of its benefits. As a consequence, a major shift toward endovascular intervention (e.g., covered stents and coiling) has been observed over the past 15 years for all types of vascular injury [9].

Although our patients experienced no mortality or morbidity during followup period (median eight years), the use of endovascular intervention can eliminate the need for open surgery to repair of iliac pseudoaneurysms and/or AVF. If the patient is hemodynamically unstable, surgical approach is the best option. And endovascular intervention can be used as alternative for stable patients to reduce the perioperative morbidity and mortality rates.

In conclusion, early recognition, diagnosis, and prompt treatment are essential to prevent fatal outcomes in vascular injuries complicating posterior lumbar disc surgery. Recently, endovascular intervention is increasingly and preferably used because of its low morbidity and mortality. However surgery is still the best option for the patients with unstable vital sign and endovascular approach can be applied to stable patients.

REFERENCES

- 1) Ewah B, Calder I. Intraoperative death during lumbar discectomy. *Br J Anaesth* 1991;66:721-723.
- 2) Papadoulas S, Konstantinou D, Kourea HP, Kritikos N, Haftouras N, Tsolakis JA. Vascular injury complicating lumbar disc surgery. A systematic review. *Eur J Vasc Endovasc Surg* 2002;24:189-195.
- 3) DeSaussure RL. Vascular injury coincident to disc surgery. *J Neurosurg* 1959;16:222-228.

- 4) Linton RR, White PD. Arteriovenous fistula between the right common iliac artery and the inferior vena cava: report of a case of its occurrence following an operation for a ruptured intervertebral disc with cure by operation. *Arch Surg* 1945;50:6-13.
- 5) Zajko AB, Little AF, Steed DL, Curtiss EI. Endovascular stent-graft repair of common iliac artery-to-inferior vena cava fistula. *J Vasc Interv Radiol* 1995; 6:803-806.
- 6) Szolar DH, Preidler KW, Steiner H, Riepl T, Flaschka G, Stiskal M, et al. Vascular complications in lumbar disk surgery: report of four cases. *Neuroradiology* 1996;38:521-525.
- 7) Anda S, Aakhus S, Skaanes KO, Sande E, Schrader H. Anterior perforations in lumbar discectomies. A report of four cases of vascular complications and a CT study of the prevertebral lumbar anatomy. *Spine (Phila Pa 1976)* 1991;16:54-60.
- 8) Ganesan C, Petrus L, Ross IB. Regarding the possibility of anterior vascular injury from the posterior approach to the lumbar disc space: an anatomical study. *Spine (Phila Pa 1976)* 2012;37:E1371-E1375.
- 9) van Zitteren M, Fan B, Lohle PN, de Nie JC, de Waal Malefijt J, Vriens PW, et al. A shift toward endovascular repair for vascular complications in lumbar disc surgery during the last decade. *Ann Vasc Surg* 2013;27:810-819.
- 10) Bolesta MJ. Vascular injury during lumbar discectomy associated with peridiskal fibrosis: case report and literature review. *J Spinal Disord* 1995;8:224-227.
- 11) Sağdıç K, Ozer ZG, Senkaya I, Türe M. Vascular injury during lumbar disc surgery. Report of two cases; a review of the literature. *Vasa* 1996;25:378-381.
- 12) Kwon TW, Sung KB, Cho YP, Kim DK, Ko GY, Yoon HK, et al. Large vessel injury following operation for a herniated lumbar disc. *Ann Vasc Surg* 2003;17:438-444.
- 13) Goodkin R, Laska LL. Vascular and visceral injuries associated with lumbar disc surgery: medicolegal implications. *Surg Neurol* 1998;49:358-370; discussion 372.
- 14) Skippage P, Raja J, McFarland R, Belli AM. Endovascular repair of iliac artery injury complicating lumbar disc surgery. *Eur Spine J* 2008;17 Suppl 2:S228-S231.
- 15) Inamasu J, Guiot BH. Vascular injury and complication in neurosurgical spine surgery. *Acta Neurochir (Wien)* 2006;148:375-387.