



# Surgical management of a recurrent hydatid cyst in the thoracic spine of a postpartum patient with paraplegia: a rare case report and literature review

Rund Sami Aleissa<sup>1,2,3</sup>, Mohamed Saad Asiri<sup>1,2,3</sup>, Ghalib Habeeb Nasraldeen<sup>1,2,3</sup>, Faisal M. Konbaz<sup>4</sup>, Suhail S. Alassiri<sup>2,3,5</sup>, Majed S. Abaalkhail<sup>2,3,5</sup>, Fahad H. Al Helal<sup>2,3,5</sup>, Sami I. Al Eissa<sup>2,3,5</sup>

<sup>1</sup>Ministry of the National Guard-Health Affairs, King Abdulaziz Medical City, Riyadh, Saudi Arabia; <sup>2</sup>King Abdullah International Medical Research Centre, Riyadh, Saudi Arabia; <sup>3</sup>King Saud bin Abdulaziz University for Health Sciences, Riyadh, Saudi Arabia; <sup>4</sup>King Faisal Specialised Hospital and Research Centre, Riyadh, Saudi Arabia; <sup>5</sup>Orthopedics Surgery Department, Ministry of the National Guard-Health Affairs, King Abdulaziz Medical City, Riyadh, Saudi Arabia

*Contributions:* (I) Conception and design: SI Al Eissa, FM Konbaz; (II) Administrative support: SS Alassiri; (III) Provision of study materials or patients: SS Alassiri; (IV) Collection and assembly of data: RS Aleissa, MS Asiri, GH Nasraldeen; (V) Data analysis and interpretation: MS Abaalkhail, FH Al Helal; (VI) Manuscript writing: All authors; (VII) Final approval of manuscript: All authors.

*Correspondence to:* Rund Sami Aleissa, Medical Student. Ministry of the National Guard-Health Affairs, King Abdulaziz Medical City, Riyadh, Saudi Arabia; King Abdullah International Medical Research Centre, Riyadh, Saudi Arabia; King Saud bin Abdulaziz University for Health Sciences, 11426 Ar Rimmayia, Riyadh, Saudi Arabia. Email: Rundaleissa@gmail.com.

**Background:** Hydatid disease is a health problem caused by *Echinococcus granulosus*. Spinal hydatidosis is relatively uncommon when compared to hydatid disease of visceral organs, such as the liver.

**Case Description:** This report details the case of a 26-year-old female who presented acutely with incomplete paraplegia following delivery via cesarean section. She was previously treated for visceral and thoracic spine hydatid cyst disease. On magnetic resonance imaging (MRI), a cystic lesion suggestive of hydatid cyst disease was identified as causing severe cord compression, mainly at T7, raising suspicions of recurrence. Emergency decompression of the thoracic spinal cord via costotransversectomy was performed, as well as the removal of a hydatid cyst and instrumentation from T3-T10. Histopathology findings were consistent with a parasitic infection, specifically *Echinococcus granulosus*. The patient was administered albendazole for treatment and subsequently had full neurological recovery at the final follow-up.

**Conclusions:** Diagnosis and treatment of spinal hydatid disease is challenging. Surgical excision of the cyst for neural decompression and pathological identification of the cyst is the initial treatment of choice, alongside albendazole chemotherapy. In this review, we have analyzed spine cases reported in the literature and present the surgical approach applied to our case, which was the first reported case of spine hydatid cyst disease following delivery and recurrence. Uneventful surgery, avoiding cyst rupture, and treatment with antiparasitic medication are the mainstays of spine hydatid cyst management and avoidance of recurrence.

**Keywords:** Hydatid cyst; postpartum cyst; thoracic spine cyst; paraplegia; case report

Submitted Jan 21, 2023. Accepted for publication Apr 25, 2023. Published online May 31, 2023.

doi: 10.21037/jss-23-11

View this article at: <https://dx.doi.org/10.21037/jss-23-11>

## Introduction

Hydatid cyst disease is a zoonotic infection caused by tapeworm parasites of the genus *Echinococcus*, and predominately by *Echinococcus granulosus* (1). *Echinococcus* parasitic infections are typically established after the ingestion of larvae (2). Hydatidosis is frequently associated with visceral involvement, with the liver and spleen involved in 80–90% of cases (3,4). In certain conditions, skeletal involvement is observed, and vertebral involvement is found in approximately half of such cases (3–5). Management of the disease is highly dependent on establishing an accurate diagnosis, which can be difficult to conclude, and on administering appropriate treatment. In the absence of this combination, recurrence rates are exceptionally high (6). Here, we present an article on a rare case of recurrent spinal hydatid disease that caused severe and progressive neurological deficit that was discovered immediately after delivery, in accordance with the CARE reporting checklist (available at <https://jss.amegroups.com/article/view/10.21037/jss-23-11/rc>).

## Case presentation

A 26-year-old female presented to the emergency department of our hospital with sudden paraplegia with bowel and urinary incontinence. She had delivered via cesarean section 3 days prior. The patient's medical history included a hydatid cyst in the viscera, specifically along the surface of the liver, around 5 years prior to the current incident along with thoracic spine involvement; at that

time, she presented with back pain and cough. The cyst was removed surgically through posterior laminectomy from T4 to T7, and the patient was treated with albendazole, an anthelmintic agent, for 1 year.

The patient was admitted and provided informed consent. She reported bilateral lower limb ascending numbness and weakness associated with an unsteady gait that required her to use a walking frame for mobilization for the last 6 months of her pregnancy.

Neurological examination showed an upgoing Babinski reflex, clonus, and hyperreflexia of the patellar tendon, bilaterally. Furthermore, the physical examination revealed that the lower limb sensory value was 0/2, with intact sensation above the umbilicus and completely absent sensation below it. The motor value was 1/5, apart from dorsiflexion, which was 2/5 bilaterally on the Muscle Power Assessment Medical Research Council (MRC) grade scale. Upper limb full neurological examinations returned normal results. A full infectious and oncological workup was conducted urgently. In terms of radiological examination, thoracic spine magnetic resonance imaging (MRI) (*Figure 1*) revealed a multiloculated septated and thin peripheral enhancing cystic lesion. Chest computerized tomography (CT) revealed a left paraspinal multilocular complex cystic lesion at the T6 and T7 vertebrae that extended into the spinal canal with significant spinal cord compression (*Figure 2*). Blood examination showed an elevated C-reactive protein (CRP) concentration of 54 mg/L, an erythrocyte sedimentation rate (ESR) of 101 mm/h, and a white cell count of  $12.5/\text{mm}^3$  with the imaging and laboratory results in mind, we made a diagnosis of spinal cord compression at the T6 and T7 levels due to hydatid cyst recurrence.

The patient underwent emergency decompression and instrumentation of the thoracic spinal cord via costotransversectomy. The same midline incision was utilized to remove the hydatid cyst, and excision of a posterior mediastinal hydatid cyst from the ascending thoracic aorta was performed. The thoracic spine was exposed from T3–T10. Costotransversectomy was performed at the T6, T7, and T8 levels to gain access to achieve ventral decompression of the spinal cord.

Instrumentation was performed from T3–T10, skipping T6, T7 bilaterally and the T8 right pedicle. Microscopic decompression was started at the level of T9 in a cranial direction. At the level of T7, access was provided by costotransversectomy into the anterior part of the spinal cord, and cyst material was identified on both sides of the

### Highlight box

#### Key findings

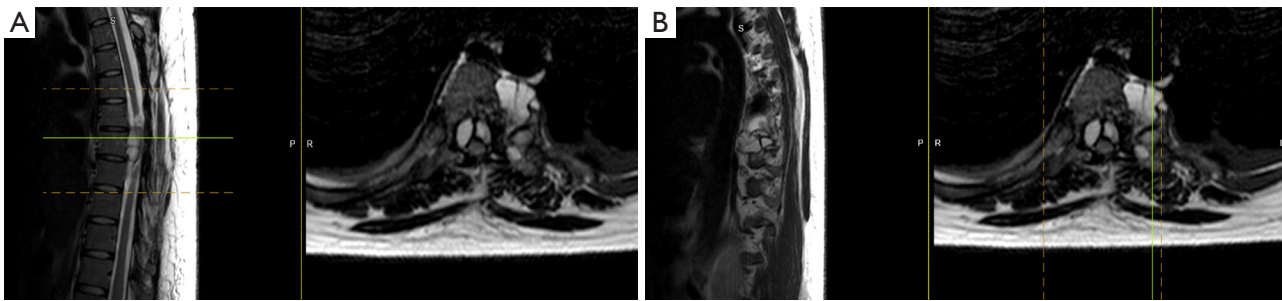
- A 26-year-old female who presented with paraplegia was diagnosed with a recurrent hydatid cyst post-delivery via cesarean section.

#### What is known and what is new?

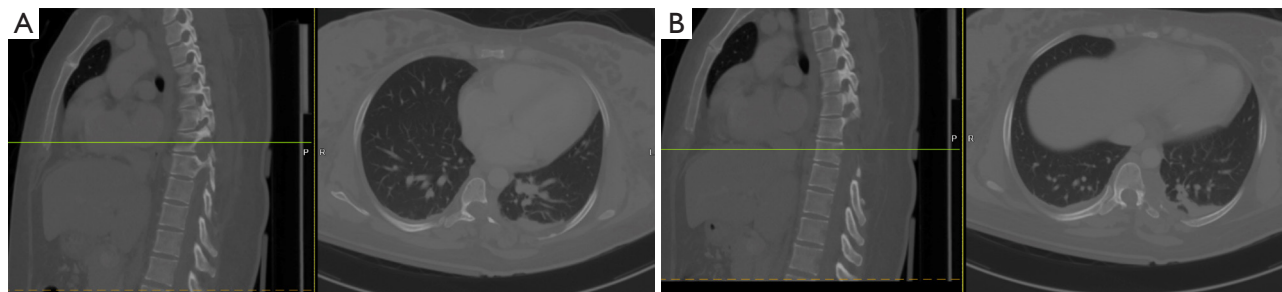
- Hydatid cyst is caused by *echinococcus granulosus* and is more likely to occur in the visceral organs.
- This is the first reported case in post-partum patients, especially after recurrence.

#### What is the implication, and what should change now?

- Extensive up-to-date literature summary on orthopedic spine-related cysts were analyzed.
- Surgeons should have a high degree of suspicion for known cases as recurrence is common and operating without knowledge might risk fatal anaphylaxis.



**Figure 1** T2-weighted midline sagittal (left) and axial (right) thoracic spine MRI (A) and T2-weighted left sagittal (left) with corresponding axial (right). Thoracic spine MRI of the level of T7 vertebral body (B). (A) Demonstrating a multiloculated septated and thin peripheral enhancing cystic lesion measuring approximately (4×2.7×2.6 centimeters) located at T7; extradural involvement of the posterior part of T7 vertebral body and bilateral pedicles causing spinal cord compression and high signal intensity that represents cord compression (myelomalacia) can be seen with bilateral neural foraminal and left paravertebral extension. Green line in (A) represents the exact location of the shown axial view in the sagittal plane. MRI, magnetic resonance imaging.

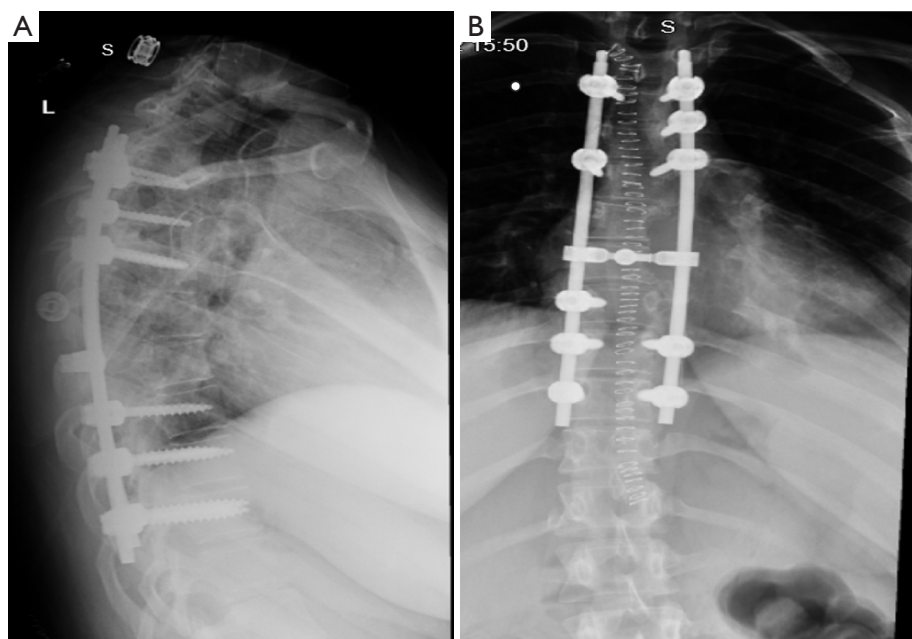


**Figure 2** Central sagittal (left) and axial (right) spine CT (A), and left sagittal spine (left) and axial spine (right) CT of the corresponding level of T6, T7 vertebral body (B). (A) Showcasing a left paraspinal multilocular complex cystic lesion at T6 and T7 vertebrae extending into the spinal canal with significant spinal cord compression; and there is concomitant bone erosion involving T6-T7 ribs with an expansion of T6-T7 left neural foramina, concerning a mediastinal cyst. The CT also revealed the previous laminectomy. CT, computerized tomography.

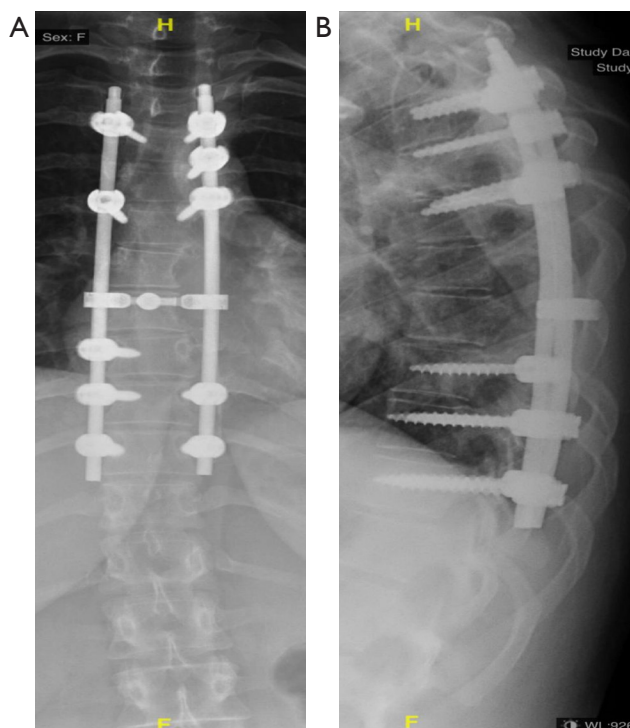
spinal cord. It was ensured that the whole cyst was removed. Rod-to-rod connectors were applied, and irrigation was performed with 14% hypertonic saline, an immediate postoperative X-ray of the spine is demonstrated in (Figure 3). The estimated blood loss was around 250 mL.

Histopathology of the thoracic decompression and biopsy revealed a fragmented cyst wall with laminated membranous structures and foci of calcifications surrounded by a foreign body giant cell reaction involving bone and adjacent soft tissue consistent with hydatid cyst. After consultation with an infectious disease team, the decision was made to administer anthelmintic treatment, specifically albendazole, postoperatively. On postoperative day 1, the patient had an improved sensation in the lower limbs. Examination of the bilateral lower limb muscles revealed the

following scores: ankle 3+/5, knee flexion 3+/5, hip flexion 3/5, hip adduction, abduction 2+/5, knee extension 4/5, and hip extension 3+/5. During her postoperative recovery, the patient started to show significant improvement in her neurological function. She was able to walk with minimal assistance and was discharged home after 4 weeks. After having a previous American Spinal Injury Association (ASIA) score of B, over the next few follow-ups 6 months after the surgery, the patient showed complete neurological recovery and had an ASIA score of E. Shown in (Figure 4) is her postoperative follow-up X-ray at 6 months. All procedures performed in this study were in accordance with the ethical standards of the institutional and/or national research committee(s) and with the Declaration of Helsinki (as revised in 2013). Written informed consent was obtained



**Figure 3** Postoperative lateral thoracic spine X-ray demonstrating final fixation from T3-T10 screws (A); and AP spine X-ray of the corresponding levels (B). L indicates the left side. S indicates that there was an external metal. AP, anteroposterior.



**Figure 4** AP thoracic spine X-ray image demonstrating the final fixation using T3-T10 screws at 6 months follow up (A), and lateral spine X-ray image showing the corresponding levels at 6 months follow up (B). AP, anteroposterior.

from the patient for the publication of this case report and accompanying images. A copy of the written consent is available for review by the editorial office of this journal.

## Discussion

The most affected organs in hydatid echinococcosis are the liver (70–75%), lungs (15–20%), and brain (2–4%) (7). Other less common sites of infection include the heart, kidneys, and spleen (8). Bone involvement is rare and found in 0.5–4% of cases, in which the spine is more frequently implicated (35–50%) than other structures (9,10). The pelvis is affected in 21% of hydatid bone disease cases, followed by the femur (16%) and tibia (10%) (9). In hydatid or cystic echinococcosis (CE) of the spine, the thoracic vertebrae are the most affected (50%), followed by the lumbar (20%), sacral (20%), and cervical (10%) vertebrae (11). Although spinal involvement is not as frequent as visceral involvement, portovertebral venous shunts serve as a route for spread. When there is spinal involvement, infection first appears in the center of the vertebrae, followed by multivesicular infiltration of cancellous bone that may include the vertebral bodies, pedicles, and lamina (5,6). Since cystic growth is confined to the periosteum, intervertebral disc involvement is

usually spared (12). Dew (13) and Braithwaite and Lees (14) classified spinal CE anatomically into five types: (I) intramedullary; (II) intradural extramedullary; (III) extradural intraspinal; (IV) vertebral; and (V) paravertebral. It can also be classified according to the route of spinal infection: (I) primary hematogenous; (II) secondary hematogenous; (III) secondary “per contiguitatem”; and (IV) secondary “per continuitatem” (10).

In our literature review, we found that the majority of reported spine cysts were thoracic, followed by lumbar, with only one case of sacral involvement (*Table 1*). Thoracic involvement could be explained by the proximity of the vasculature of the visceral organs that are most commonly infected with hydatid cysts, such as the liver. Our case had a recurrence from the liver to the spine, which provides further evidence for this theory.

It is also worth noting that our patient’s postpartum presentation is a unique aspect of this case. There are no reported cases in the literature of a progressive course following delivery, which our patient experienced. No doubt, the incredible physiological stress associated with pregnancy had a major role in the progressive nature of the cyst, as well as the surge of various hormones and signaling molecules.

In terms of patient recovery, our literature review findings show that the outcomes of the pooled cases were astoundingly positive, with near-full recovery in every case that mentioned the outcomes. There was no specific predilection to a gender or age range; the pooled cases ranged in age, and there was equal gender distribution. While definite pathognomonic signs of spinal hydatid disease do not exist, signs and symptoms that result from cystic lesions compressing neurological structures often present in adulthood as the disease is slow growing in nature. The most common of these are paraparesis (62%) or paraplegia (26%), radicular or back pain (55%), sensory loss or disturbances (36%), and sphincter disturbance (30%) (6).

Detection of hydatid disease is considered difficult; subsequently, adequate detailed history, clinical evaluation, and neuroimaging are essential (6). The imaging modalities of choice are CT scanning and MRI. T1-weighted images show hydatid cysts as hypointense, while T2-weighted images show them as hyperintense (18). Nevertheless, multiple smaller cysts in or around larger ones could go undetected when imaging is used (18). Cyst aspiration or biopsy is not advised as a diagnostic method, as these

procedures increase the risk of cyst dissemination or rupture, which may cause an anaphylactic reaction (7).

The most common initial treatment is surgical excision with the primary goal of neural decompression, complete removal, and pathological identification of cyst(s) (*Table 1*). Laminectomy with simple decompression is regularly used; however, it is also prone to many complications (18). Due to their relatively thin walls and relation to bony landmarks in the narrow spaces of the spine, total removal of cyst(s) without rupture is difficult (6,18). Cyst rupture is especially problematic because it can result in dissemination and anaphylaxis, as mentioned above. Several studies have shown that irrigation of the cyst using hypertonic saline may reduce the risk of cyst redevelopment (7,20). Although recurrence is still possible due to the presence of vital structures and limited access to cysts. According to one study, cysts recur in up to 44.4% of cases (6). Chemotherapy is another form of hydatid cyst treatment, with albendazole and mebendazole being the most commonly used anthelmintic drugs. They are often used concurrently with surgery to protect against the dissemination of a ruptured or punctured cyst, to decrease cyst volume preoperatively, and to prevent recurrence (7,10). The effectiveness of these drugs is widely debated; however, there have been reports of their success. el-Mufti *et al.* reported a 53% cure rate in a study of 40 patients with inoperable spinal cysts using albendazole treatment with a 2-year follow-up time (21).

Disease recurrence is a major handicap in the treatment of hydatid cysts. Despite aggressive surgical treatment and adjuvant chemotherapy, rates of spinal CE recurrence range from 30% to 100% (22). Recurrence is typically observed within the same organ or structure that was initially involved. However, our case presented with a thoracic spinal hydatid cyst years after albendazole treatment of a recurrent mediastinal hydatid cyst.

## Conclusions

Diagnosis of spinal hydatid disease is not straightforward and thus might cause a delay in treatment. Surgeons should work with utmost steadiness and precision to avoid rupturing cysts during biopsy and excision, as rupture could lead to a fatal anaphylactic reaction. Surgical excision, antiparasitic medications, and long-term follow-up are the mainstays for managing and avoiding the recurrence of spinal hydatid cysts.

**Table 1** Previous reports of spine hydatid cysts

Author(s) and year	Patient sex	Patient age (years)	Location in spine	Symptoms	Type of surgery	Medications	Outcome
Schnepper & Johnson, 2004 (6)	Female	34	Thoracic	Back pain, numbness, monoparesis	Surgical resection	Not mentioned	Complete recovery
Gouse <i>et al.</i> , 2013 (15)	Male	21	Lumbar	Low back pain with radicular pain to both legs	Surgical resection	Albendazole	Complete recovery, no recurrences
Somay <i>et al.</i> , 2014 (4)	Female	36	Thoracic with extensions to right thoracic wall and paravertebral musculature	Paraparesis, hypoesthesia below T10 level, increased deep tendon reflexes	Two-stage surgery: (I) right thoracotomy, T4 and T5 vertebrae removed, spinal decompression achieved; (II) multiple cysts in paraspinal musculature removed through posterior approach	Albendazole	Complete recovery, no recurrences
Ekşi <i>et al.</i> , 2014 (16)	Female	62	Thoracic	Back pain	Resection of the cystic mass	Albendazole	Complete recovery, no local or systemic recurrences
Abdelhakim <i>et al.</i> , 2014 (5)	Male	19	Sacrum	Cauda equina syndrome and pelvic pain	Surgical resection	Not mentioned	Not mentioned
Sharma <i>et al.</i> , 2020 (3)	Male	41	Lumbar	Back pain and weakness of the left foot	Surgical resection and decompression	Albendazole	Complete recovery, no recurrences
Alkan Çeviker <i>et al.</i> , 2022 (17)	Male	63	Thoracic	Loss of bilateral lower extremity strength, complete motor function loss in lower extremities, paraplegia and immobilization, urinary and fecal incontinence	Surgical resection	Albendazole	Not mentioned
Das <i>et al.</i> , 2021 (18)	Male	35	Thoracic	Back pain	Surgical resection through a posterior approach	Albendazole	Complete recovery, no recurrences
Zhang <i>et al.</i> , 2021 (19)	Female	57	Thoracic	Numbness and weakness in lower limbs, bladder dysfunction issues	Laminectomy	Albendazole	Complete recovery, no recurrences
Our case	Female	26	Thoracic	Bilateral lower limb ascending numbness and weakness, unsteady gait, post-partum	Costotransversectomy and decompression with instrumentation	Albendazole	Complete recovery, no recurrences

## Acknowledgments

*Funding:* None.

## Footnote

*Reporting Checklist:* The authors have completed the CARE reporting checklist. Available at <https://jss.amegroups.com/article/view/10.21037/jss-23-11/rc>

*Peer Review File:* Available at <https://jss.amegroups.com/article/view/10.21037/jss-23-11/prf>

*Conflicts of Interest:* All authors have completed the ICMJE uniform disclosure form (available at <https://jss.amegroups.com/article/view/10.21037/jss-23-11/coif>). The authors have no conflicts of interest to declare.

*Ethical Statement:* The authors are accountable for all aspects of the work in ensuring that questions related to the accuracy or integrity of any part of the work are appropriately investigated and resolved. All procedures performed in this study were in accordance with the ethical standards of the institutional and/or national research committee(s) and with the Declaration of Helsinki (as revised in 2013). Written informed consent was obtained from the patient for the publication of this case report and accompanying images. A copy of the written consent is available for review by the editorial office of this journal.

*Open Access Statement:* This is an Open Access article distributed in accordance with the Creative Commons Attribution-NonCommercial-NoDerivs 4.0 International License (CC BY-NC-ND 4.0), which permits the non-commercial replication and distribution of the article with the strict proviso that no changes or edits are made and the original work is properly cited (including links to both the formal publication through the relevant DOI and the license). See: <https://creativecommons.org/licenses/by-nc-nd/4.0/>.

## References

- Charles RW, Govender S, Naidoo KS. Echinococcal infection of the spine with neural involvement. *Spine (Phila Pa 1976)* 1988;13:47-9.
- Thompson RCA, McManus DP. Aetiology: parasites and life-cycles. In: Eckert J, Gemmell MA, Meslin FX, et al. editors. WHO/OIE Manual on Echinococcosis in Humans and Animals: A Public Health Problem of Global Concern. Paris: World Organization for Animal Health, 2001:1-19.
- Sharma JK, Tandon V, Marathe NA, et al. Hydatid Cyst of the Spine: A Rare Case Report and Review of Literature. *J Orthop Case Rep* 2020;10:57-9.
- Somay H, Ayan E, Turk CC, et al. Long-term disseminated recurrence in spinal hydatid cyst: a case report. *Turk Neurosurg* 2014;24:78-81.
- Abdelhakim K, Khalil A, Haroune B, et al. A case of sacral hydatid cyst. *Int J Surg Case Rep* 2014;5:434-6.
- Schnepper GD, Johnson WD. Recurrent spinal hydatidosis in North America. Case report and review of the literature. *Neurosurg Focus* 2004;17:E8.
- Sioutis S, Reppas L, Bekos A, et al. Echinococcosis of the spine. *EFORT Open Rev* 2021;6:288-96.
- Kouskos E, Chatziantoniou J, Chrissafis I, et al. Uncommon locations of hydatid cysts. *Singapore Med J* 2007;48:e119-21.
- Papanikolaou A. Osseous hydatid disease. *Trans R Soc Trop Med Hyg* 2008;102:233-8.
- Neumayr A, Tamarozzi F, Goblirsch S, et al. Spinal cystic echinococcosis—a systematic analysis and review of the literature: part 1. Epidemiology and anatomy. *PLoS Negl Trop Dis* 2013;7:e2450.
- Polat P, Kantarci M, Alper F, et al. Hydatid disease from head to toe. *Radiographics* 2003;23:475-94; quiz 536-7.
- Senoglu M, Bulbuloglu E, Demirpolat G, et al. Combined anterior and posterior approach for sacral/retroperitoneal hydatid cyst disease: case report. *Turk Neurosurg* 2009;19:428-32.
- Dew HR. Hydatid Disease. Its Pathology, Diagnosis and Treatment. Sydney: The Australasian Medical Publishing Company, Limited., 1928.
- Braithwaite PA, Lees RF. Vertebral hydatid disease: radiological assessment. *Radiology* 1981;140:763-6.
- Gouse M, Amritanand R, Venkatesh K, et al. Recurrent Echinococcal Infection of the Lumbar Spine: An 11 Year Follow-up. *Asian Spine J* 2013;7:39-43.
- Ekşi MŞ, Bayri Y, Saraçoğlu A, et al. Primary subcutaneous hydatid cyst over thoracic spine: a case report and review of the literature. *Türkiye Parazitol Derg* 2014;38:264-9.
- Alkan Çeviker S, Yüksel C, Şener A, et al. Hydatid Cyst of the Spine: A Rare Case Report. *Türkiye Parazitol Derg* 2022;46:78-81.
- Das G, Nanda SN, Sahu NK, et al. Hydatid Cyst of Dorsal Spine Masquerading as Tubercular Infection: A Case Report and Review of Literature. *Asian J Neurosurg*

- 2021;16:886-9.
19. Zhang B, Zhang L, Zhou H, et al. Progressive compressive myelopathy induced by a rare primary isolated thoracic vertebral hydatid cyst: A case report. *Medicine (Baltimore)* 2021;100:e25177.
  20. Gezercan Y, Ökten AI, Çavuş G, et al. Spinal Hydatid Cyst Disease. *World Neurosurg* 2017;108:407-17.
  21. el-Mufti M, Kamag A, Ibrahim H, et al. Albendazole therapy of hydatid disease: 2-year follow-up of 40 cases. *Ann Trop Med Parasitol* 1993;87:241-6.
  22. Neumayr A, Tamarozzi F, Goblirsch S, et al. Spinal cystic echinococcosis--a systematic analysis and review of the literature: part 2. Treatment, follow-up and outcome. *PLoS Negl Trop Dis* 2013;7:e2458.

**Cite this article as:** Aleissa RS, Asiri MS, Nasraldeen GH, Konbaz FM, Alassiri SS, Abaalkhail MS, Al Helal FH, Al Eissa SI. Surgical management of a recurrent hydatid cyst in the thoracic spine of a postpartum patient with paraplegia: a rare case report and literature review. *J Spine Surg* 2023;9(2):216-223. doi: 10.21037/jss-23-11