

Spontaneous fracture of an implanted posterior chamber polyimide intraocular lens haptic: A case report

Haemin Kang¹, Kyung Eun Han^{1,2}, Tae-im Kim^{1,2},
Eung Kweon Kim^{1,2,3,4}

A 57-year-old male patient visited our clinic for decreased visual acuity in the right eye for 10 days. He denied any trauma history, but recalled that the symptom developed after straining. He had undergone uncomplicated phacoemulsification and posterior chamber intraocular lens (IOL) implantation in the bag of the right eye 11 years ago. The IOL was a three-piece silicone polyimide-haptics design. On slit-lamp examination, the IOL optic and proximal part of nasal fractured haptic were found in the anterior chamber. The distal part of fractured haptic was

observed in the capsular bag. He underwent IOL exchange. The fracture site of the haptic was near the optic-haptic junction. This is the unique case report of a spontaneous fracture of an implanted posterior chamber polyimide IOL haptic, which implies the possibility of IOL haptic fracture in various haptic materials.

Key words: Haptic fracture, posterior chamber intraocular lens fracture, spontaneous fracture

Fracture of an intraocular lens (IOL) after implantation is a relatively rare complication after cataract surgery. However, there have been reports of traumatic and spontaneous fracture of anterior and posterior chamber IOLs.^[1-6] Such fracture may result in corneal decompensation if broken lens contacts the corneal endothelium.^[6]

All previously reported cases of posterior chamber IOLs involved lenses made of polymethyl methacrylate (PMMA).^[4-6] Herein, we report a case of spontaneous fracture of posterior chamber polyimide IOL haptic.

Case Report

A 57-year-old male patient presented to our clinic with a history of blurred vision in the right eye for 10 days. He had no recent systemic disease or ocular trauma history, but he remembered that blurred vision developed just after straining to lift a heavy object. His medical record showed that he underwent uneventful phacoemulsification with capsular bag implantation of a posterior chamber IOL in the right eye under local anesthesia 11 years ago in our institute. The IOL (model AQ2003V, STAAR[®] Surgical Co., Monrovia, CA, USA) was a three-piece biconvex lens with a 6.3-mm optic and polyimide haptics, and the overall diameter was 12.5 mm. The haptics had a C-shaped configuration and a flat angulation. Postoperatively, the uncorrected visual acuity (UCVA) was 20/20.

Access this article online	
Quick Response Code:	Website: www.ijo.in
	DOI: 10.4103/0301-4738.111195

¹Department of Ophthalmology, ²Corneal Dystrophy Research Institute, ³Severance Biomedical Science Institute, ⁴Brain Korea 21 Project for Medical Science, Yonsei University College of Medicine, Seoul, Korea

Correspondence to: Dr. Eung Kweon Kim, Department of Ophthalmology, Yonsei University College of Medicine, 134, Shinchon-dong, Seodaemun-ku 120-752, Seoul, Korea. E-mail: eungkkim@yuhs.ac

Manuscript received: 02.11.10; Revision accepted: 22.08.11

At presentation, the visual acuity of right eye was 20/60, and the intraocular pressure (IOP) was 11 mmHg by noncontact tonometer. Best corrected visual acuity (BCVA) was 20/20 (-2.25 Dsph = -1.00 Dcyl Ax 90). On slit-lamp examination, the pupil was distorted, and the IOL optic and a proximal part of a nasal fractured haptic were found in the anterior chamber, with cells 3+. After dilation, both ends of the fractured IOL haptic fragment were found to be aligned close to each other at the margin of the capsulotomy, with most of the haptic loop located in the bag [Fig. 1]. Severe capsular fibrosis was also noted. Fundus examination revealed no specific abnormality. The corneal endothelial count was 2075/mm² by specular microscope.

To prevent further complication, an operation was performed. Under retrobulbar anesthesia, the dislocated IOL including attached haptic fragment was removed. During operation, the fractured distal haptic fragment was noted and left in the bag. Then, a three-piece IOL (ZA9003, Tecnis®, Abbott Medical Optics, Santa Ana, IL, USA) was fixed in the ciliary sulcus. The extracted IOL was checked grossly, and the fracture site of the haptic was near the optic-haptic junction [Fig. 2].

On postoperative day 1, the UCVA was 20/25 and IOP was 10 mmHg. The IOL was fixed in the sulcus and postoperatively there were no further complications. At the most recent presentation, which was 3 weeks after operation, the UCVA was 20/25 and the IOL was well positioned.

Discussion

Shammas and Milkei reported traumatic fracture of a rigid Choyce-style anterior chamber IOL.^[1] Subsequently, there have been several case reports of posterior chamber IOL fractures, mostly occurring in PMMA IOLs. PMMA can crack or even break when stressed beyond certain limits. Single-piece all-PMMA IOLs can withstand the level of stress necessary for implantation, but excessive pressure on the haptic can lead to fracture, usually at the optic-haptic junction which is the weakest point of the IOL.

Our case is unique in that spontaneous fracture of IOL occurred in a three-piece silicone polyimide-haptics

design. This polyimide is known for thermal stability, good chemical resistance, excellent mechanical properties, and characteristic orange/yellow color. Therefore, this type of IOL has advantages of greater flexibility and excellent resistance to heat and biodegradation than other IOLs with polypropylene and PMMA haptics. Despite these advantages, they can be problematic during operation. A clinicopathological analysis of 100 intraoperatively explanted IOLs reported that the three-piece silicone polyimide-haptics design is the second most commonly explanted IOL during initial cataract surgery. The primary reasons for intraoperative explantation were optic and haptic damages during IOL implantation.^[7]

Implantation of most foldable IOLs generally requires more steps during loading, folding, unfolding, and delivering into the capsular bag than rigid IOLs. These additional steps may result in damage to foldable IOL designs. However, once implanted successfully, posterior chamber IOLs are better protected in the capsular bag than anterior chamber IOLs which are subjected to external forces. However, posterior chamber IOLs are subject to the compressing forces of the contracting fibrosed capsular bag. These forces may cause deformation of a haptic and subsequent decentration of the IOL as proved in Rhesus monkeys.^[8]

Although we could not determine the exact mechanism of the IOL haptic fracture in this patient, the fracture may be attributed to several factors. We hypothesized that the IOL might have been weakened with time and deformed by the compressing forces of the contracting fibrosed capsular bag. When lifting a heavy object, the transient energy and a subsequent change in the IOP might have forced the IOL optic and haptic anteriorly through the pupil, resulting in fracture of the IOL haptic. The obliquely fractured surface of the distal haptic shown in Fig. 1b suggests the possibility of applied force on the fractured haptic site. The previous unnoticed damage on the haptic near the optic junction, however, might be made during folding, loading, or implantation of IOL at the time of initial surgery, which can be a cause of delayed haptic fracture.

This case is the unique report of spontaneous fracture of a three-piece silicone polyimide-haptics IOL. Although this type

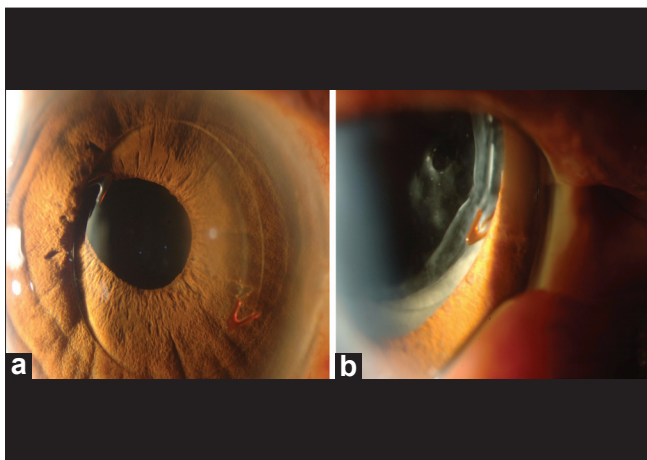


Figure 1: Slit-lamp examination of the right eye. (a) Intraocular lens was dislocated to the anterior chamber with a broken haptic. (b) After dilation. Capsular fibrosis was noted with the fractured haptic




Figure 2: (a) Fractured intraocular lens after explantation. (b) Magnifying view at the optic-haptic junction

of IOL is known to be more prone to damage during folding, loading, and implantation than other foldable IOLs, there has been no report of spontaneous fracture.

In conclusion, although relatively rare, spontaneous fracture of IOL can occur after cataract surgery, even after 11 years like in this case. Also, as three-piece silicone polyimide-haptics IOLs are known to have more flexible haptics than the PMMA design, spontaneous fracture occurred in our patient. IOLs have evolved, but multiple mechanisms other than the lens material affect the IOL and may lead to subsequent IOL fracture, especially at the optic-haptic junction. Therefore, ophthalmologists should be aware of this fact, and further investigation is needed to prevent IOL fracture.

References

1. Shamma HJ, Milkie CF. Traumatic fracture of a Choyce-style anterior chamber lens. *J Am Intraocul Implant Soc* 1981;7:46-8.
2. Capoferri C, Vacchi S, Tafi A, Voglini IM. Traumatic fracture of flexible anterior chamber intraocular lenses. *J Cataract Refract Surg* 1997;23:1418-20.
3. Park SB, Kratz RP, Olson PF, Pfeffer BR, Apple DJ. *In vivo* fracture of an extruded polymethylmethacrylate intraocular lens loop. *J Cataract Refract Surg* 1987;13:194-7.
4. Das S, Patil MD, Garg P. Traumatic fracture of posterior chamber intraocular lens. *J Cataract Refract Surg* 2007;33:2151-2.
5. Çaça I, Unlü K, Ari S, Akşit I. Spontaneous fracture of an implanted posterior chamber intraocular lens. *Eur J Ophthalmol* 2005;14:507-9.
6. Eleftheriadis H, Sahu DN, Willekens B, Vrensen GF, Liu CS. Corneal decompression and graft failure secondary to a broken posterior chamber poly (methyl methacrylate) intraocular lens haptic. *J Cataract Refract Surg* 2001;27:2047-50.
7. Schmidbauer JM, Peng Q, Apple DJ, Pandey SK, Escobar-Gomez M, Auffarth GU, *et al.* Rates and causes of intraoperative removal of foldable and rigid intraocular lenses. Clinicopathological analysis of 100 cases. *J Cataract Refract Surg* 2002;28:1223-8.
8. Lambert SR, Fernandes A, Grossniklaus HE. Haptic breakage following neonatal IOL implantation in a non-human primate model. *J Pediatr Ophthalmol Strabismus* 1995;32:219-24.

Cite this article as: Kang H, Han KE, Kim T, Kim EK. Spontaneous fracture of an implanted posterior chamber polyimide intraocular lens haptic: A case report. *Indian J Ophthalmol* 2014;62:348-50.

Source of Support: Nil. **Conflict of Interest:** None declared.