



CASE SERIES

# Trifarotene 0.005% Cream in the Treatment of Facial and Truncal Acne Vulgaris in Patients with Skin of Color: a Case Series

James Q. Del Rosso · Edward Lain · Jean Philippe York · Andrew Alexis

Received: June 21, 2022 / Accepted: July 29, 2022 / Published online: August 22, 2022  
© The Author(s) 2022

## ABSTRACT

The clinical appearance of acne vulgaris (AV) and the response to therapeutic agents may vary in people with skin of color (SoC) compared with those with lighter skin types. Given the heightened potential for postinflammatory hyperpigmentation and keloid development, effective and timely AV treatment in patients with SoC is especially important. However, these patients are frequently underrepresented in clinical trials, and SoC photographs are generally underrepresented in dermatology. Trifarotene 0.005% cream is a retinoid approved for the once-daily topical treatment of AV, and

was studied in large-scale clinical trials that assessed the treatment of AV on both the face and trunk. For severe AV, a topical retinoid may be used in combination with an oral antibiotic, such as doxycycline. Five subjects covering Fitzpatrick skin phototypes III, IV, V, and VI were selected from two larger studies to visually demonstrate treatment of clinically diagnosed AV with trifarotene 0.005% cream. Two subjects received 24 weeks of treatment with trifarotene 0.005% cream for moderate AV on the face and trunk, while three subjects received 12 weeks of treatment with trifarotene 0.005% cream in association with 120 mg oral doxycycline with modified polymer coating for severe facial AV. This case series supports the favorable efficacy and safety of facial and truncal AV treatment with trifarotene 0.005% cream, with or without oral doxycycline, in subjects with SoC (phototypes III–VI).

J. Q. Del Rosso (✉)  
JDR Dermatology Research/Thomas Dermatology,  
Las Vegas, NV, USA  
e-mail: jqdelrosso@yahoo.com

J. Q. Del Rosso  
Advanced Dermatology and Cosmetic Surgery,  
Maitland, FL, USA

E. Lain  
Austin Institute for Clinical Research, Pflugerville,  
TX, USA  
e-mail: ted.lain@gmail.com

J. P. York  
Galderma Laboratories, L.P., Fort Worth, TX, USA  
e-mail: jp.york@galderma.com

A. Alexis  
Weill Cornell Medical College, New York, NY, USA  
e-mail: alexisderm@yahoo.com

**Keywords:** Acne; Case series; Doxycycline; Facial; Retinoid; Skin of color; Trifarotene; Truncal

## Key Summary Points

### *Why carry out this study?*

Subjects with skin of color (SoC) are frequently underrepresented in clinical trials, and SoC photographs are generally underrepresented in dermatology.

This case series illustrates five subjects covering Fitzpatrick skin phototypes III, IV, V, and VI treated with trifarotene 0.005% cream in combination with 120 mg oral doxycycline with modified polymer coating for severe facial acne vulgaris (AV) for 12 weeks or with trifarotene 0.005% cream used as monotherapy for moderate facial and truncal AV for 24 weeks.

### *What was learned from the study?*

Trifarotene 0.005% cream, with or without oral doxycycline, demonstrates favorable efficacy and safety for treating moderate or severe AV in subjects with skin phototypes III–VI.

## INTRODUCTION

Acne vulgaris (AV) is a common skin disease among people of all skin types and racial/ethnic groups. The visible appearance of AV and the patterns of clinical response to therapeutic agents may vary in people with skin of color (SoC) compared with those with lighter skin types [1]. However, photographs of patients with SoC are generally underrepresented in dermatology literature [2].

Furthermore, effective and timely AV treatment in patients with SoC is important owing to a heightened potential for sequelae, such as postinflammatory hyperpigmentation (PIH) and keloid development [3–5]. Topical retinoids may improve the appearance of pigmented lesions in patients with SoC [5]. Understanding these nuances in clinical presentation, safety

considerations, cultural factors, and implications for treatment and skin care recommendations is important to ensure successful AV management in patients with SoC [6, 7].

Topical retinoids, alone or combined with other agents, are recommended as a vital component of the initial treatment in most patients with AV as they reduce both comedonal and inflammatory AV lesions, and assist in sustaining AV clearance by inhibiting the emergence of new AV lesions [8, 9]. Trifarotene 0.005% cream is a topical retinoid with high selectivity in targeting retinoic acid receptor gamma (RAR- $\gamma$ ), the most common RAR found in the skin [10]. Clinical data from three large clinical trials have demonstrated good efficacy and long-term safety of trifarotene 0.005% cream monotherapy, which has been approved for the once-daily topical treatment of facial and truncal AV [11, 12]. For facial or truncal disease where the clinician determines that topical monotherapy may not be adequate, a topical retinoid may be used in combination with other therapies, including an oral antibiotic [13, 14].

The objective of this case series of five representative subjects selected from larger clinical studies to include skin phototypes III, IV, V, and VI was to visually demonstrate AV treatment with trifarotene 0.005% cream on the face and trunk, including cases of severe AV used in combination with oral doxycycline, in subjects with dark skin phototypes. The formulation of doxycycline used was 120 mg oral doxycycline with modified polymer coating (MPC).

## METHODS

### Subjects

For this case series of AV subjects with skin phototypes III, IV, V, and VI, five representative subjects were selected from two larger studies. These studies each enrolled proportional numbers of SoC subjects relative to the racial population of the USA.

1. Study 1 was a phase 4, multicenter, randomized-controlled study evaluating the safety and efficacy of topical trifarotene

0.005% cream associated with 120 mg oral doxycycline MPC, once daily for 12 weeks, for the treatment of severe facial AV [Investigator Global Assessment (IGA) 4,  $\geq$  20 inflammatory lesions, 30–120 noninflammatory lesions]. A wash-out period was applied for topical treatments and for any previous retinoid treatments (at least 2 weeks); systemic corticosteroids, antibiotics, and spironolactone (at least 4 weeks); and oral retinoids/isotretinoin (12 weeks) before starting the study. Of 133 subjects randomized to the treatment group, 19 (14%) had SoC (9 Black/African American, 6 Asian, 1 Pacific Islander, 3 multiple). ClinicalTrials.gov Identifier: NCT04451330.

2. Study 2 was a phase 3b, multicenter, open-label, single-arm study to evaluate treatment of moderate facial and truncal AV [baseline IGA 3,  $\geq$  20 inflammatory lesions and  $\geq$  25 noninflammatory lesions on the face, in addition to  $\geq$  20–100 inflammatory lesions and  $\geq$  20 noninflammatory lesions on the trunk (shoulders, upper back, and upper anterior chest)] with trifarotene 0.005% cream applied once daily in the evening for 24 weeks. Any previous AV treatments within the previous 6 months were recorded, and a washout period of at least 2 weeks was applied for topical treatments (4 weeks for any previous retinoid treatments), on the face and trunk, before starting the study. Each subject was given both oral and written instructions on the proper dosing and how to apply a thin layer of trifarotene 0.005% cream on the facial region (one pump actuation) and the trunk (two actuations), as per the Summary of Product Characteristics [15]. Of 47 subjects included, 5 (11%) were Black/African American and 42 were categorized as white (including 10 Hispanic or Latino with skin phototypes ranging from II to V). ClinicalTrials.gov Identifier: NCT03915860.

In both studies, to reduce any irritation and to enhance compliance with the study treatment, subjects were encouraged to use the provided gentle cleanser and moisturizer lotion. Additionally, the physician could institute an

alternate-day application regimen for a maximum of 2 weeks during the first 4 weeks. In study 1, an oil-absorbing moisturizer with sun protection factor (SPF) 30 was also provided for daily use, although in both studies, subjects could use their preferred brand of noncomedogenic sunscreen with SPF  $\geq$  30. No products were to be applied to the face or trunk for 1 h before and after the study drug.

### Assessments

At baseline and weeks 1, 2, 4, 8, 12, and 24 (when applicable):

1. Investigator Global Assessment (IGA) score for facial AV for both studies, as well as Physician Global Assessment (PGA) for truncal AV in study 2, on a scale from 0 (clear) to 4 (severe).
2. Inflammatory and noninflammatory lesion counts.
3. Local tolerability parameters (dryness, erythema, stinging/burning, scaling) were assessed on a 5-point scale [from 0 (none) to 4 (severe)], and adverse events were recorded throughout the treatment period.

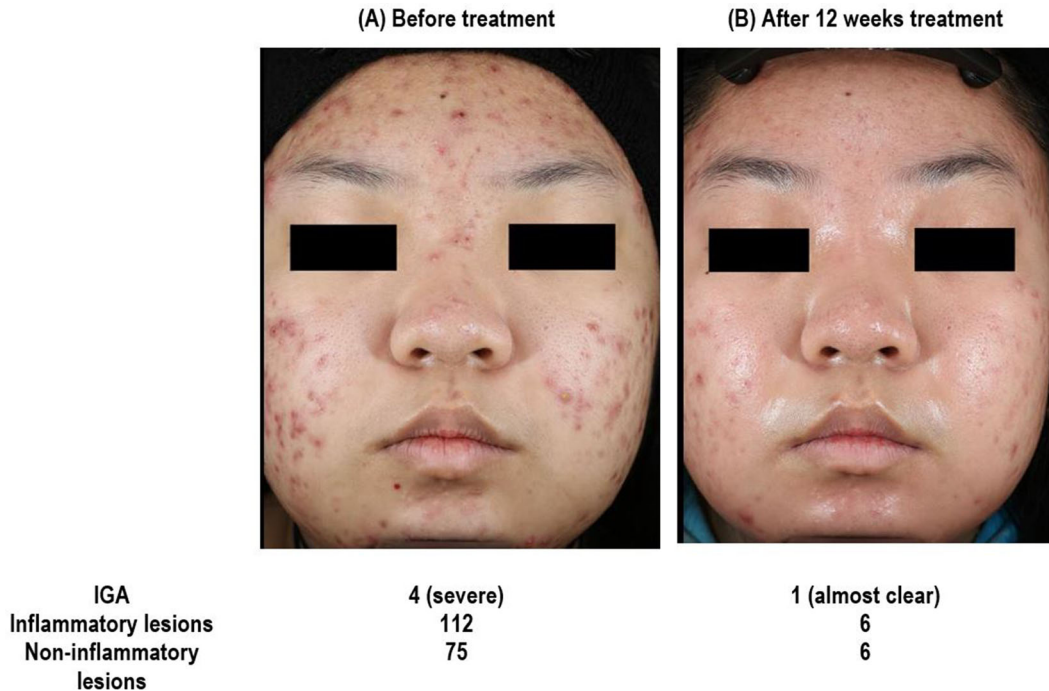
### Compliance with Ethics Guidelines

All subjects, or their parent or guardian, provided written informed consent before participating in the study and for publication of their clinical details and photographs. All data were deidentified. Both studies were performed in accordance with the Helsinki Declaration of 1964, and its later amendments. Ethics committee and/or institutional review board (IRB) approval were obtained prior to study 1 (Copernicus Group IRB) and study 2 (IntegReview meeting held on 18 February 2019).

## RESULTS

### Case Study 1

In study 1, a 15-year-old Asian female subject from the USA with Fitzpatrick skin phototype III



**Fig. 1** Case 1: photographs of a 15-year-old Asian female subject before (A) and after 12 weeks (B) of treatment with trifarotene 0.005% cream and 120 mg oral

doxycycline with modified polymer coating for facial acne vulgaris. IGA Investigator Global Assessment

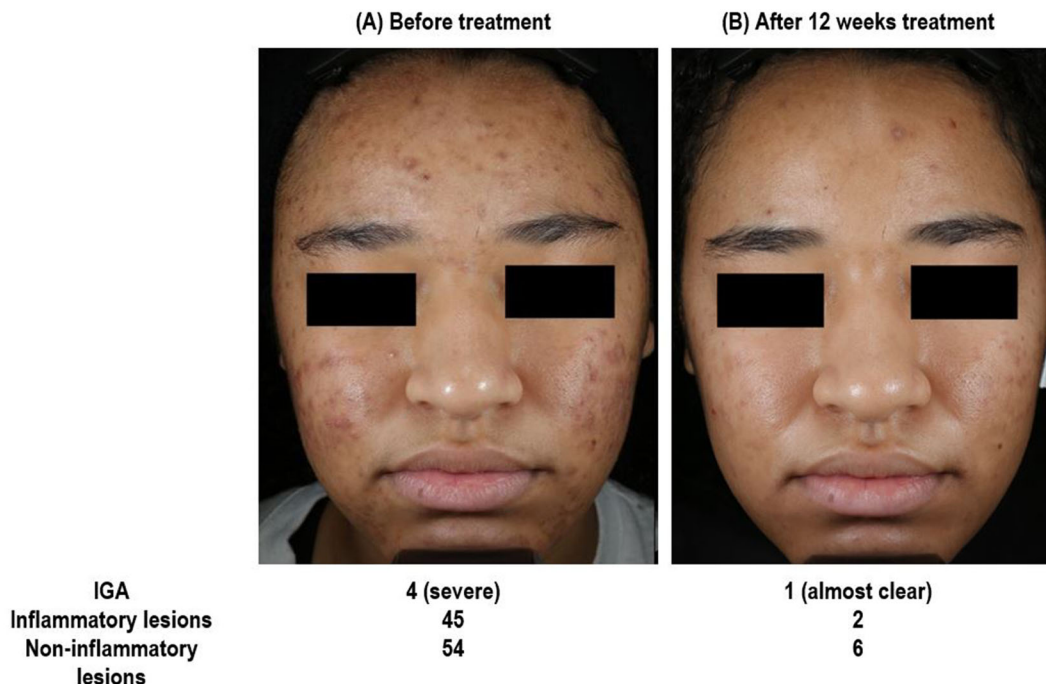
had a history of AV for 4.8 years. She was clinically diagnosed with severe (IGA 4) facial AV at baseline, and this decreased to almost clear (IGA 1) after 12 weeks of treatment with trifarotene 0.005% cream and 120 mg oral doxycycline MPC (Fig. 1). She had significant reductions in lesion counts from 112 inflammatory and 75 noninflammatory lesions on the face at baseline to 6 inflammatory and 6 noninflammatory lesions after 12 weeks.

She completed the 12 weeks of treatment with only minor deviations of missed doses. Overall treatment compliance for topical trifarotene 0.005% cream was 85% (100% in weeks 1, 2, and 4, 82% in week 8, and 71% in week 12), and overall compliance for 120 mg oral doxycycline MPC was 98% (100%, 86%, 100%, 100%, and 96% for weeks 1, 2, 4, 8, and 12, respectively). The only local tolerability parameter that was moderate was erythema at week 4, and she experienced no cutaneous treatment-emergent adverse events.

## Case Study 2

In study 1, an 18-year-old Black/African American female subject from the USA with Fitzpatrick skin phototype V had a history of AV for 9.7 years. She had severe facial AV (IGA 4) at baseline, and this decreased to almost clear (IGA 1) after 12 weeks of treatment with trifarotene 0.005% cream and 120 mg oral doxycycline MPC (Fig. 2). A decrease in lesion counts on the face was observed from 45 inflammatory and 54 noninflammatory lesions at baseline to 2 inflammatory and 6 noninflammatory lesions after 12 weeks.

She had 100% overall compliance for both treatments, and the only local tolerability reactions she had over the 12 weeks of treatment were mild scaling at week 1 and moderate erythema at week 2, which had disappeared by the week 4 visit. She experienced no cutaneous treatment-emergent adverse events.



**Fig. 2** Case 2: photographs of a 18-year-old Black/African American female subject with Fitzpatrick skin type V before (A) and after 12 weeks (B) of treatment with

trifarotene 0.005% cream and 120 mg oral doxycycline with modified polymer coating for facial acne vulgaris. IGA Investigator Global Assessment

### Case Study 3

In study 1, a 19-year-old Black/African American male subject from the USA with Fitzpatrick skin phototype V had a medical history of AV for 4.9 years and concomitant seasonal allergic rhinitis for 2.9 years. Prior medication included topical sulfur treatment for AV and antiseptics and disinfectants, started 10 weeks before the study began and stopped 15 days prior to study start.

His IGA score decreased from severe (IGA 4) at baseline to mild (IGA 2) at week 12 after treatment on the face with trifarotene 0.005% cream and 120 mg oral doxycycline MPC. Lesion counts decreased from 43 inflammatory and 34 noninflammatory lesions at baseline to 12 inflammatory and 17 noninflammatory lesions at week 12 (Fig. 3).

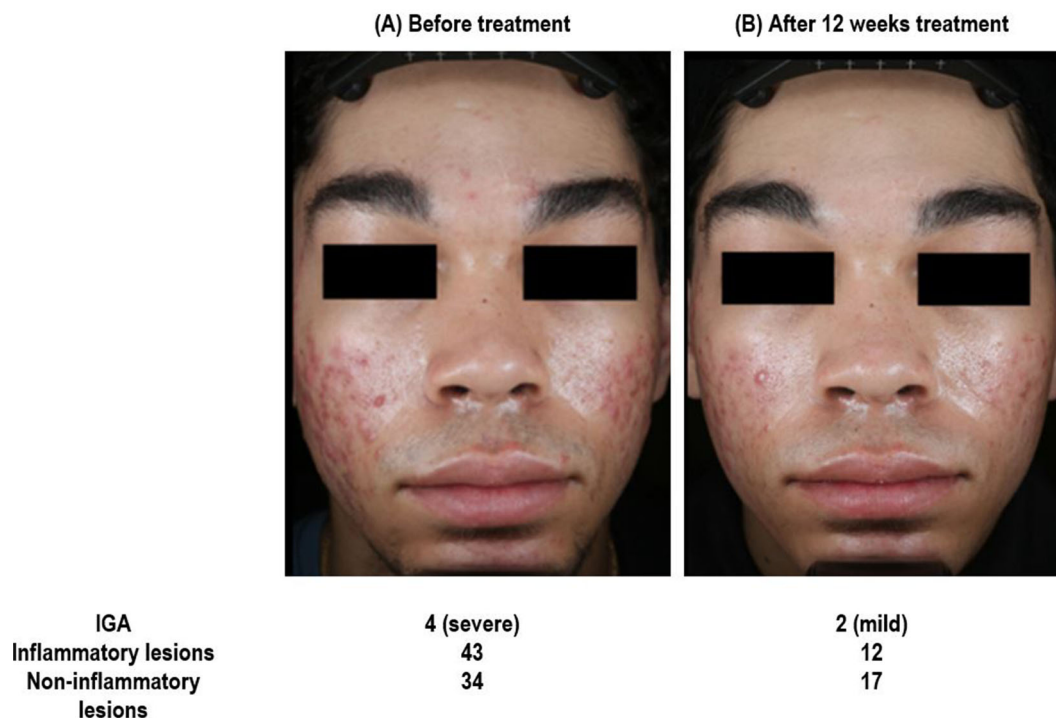
He had one minor protocol deviation of a missed dose of 120 mg oral doxycycline MPC at week 8 with overall compliance of 99% for 120 mg oral doxycycline MPC (96% compliance at week 8 and 100% for weeks 1, 2, 4, and 12).

Overall compliance was 100% for trifarotene 0.005% cream. This subject did use the provided gentle skin cleanser and the SPF 30 sunscreen but did not apply the dispensed moisturizing lotion. No cutaneous treatment-emergent adverse events or any local tolerability reactions were observed throughout the study.

### Case Study 4

In study 2, a 16-year-old Black/African American male subject from the USA with Fitzpatrick skin phototype VI had a medical history of AV for 3.4 years and was taking concomitant medications for asthma (selective  $\beta$ -2 adrenoreceptor agonists) and using skin care (emollients).

He was diagnosed with moderate facial and truncal AV at baseline. After 24 weeks of treatment with trifarotene 0.005% cream, significant reductions were observed in IGA score on the face and PGA score for truncal AV and both inflammatory and noninflammatory lesions significantly decreased on the face and trunk (Fig. 4).



**Fig. 3** Case 3: photographs of a 19-year-old Black/African American male subject with Fitzpatrick skin type V before (A) and after 12 weeks (B) of treatment with trifarotene

0.005% cream and 120 mg oral doxycycline with modified polymer coating for facial acne vulgaris. IGA Investigator Global Assessment

Overall compliance was 100% for both face and trunk. He had moderate erythema between baseline and week 4 (face and trunk), moderate scaling between baseline and week 1 on trunk, and moderate stinging/burning at week 1 (face and trunk) and week 4 (face only). He experienced no cutaneous treatment-emergent adverse events.

### Case Study 5

In study 2, a 12-year-old Black/African American female subject from the USA with Fitzpatrick skin phototype IV had a medical history of AV for 2.5 years and was taking concomitant medications for allergies (oral antihistamines). She had moderate facial and truncal AV at baseline, while after 24 weeks of treatment with trifarotene 0.005% cream, significant reductions were observed in IGA score on the face and PGA score for truncal AV and both inflammatory and noninflammatory lesions

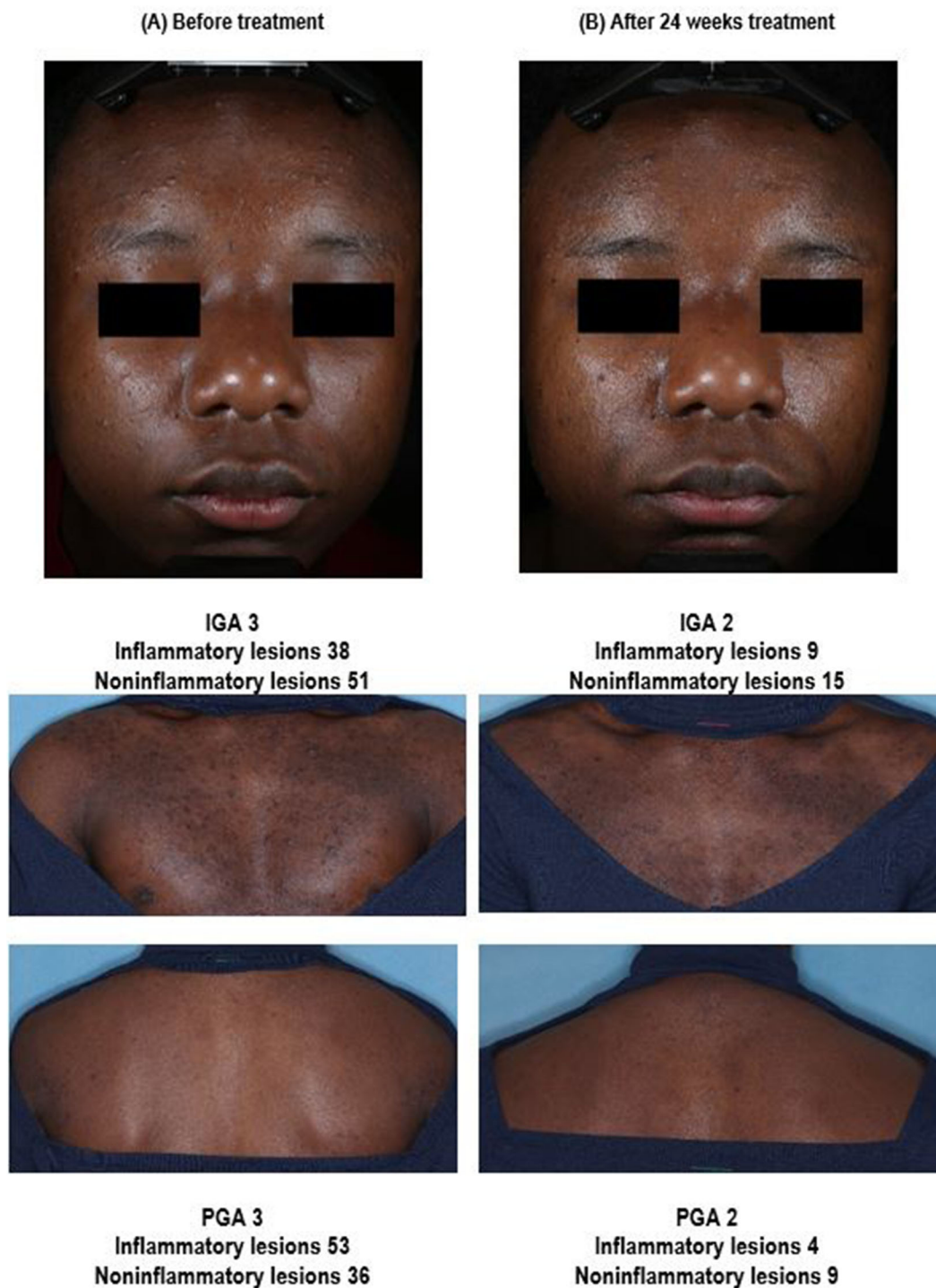
significantly decreased on the face and trunk (Fig. 5).

Overall compliance was 100% for both face and trunk. She experienced no cutaneous treatment-emergent adverse events, and the only tolerability reactions of moderate severity were scaling and stinging/burning at week 1 on the face only.

## DISCUSSION

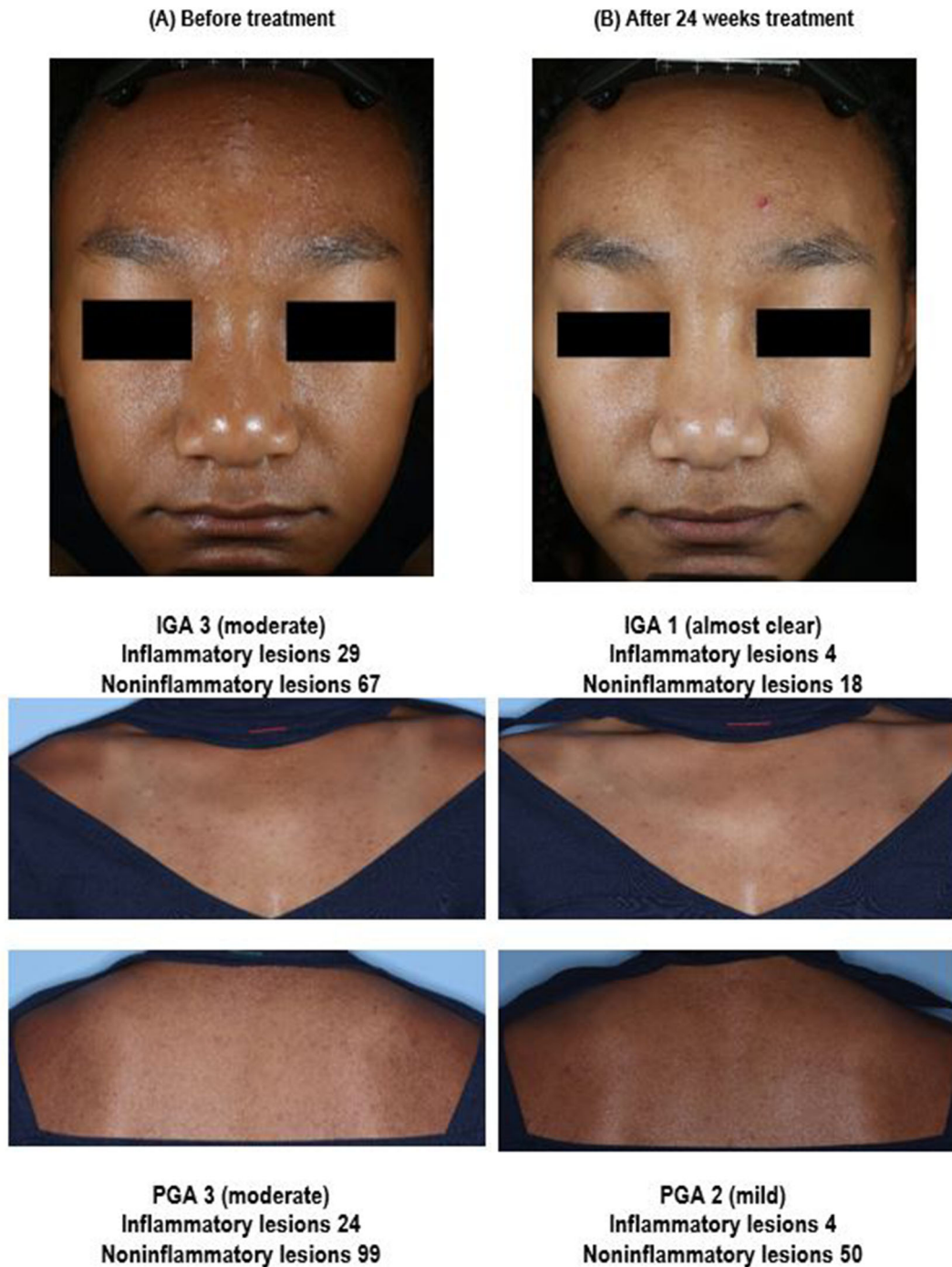This case series illustrates the favorable efficacy and safety of trifarotene 0.005% cream, with or without doxycycline, for treating facial and truncal AV in patients with darker skin phototypes III, IV, V, and VI and with moderate or severe AV. Significant reductions in lesions were observed for all five cases, and this was visually demonstrated in the clinical photographs.

In all five cases, treatment with trifarotene 0.005% cream, with or without doxycycline, was well tolerated with only mild or moderate



**Fig. 4** Case 4: photographs of a 16-year-old Black/African American male subject with Fitzpatrick skin type VI before (A) and after 24 weeks (B) of treatment with trifarotene 0.005% cream for facial and truncal acne vulgaris. *IGA*

Investigator Global Assessment for face, *PGA* Physician Global Assessment for trunk



**Fig. 5** Case 5: photographs of a 12-year-old Black/African American female subject with Fitzpatrick skin type IV before (A) and after 24 weeks (B) of treatment with

local tolerability reactions, presenting as transient signs and symptoms, at the sites of application, and there were no instances of

trifarotene 0.005% cream for facial and truncal acne. *IGA* Investigator Global Assessment for face, *PGA* Physician Global Assessment for trunk

treatment-emergent adverse events. Case 3 experienced no cutaneous treatment-emergent adverse events or any local tolerability reactions



throughout the study, even though he did not use the provided noncomedogenic moisturizer, although he did use the gentle cleanser and the sunscreen.

All subjects were advised to minimize sun exposure (occupational exposure to the sun, sunbathing, phototherapy) and to use sunscreen and protective clothing over treated areas, as well as to avoid excessive wind and cold, as much as possible during the study. AV is a common cause for PIH in patients with SoC and may have a significant psychosocial impact [5, 16, 17]. Risk of PIH is higher in patients with darker skin phototypes, severe AV, or trauma to AV lesions [18]. Compared with facial AV, clinical experience suggests that PIH from truncal AV has a tendency to be more persistent. Furthermore, a recent case report and literature review has reported drug-induced hyperpigmentation associated with doxycycline monohydrate 100 mg twice daily (BID), but it was concluded to be uncommon and, in most cases, resolved after doxycycline was discontinued [19]. Notably, a review of the published photographs in the aforementioned reference of doxycycline-induced hyperpigmentation showed more diffuse hyperpigmentation that is distinct from the focal follicular/perifollicular PIH that is characteristically associated with AV.

Through several mechanisms of action, various topical retinoids (e.g., tretinoin, tazarotene, adapalene) have been reported to reduce hyperpigmentation in patients with skin phototypes IV–VI, and also in Asian skin, which generally includes medium skin phototypes (III–IV), possibly also lighter skin phototypes (II–III), and darker phototypes in India, for example [20–24]. Similar to other retinoids, trifarotene is an excellent comedolytic with substantial antiinflammatory activity.

Furthermore, preclinical data with trifarotene, the newest retinoid, has shown superior antipigmentation on ultraviolet-radiation-induced pigmentation activity compared with both tretinoin and adapalene in mouse models [25]; this property may be efficacious in the treatment of PIH associated with AV, seen commonly in SoC [25, 26]. Topical retinoids may be used to treat AV-associated dyschromias in SoC to improve skin tone and texture,

including lightening of focal hyperpigmentation [23, 27]. Effective treatment with topical retinoids should be started as early as possible unless contraindicated or not recommended under specific circumstances, for example, during pregnancy [5].

A clinical review on PIH in SoC concluded that educating patients about the dual benefits of retinoids on both AV and PIH, the importance of a skin regimen with gentle cleansing, moisturizing, and photoprotection, as well as managing expectations on how long the therapy will take to work on the AV and PIH, can improve compliance and treatment outcomes [5]. Similarly in this case series, four out of five subjects had close to 100% adherence. Case 1 is an Asian female subject with skin phototype III and had a slightly lower adherence of 85% for topical trifarotene 0.005% cream, but the only local tolerability reaction was moderate erythema at week 4. Tolerability signs and symptoms are generally mild and transient, occurring during the first 4 weeks of treatment, and topical retinoid therapy can be optimized to provide excellent results in treating AV in Asian patients [7, 23, 28].

The main limitation of this case series is the small number of cases and that there were two different trial designs. However, subjects with skin phototypes III, IV, V, and VI were included along with photographs illustrating evidence for the treatment of both moderate or severe facial AV, as well as moderate truncal AV.

## CONCLUSIONS

The findings of this case series support the favorable efficacy and safety of treatment with trifarotene 0.005% cream, with or without 120 mg oral doxycycline MPC, for facial and truncal AV in subjects with SoC.

## ACKNOWLEDGEMENTS

The authors wish to thank the five subjects.

**Funding.** Funding for the study, the journal's Rapid Service Fee, and the editorial

assistance received was provided by Galderma Laboratories. L.P.

**Medical Writing and Editorial Assistance.** Editorial assistance in the preparation of this article was provided by Helen Simpson, PhD, of My Word Medical Writing. Support for this assistance was funded by Galderma.

**Authorship.** All named authors meet the International Committee of Medical Journal Editors (ICMJE) criteria for authorship for this article, take responsibility for the integrity of the work as a whole, and have given their approval for this version to be published.

**Author Contributions.** Dr James Q Del Rosso, Dr Edward Lain, and Dr Andrew Alexis were involved in drafting the manuscript, critically reviewing and approving the manuscript. Dr Jean Philippe York was involved in concept, drafting the manuscript, critically reviewing and approving the manuscript.

**Disclosures.** Dr. James Q Del Rosso has served as a research investigator, consultant, and/or speaker for Galderma, Mayne Pharma, Allergan, Almirall, Arcutis, Bayer, Bausch Health (Ortho Dermatologics), Biorasi, Bristol Myers Squibb, Cassiopea, Cutera, Dermavant, Dr. Reddy, EPI Health, Evommune, Ferndale, JEM Health, Journey, Johnson & Johnson, Leo Pharma, L'Oreal, Sebacia, Sol Gel Technologies, Sun Pharma, and Vyne. Dr Edward Lain has been an advisory board member, investigator, speaker and/or consultant for AbbVie, Aclaris Therapeutics, Allergan, Almirall, AstraZeneca, Athenex, Biopelle, BioPharmX, Biorasi, BMS, Brickell Biotech, Cassiopea S.p.A., Celgene, Cellceutix, ChemoCentryx, Cutanea Life Sciences, Dermira, Dow Pharmaceutical Sciences, Dr Reddy's Laboratory, Eli Lilly and Company, Gage Development Company, Galderma, Hovione, Johnson & Johnson, Kadmon Corporation, La Roche-Posay Laboratoire, Leo Pharma, Medimmune, Menlo Therapeutics, Moleculin, Neothetics, Novartis, Ortho Dermatologics, Pfizer, Promius Pharma, Sebacia, Sienna Labs, SkinCeuticals, Sol-Gel Technologies, UCB Pharma, Valeant. Dr Andrew Alexis

has received grants (funds to institution) from Leo, Novartis, Almirall, Bristol-Myers-Squibb, Amgen, Menlo, Galderma, Valeant (Bausch Health), Cara, Arcutis, Dermavant; has been an advisory board member/consultant for Leo, Galderma, Pfizer, Sanofi-Regeneron, Dermavant, Beiersdorf, Valeant, L'Oreal, BMS, Bausch health, UCB, Vyne, Arcutis, Janssen, Allergan, Almirall, Abbvie, Sol-Gel, Amgen, VisualDx, Eli Lilly, Swiss American, Cutera; has been a speaker for Regeneron, Sanofi-Genzyme, Pfizer, BMS; and has received royalties from Springer, Wiley-Blackwell, Wolters Kluwer Health. Dr JP York is an employee of Galderma Laboratories L.P.

**Compliance with Ethics Guidelines.** All subjects, or their parent or guardian, provided written informed consent before participating in the study and for publication of their clinical details and photographs. All data were deidentified. Both studies were performed in accordance with the Helsinki Declaration of 1964, and its later amendments. Ethics committee and/or institutional review board (IRB) approval were obtained prior to Study 1 (Copernicus Group IRB) and Study 2 (IntegReview meeting held on February 18, 2019).

**Data Availability.** The datasets generated during and/or analyzed during this case series study are available from the corresponding author upon reasonable request made within 6 months following publication.

**Open Access.** This article is licensed under a Creative Commons Attribution-NonCommercial 4.0 International License, which permits any non-commercial use, sharing, adaptation, distribution and reproduction in any medium or format, as long as you give appropriate credit to the original author(s) and the source, provide a link to the Creative Commons licence, and indicate if changes were made. The images or other third party material in this article are included in the article's Creative Commons licence, unless indicated otherwise in a credit line to the material. If material is not included in the article's Creative Commons licence and your intended use is not permitted by statutory

regulation or exceeds the permitted use, you will need to obtain permission directly from the copyright holder. To view a copy of this licence, visit <http://creativecommons.org/licenses/by-nc/4.0/>.

## REFERENCES

- Taylor SC, Cook-Bolden F, Rahman Z, Strachan D. Acne vulgaris in skin of color. *J Am Acad Dermatol*. 2002;46(2 Suppl Understanding):S98–106.
- Lester JC, Taylor SC, Chren MM. Under-representation of skin of colour in dermatology images: not just an educational issue. *Br J Dermatol*. 2019;180(6):1521–2.
- Yin NC, McMichael AJ. Acne in patients with skin of color: practical management. *Am J Clin Dermatol*. 2014;15(1):7–16.
- Alexis AF, Harper JC, Stein Gold LF, Tan JKL. Treating acne in patients with skin of color. *Semin Cutan Med Surg*. 2018;37(3s):S71–3.
- Callender VD, Baldwin H, Cook-Bolden FE, Alexis AF, Stein Gold L, Guenin E. Effects of topical retinoids on acne and post-inflammatory hyperpigmentation in patients with skin of color: a clinical review and implications for practice. *Am J Clin Dermatol*. 2022;23(1):69–81.
- Alexis AF. Acne vulgaris in skin of color: understanding nuances and optimizing treatment outcomes. *J Drugs Dermatol*. 2014;13(6):s61–5.
- Alexis AF, Woolery-Lloyd H, Williams K, et al. Racial/ethnic variations in acne: implications for treatment and skin care recommendations for acne patients with skin of color. *J Drugs Dermatol*. 2021;20(7):716–25.
- Leyden J, Stein-Gold L, Weiss J. Why topical retinoids are mainstay of therapy for acne. *Dermatol Ther (Heidelb)*. 2017;7(3):293–304.
- Baldwin H, Webster G, Stein Gold L, Callender V, Cook-Bolden FE, Guenin E. 50 years of topical retinoids for acne: evolution of treatment. *Am J Clin Dermatol*. 2021;22(3):315–27.
- Thoreau E, Arlabosse JM, Bouix-Peter C, et al. Structure-based design of trifarotene (CD5789), a potent and selective RAR $\gamma$  agonist for the treatment of acne. *Bioorg Med Chem Lett*. 2018;28(10):1736–41.
- Tan J, Thiboutot D, Popp G, et al. Randomized phase 3 evaluation of trifarotene 50  $\mu$ g/g cream treatment of moderate facial and truncal acne. *J Am Acad Dermatol*. 2019;80(6):1691–9.
- Blume-Peytavi U, Fowler J, Kemény L, et al. Long-term safety and efficacy of trifarotene 50  $\mu$ g/g cream, a first-in-class RAR $\gamma$  selective topical retinoid, in patients with moderate facial and truncal acne. *J Eur Acad Dermatol Venereol*. 2020;34(1):166–73.
- Del Rosso JQ. Oral doxycycline in the management of acne vulgaris: current perspectives on clinical use and recent findings with a new double-scored small tablet formulation. *J Clin Aesthet Dermatol*. 2015;8(5):19–26.
- Zaenglein AL, Pathy AL, Schlosser BJ, et al. Guidelines of care for the management of acne vulgaris. *J Am Acad Dermatol*. 2016;74(5):945–73.e33.
- US Food and Drug Administration. Summary of product characteristics. [https://www.accessdata.fda.gov/drugsatfda\\_docs/label/2019/211527s000lbl.pdf](https://www.accessdata.fda.gov/drugsatfda_docs/label/2019/211527s000lbl.pdf). Accessed 28 Feb 2022.
- Darji K, Varade R, West D, Armbrecht ES, Guo MA. Psychosocial impact of postinflammatory hyperpigmentation in patients with acne vulgaris. *J Clin Aesthet Dermatol*. 2017;10(5):18–23.
- França K, Keri J. Psychosocial impact of acne and postinflammatory hyperpigmentation. *An Bras Dermatol*. 2017;92(4):505–9.
- Al-Qarqaz F, Bodoor K, Baba A, Al-Yousef A, Muhaidat J, Alshiyab D. Post-acne hyperpigmentation: evaluation of risk factors and the use of artificial neural network as a predictive classifier. *Dermatol Rep*. 2021;13(3):8223.
- Afrin A, Cohen PR. Doxycycline-associated hyperpigmentation: a case report and literature review. *Cureus*. 2022;14(4): e23754.
- Bulengo-Ransby SM, Griffiths CE, Kimbrough-Green CK, et al. Topical tretinoin (retinoic acid) therapy for hyperpigmented lesions caused by inflammation of the skin in Black patients. *N Engl J Med*. 1993;328(20):1438–43.
- Grimes P, Callender V. Tazarotene cream for postinflammatory hyperpigmentation and acne vulgaris in darker skin: a double-blind, randomized, vehicle-controlled study. *Cutis*. 2006;77(1):45–50.
- Jacyk WK. Adapalene in the treatment of African patients. *J Eur Acad Dermatol Venereol*. 2001;15(Suppl 3):37–42.

- 
23. See JA, Goh CL, Hayashi N, Suh DH, Casintahan FA. Optimizing the use of topical retinoids in Asian acne patients. *J Dermatol*. 2018;45(5):522–8.
  24. Elbuluk N, Grimes P, Chien A, et al. The pathogenesis and management of acne-induced post-inflammatory hyperpigmentation. *Am J Clin Dermatol*. 2021;22(6):829–36.
  25. Aubert J, Piwnica D, Bertino B, et al. Nonclinical and human pharmacology of the potent and selective topical retinoic acid receptor- $\gamma$  agonist trifarotene. *Br J Dermatol*. 2018;179(2):442–56.
  26. Bell KA, Brumfiel CM, Haidari W, Boger L. Trifarotene for the treatment of facial and truncal acne. *Ann Pharmacother*. 2021;55(1):111–6.
  27. Kang SJ, Davis SA, Feldman SR, McMichael AJ. Dyschromia in skin of color. *J Drugs Dermatol*. 2014;13(4):401–6.
  28. Goh CL, Tang MB, Briantais P, Kaoukhov A, Soto P. Adapalene gel 0.1% is better tolerated than tretinoin gel 0.025% among healthy volunteers of various ethnic origins. *J Dermatol Treat*. 2009;20(5):282–8.