

# Bilateral sagittal split osteotomy a versatile approach for correction of facial deformity: A review literature

## ABSTRACT

Poor facial cosmesis resultant from dysgnathias usually accounts for a range of these individuals' psychological and social problems. Disturbances of both esthetics and function are caused by jaw deformity and associated structures' deformity such as malocclusion. The correction of these deformities is one of the most challenging and intriguing aspects of maxillofacial surgery. Despite having become routine only relatively recently, rigid internal fixation has advanced rapidly, its results are consistent and predictable and thus, its knowledge applies in orthognathic surgery besides other areas of maxillofacial surgery. The bilateral sagittal split osteotomy (BSSO) is a common orthognathic procedure performed on the mandible. First described by Trauner and Obwegeser in 1957, modified by Dal Pont and refined by Epker, several modifications of the BSSO have been introduced aiming to enhance surgical convenience, minimize morbidity, and maximize stability. The aim of this article is to review the literature of this technique from the historical perspective and to present a standard operation technique.

**Keywords:** Facial deformity, orthognathic surgery, sagittal split mandibular osteotomy

## INTRODUCTION

Asymmetrical facial deformity, manifested easily as a defective facial profile, has been of intense interdisciplinary interest to both, the oral and maxillofacial surgeon and the orthodontist. Expected soft-tissue changes after surgery, the extent of the dentofacial deformity and the caliber of beneficial jaw movement distance dictate selection of osteotomy and its site. Since the orthodontic restoration of masticatory function usually relies on straight basal bone, even for the patient whose chief complaint is not dominated by cosmesis, surgery is of great importance. Diagnosis and treatment planning must include an accurate prediction of the posttreatment (both surgical and orthodontic) facial profile.

Ranging from dentoalveolar discrepancies to severe facial asymmetry and disfigurement of the face, deformities of the middle and lower third of the face cause social embarrassment besides resulting in defective speech and mastication. These also severely impact self-esteem and the quality of life.

## EVOLUTION OF THE BILATERAL SAGITTAL SPLIT OSTEOTOMY

After Hullihen corrected a protruded mandibular alveolar segment using an osteotomy, which is regarded as the first mandibular osteotomy in 1849,<sup>[1]</sup> Blair is credited with the first osteotomy of the entire mandibular body for the correction of prognathism.<sup>[2]</sup> Subsequently, Blair and Angle published certain operations which mark the beginning of development

**VEERENDRA PRASAD, SANJAY KUMAR<sup>1</sup>, HARSHA PRADHAN<sup>1</sup>, REHAN SIDDIQUI<sup>1</sup>, IQBAL ALI<sup>1</sup>**

Department of Plastic Surgery, King George Medical University, <sup>1</sup>Department of Oral and Maxillofacial Surgery, Career Postgraduate Institute of Dental Science and Hospital, Lucknow, Uttar Pradesh, India

**Address for correspondence:** Dr. Sanjay Kumar, Department of Oral and Maxillofacial Surgery, Career Postgraduate Institute of Dental Science and Hospital, Lucknow, Uttar Pradesh, India.  
E-mail: drskomfs@gmail.com

**Received:** 11 December 2018, **Revised:** 17 February 2019, **Accepted:** 26 September 2019, **Published:** 16 March 2021

Access this article online	
<b>Website:</b> www.njms.in	<b>Quick Response Code</b> 
<b>DOI:</b> 10.4103/njms.NJMS_89_18	

This is an open access journal, and articles are distributed under the terms of the Creative Commons Attribution-NonCommercial-ShareAlike 4.0 License, which allows others to remix, tweak, and build upon the work non-commercially, as long as appropriate credit is given and the new creations are licensed under the identical terms.

**For reprints contact:** WKHLRPMedknow\_reprints@wolterskluwer.com

**How to cite this article:** Prasad V, Kumar S, Pradhan H, Siddiqui R, Ali I. Bilateral sagittal split osteotomy a versatile approach for correction of facial deformity: A review literature. Natl J Maxillofac Surg 2021;12:8-12.

in oral surgery.<sup>[3]</sup> In 1907, Blair corrected a Class II mandibular dysgnathia by advancing the mandibular body using a horizontal subcondylar osteotomy [Figure 1]. This was after the 1906 proposals made by Von Eiselberg<sup>[4]</sup> for mandibular body lengthening. Bruhn, in 1921 did a mandibular body vertical osteotomy followed by bone grafting.<sup>[5]</sup> Kostecka, in 1931, published a method similar to Blair's.<sup>[6]</sup>

In 1925, using an extraoral approach, Limberg developed the subcondylar osteotomy through the condylar neck.<sup>[7]</sup> Later, the inverted "L" mandibular osteotomy was described by Wassmund in 1927.<sup>[8]</sup> It was in 1939 that Kazanjian developed the beveled horizontal osteotomy of the ramus [Figure 2].<sup>[8]</sup> Schuchardt<sup>[9]</sup> in 1942 was the first to use the intraoral approach for the step osteotomy of the vertical ramus [Figures 3 and 4]. This was the 1<sup>st</sup> time that the sagittal split osteotomy was used. The inferior alveolar nerve (IAN) was not harmed.

Trauner and Obwegeser in 1957 modified Schuchardt's procedure. This osteotomy was a result of Obwegeser's quest for an osteotomy that could not only be done transorally but which would result in broad contacting bone surfaces after repositioning. The available options till that time attempted only beveling in the transverse plane as variations of the horizontal osteotomy. Having seen radiographic evidence of sagittal fractures, Obwegeser attempted it on a cadaver, transorally, at the Institute of Anatomy, Graz, Austria [Figures 5 and 6]. On reporting success to Trauner, he was informed that Perthes and Schlossman had already attempted ramal sagittal splitting extraorally. Later, while reviewing G. Perthes' article, Obwegeser found out that the osteotomy was an oblique transverse osteotomy done extraorally, similar to the osteotomy published by V. Kazanjian in 1951 [Figure 2]. The approach that these two authors had used was, instead of a sagittal split, an oblique transverse osteotomy, in an attempt to increase the surface area.

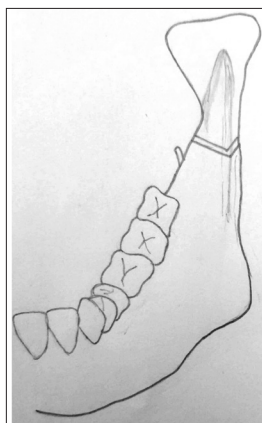


Figure 1: Blair

Since Obwegeser had conceived a true sagittal split which would increase contact surface area, Trauner got interested and suggested operating a patient, one side with a reverse "L" osteotomy using a combined extraoral and intraoral approach and on the other side with Obwegeser's idea.

A 27-year-old edentulous, female patient of mandibular prognathism was operated on the February 17, 1953. Acrylic splints were used for postoperative intermaxillary fixation. After Trauner completed his side, Obwegeser's attempt at the osteotomy resulted in ramal shattering instead of splitting. Reduction was achieved and even though the clinical outcome was acceptable, the transoral technique was "less than as I had hoped it would be." Yet, Trauner remained supportive, and a second case was operated after a 24-year-old female patient of prognathism came to them. Trauner and Obwegeser were operating and Schuchardt, who was visiting, was assisting. Operating first, as Trauner suggested, Obwegeser operated on the left side, fractured the coronoid process unintentionally, but succeeded in sagittally splitting the mandible, without injuring the nerve.

In the third operation, on April 9, 1956, done in Zurich, Switzerland, Obwegeser encountered the complication of a free lateral ramus, yet, eventually, the operation succeeded.<sup>[10]</sup>

Dal Pont modified this procedure by advancing the lower horizontal cut to the body of the mandible and rotating it to vertical at a level between the first and second molars<sup>[11]</sup> [Figures 7 and 8].

Hunsuck disagreed with making the cut through the *Lingula*. He thought that the mandible would split on its own if chisels were used.<sup>[12]</sup> He made the buccal cut at the junction of the ascending ramus and body in the tooth-bearing region, just distal to the second molar, down to the mandibular notch anterior to the masseteric insertion.<sup>[11]</sup>

In 1977, Bell and Schendel published an article which gave a direction for future modifications.<sup>[13]</sup> Epker, in

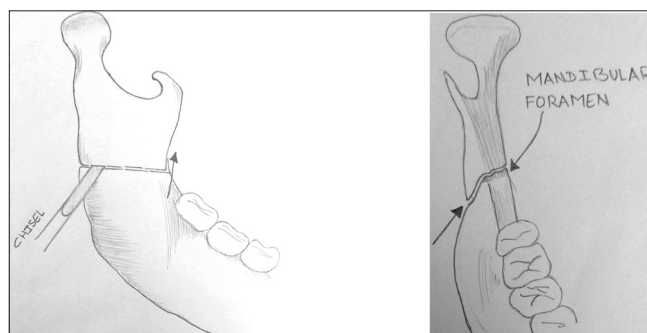


Figure 2: Kazanjian

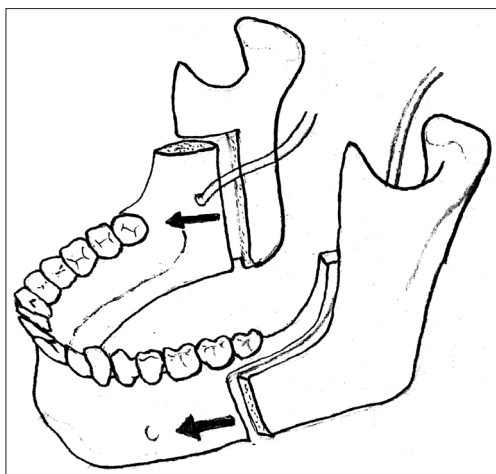


Figure 3: SCHUCHARDT

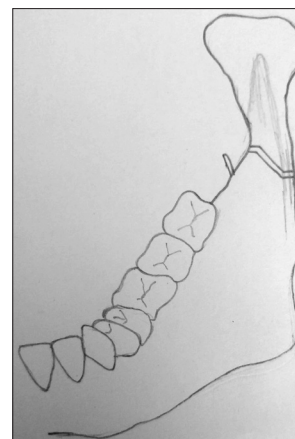


Figure 4: Schuchardt

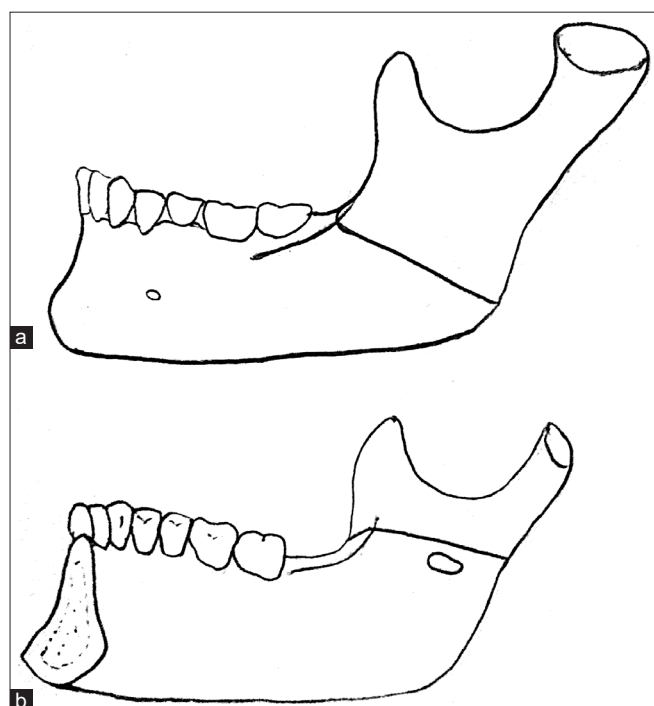


Figure 5: (a) Obwegesers Osteotomy in Buccal View (b) Obwegesers Osteotomy in Lingual View

1977 did not reflect the masseter widely and instead used a wire stabilization of both segments, proximally low and distally high. To avoid bad splits, he considered it necessary to do complete osteotomy of the inferior mandibular cortex.<sup>[14]</sup>

Steinhauser and Rudzki-Janson<sup>[15]</sup> and Bell *et al.*,<sup>[16,17]</sup> in the 1980s, published books on the principles of osteotomies in orthognathic surgery. It was in 1985 that Bell also switched to rigid fixation.

Rajchel *et al.* in 1986 reported on the mediolateral position of the mandibular nerve and concluded that the vertical buccal

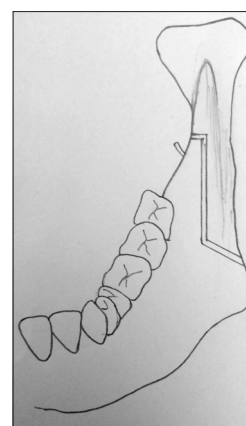


Figure 6: Obwegeser 1957

corticotomy, for the safety of the IAN, should be located at the level of the first molar.<sup>[18]</sup> In a reaction, Wolford *et al.*<sup>[19]</sup> agreed on moving the vertical cut, further anteriorly to prevent IAN injury. Obwegeser also responded by suggesting moving the anterior vertical cut between the second premolar and first molar.

In 1990, Wolford and Davis<sup>[20]</sup> used a specially designed saw to cut the inferior border resulting in a low sagittal split. Since the IAN is more frequently found in the distal fragment, it is better protected in this technique.

### TREATMENT PLANNING

Dysgnathia patients need treatment plans made for specifically for and fit to each individual. The most important aspects of patient care in these cases include a thorough evaluation and diagnosis. These are based on an analysis of information arrived at by obtaining the patient's medical history, social history, motivation, objective, facial esthetic profile (frontal and lateral), soft and hard tissue, cephalometric analysis, dental relation and degree of fractional, and social and

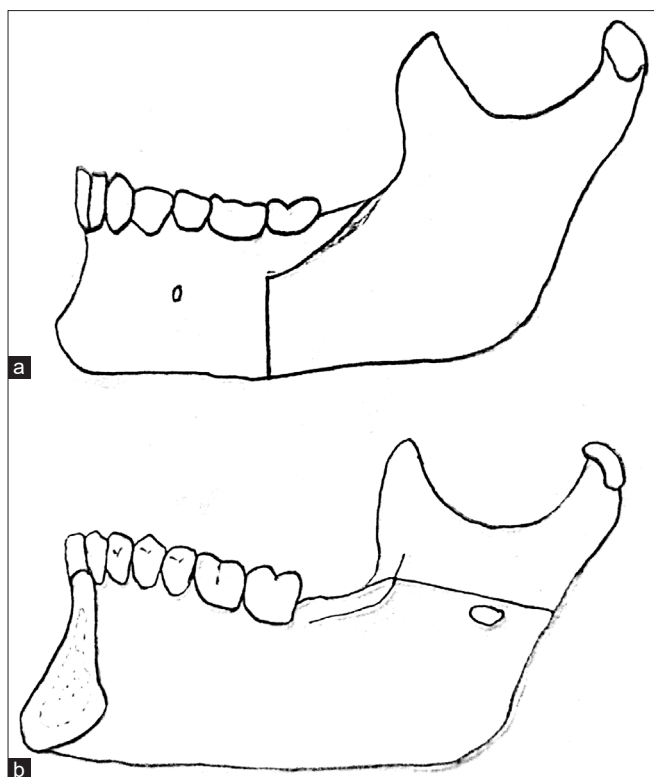


Figure 7: (a) Dal Ponts Modification – Buccal View (b) Dal Ponts Modification – Lingual View

psychological disturbances. Evaluation for orthognathic surgery itself can be divided into six realms:

1. Chief complaints of the patient
2. Clinical examination
3. Radiographic analysis
4. Dental model analysis
5. Photocephalometric analysis
6. Mock surgery.

Often attention to the chief complaint paves the way to the patient's ultimate satisfaction. Counseling is imperative for people with unrealistic expectations for them to comprehend the limitations of treatment and the likely outcome, before the start of orthodontic or surgical treatment. Some valuable guidelines have emerged as a result of cooperative studies between surgeons and psychiatrists for the selection and evaluation of such patients for surgery. All the main anomalies should be corrected in the first surgery without the breach of good surgical practice. Before the formulation of the definite surgical plan, an orthodontically stable occlusal relationship is critical for postoperative fragment stability.

#### INDICATIONS FOR THE BILATERAL SAGITTAL SPLIT OSTEOTOMY

The bilateral sagittal split osteotomy (BSSO) is a versatile surgical procedure that can be used to treat mandibular

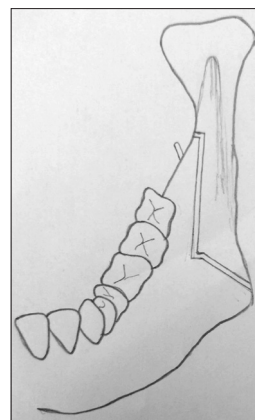


Figure 8: Sagittal split described by Dal Pont buccal osteotomy line lingual osteotomy line

excess, deficit, mandibular asymmetry, open bite and crossbite, although having limitations. It is indicated for<sup>[21]</sup>:

1. Mandibular deficiencies:
  - Mandibular deficiencies with normal or short face
  - Mandibular deficiencies with long face: increase maxillary vertical dimension
  - Mandibular deficiencies with long face: excessive chin height
  - Sleep apnea.
2. For the treatment of these abnormalities, the limitations of the BSSO are:
  - For advancements beyond 10–12 mm, an extraoral approach needs consideration
  - Additional surgery is required for most dentofacial deformities.
3. Mandibular excess
  - Short face
  - Long face
  - For the treatment of these abnormalities, the limitation of the BSSO is
  - Large setbacks of  $\geq 7-8$  mm need an intraoral vertical ramus osteotomy/inverted "L" osteotomy.
4. Mandibular asymmetries
  - Hemimandibular hypertrophy
  - Hemimandibular elongation.
5. Open bite
6. Crossbite.

#### MANDIBULAR RAMUS OSTEOTOMY

The BSSO is probably one of the most popular osteotomy performed for the correction mandibular deformity. Following the standard presurgical protocol, local anesthetic solution may be infiltrated locally into soft tissue for hemostasis. For the purpose of proper closure, the vertical incision must end inferiolaterally in soft tissue away from attached gingiva, thus allowing enough tissue on either

side. Then in a subperiosteal plane soft tissue is elevated of the posterior portion of the mandibular body and lateral aspect of the ramus. This is followed by the lifting of the fascial slings of the posterior and inferior borders and then the soft tissue medial to the ramus between the mandibular foramen and depth of coronoid notch. The soft tissue medial to the ramus is elevated up to the posterior border of the ramus. Dal Pont modified cuts are made Figures 7 and 8. The cut depth should be entirely transcortical except when the ramus is extremely thin. In such cases, the medial cut must score the cortex. Osteotomy follows, using a well-inclined osteotome. Besides a sharp stroke with the mallet being imperative, osteotome inclination is critical. The splitting force needs to be transmitted laterally within the osteotomy so that posterior border may split, in the contrast to the force being transmitted directly into the vertical plane of the osteotomy in which case a medial fracture extending to the *Lingula*, leaving the medial cortex proximal to the *Lingula* intact, will result. This will reduce the amount of overlapping bone. To prevent the involvement of medial pterygoid, medial fragment soft-tissue elevation is kept limited. For better control of fragments at fixation time, reduced risk of inferior alveolar neurovascular bundle injury and better visibility, a complete mobilization of proximal fragment is ensured.

Postosteotomy interfragmentary stability can be achieved using mandibular circumferential wiring, transosseous wiring bone plates, or positioning screws. The condyles are then stabilized within their glenoid fossa using moderate pressure from either by Kocher or tonsil clamps to the proximal segments.

## CONCLUSION

The BSSO is a versatile surgical procedure which can be used for both advancing and retruding the mandible as needed. Designed to protect the IAN while offering a range of bone movement limited by soft-tissue elasticity and a need for bony contact (for stabilization), this procedure leaves no extraoral scar. Besides, in recent times, with rigid internal fixation, there is no need for prolonged intermaxillary fixation.

## Financial support and sponsorship

Nil.

## Conflicts of interest

There are no conflicts of interest.

## REFERENCES

- Hullihen SP. Case of elongation of the under jaw and distortion of the face and neck, caused by a burn, successfully treated. *Am J Dent Sci* 1849;9:157-65.
- Blair V. Operations on the jaw-bone and face. *Surg Gynecol Obstet* 1907;4:67-78.
- Biederman W. The strange story of the angle operation. *Ann Dent* 1956;15:1-9.
- Von Eiselsberg A. Uber plastic on ectropion of the lower jaw (progeny). *KI Wochenschr* 1906;19:1505-8.
- Bruhn C. Management of Gunshot Injuries of the Jaw, Based on the Experience of the Jaw Hospital in Dusseldorf (in German). Wiesbaden, Germany: Verlag Von Bergmann; 1917.
- Kostecka F. The surgical therapy ider proggeni. *Zahnaertzl round* 1931;40:669.
- Limberg A. Treatment open bite by means of plastic oblique osteotomy of the ascending rami of mandible. *Dent Cosmos* 1925;67:1191-200.
- Wassmund M. Fractures and luxations of the facial defect under Berlick's complications d. In: *Brain skull Meusser*. Berlin, Germany: Meusser; 1927.
- Schuchardt K. Elin vorschlag to improve the wire bus connection. *Dtsch Zahn Mund Kieferheilkd* 1956;24:39-44.
- Abwegeser HL. Orthognathic surgery and a tale of how three procedures came to be: A letter to the next generations of surgeons. *Clin Plast Surg* 2007;34:331-55.
- Dal Pont G. Retromolar osteotomy for the correction of prognathism. *J Oral Surg Anesth Hosp Dent Serv* 1961;19:42-7.
- Hunsuck EE. A modified intraoral sagittal splitting technic for correction of mandibular prognathism. *J Oral Surg* 1968;26:250-3.
- Bell WH, Schendel SA. Biologic basis for modification of the sagittal ramus split operation. *J Oral Surg* 1977;35:362-9.
- Epker BN. Modifications in the sagittal osteotomy of the mandible. *J Oral Surg* 1977;35:157-9.
- Steinhauser EW, Rudzki-Janson IM. Treatment procedure typical dysgnathia forms. In: *Orthodontic Surgery*. Vol. 2. Berlin: Quintessence Publishing; 1994.
- Bell WH, Proffit WR, White RP. Surgical Correction of Dentofacial Deformities. Vol. 1. Philadelphia: W.B. Saunders Company; 1980.
- Bell WH, Proffit WR, White RP. Surgical correction of Dentofacial Deformities. Vol. 2. Philadelphia: W.B. Saunders Company; 1980.
- Rajchel J, Ellis E 3<sup>rd</sup>, Fonseca RJ. The anatomical location of the mandibular canal: Its relationship to the sagittal ramus osteotomy. *Int J Adult Orthodon Orthognath Surg* 1986;1:37-47.
- Wolford LM, Bennett MA, Rafferty CG. Modification of the mandibular ramus sagittal split osteotomy. *Oral Surg Oral Med Oral Pathol* 1987;64:146-55.
- Wolford LM, Davis WM Jr. The mandibular inferior border split: A modification in the sagittal split osteotomy. *J Oral Maxillofac Surg* 1990;48:92-4.
- Beukes J, Reyneke JP, Damstra J. Unilateral sagittal split mandibular ramus osteotomy: Indications and geometry. *Br J Oral Maxillofac Surg* 2016;54:219-23.