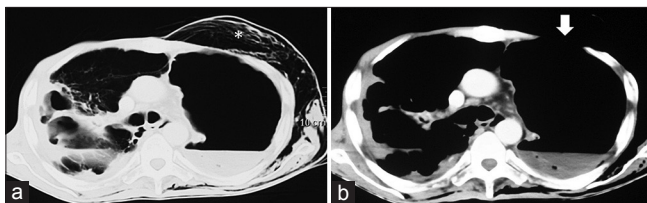


# Rare cause of spontaneous subcutaneous emphysema

Sir,

Trauma and iatrogenic injury are the most common causes of subcutaneous emphysema. Subcutaneous emphysema (with or without pneumothorax or pneumomediastinum) that occurs spontaneously is less frequently seen. It occurs as a result of a breach in either the airway or the alveolar lining following which the air tracks through bronchovascular sheaths (Macklin effect) to reach the mediastinum and then into the subcutaneous spaces of the neck through the thoracic inlet.<sup>[1]</sup> Spontaneous subcutaneous emphysema occurring as a result of a rupture in the chest wall is rare.

A 60-year old gentleman presented with swelling of the face, neck, and chest for 3 days following a bout of cough. He also had fever, productive cough, and chest pain for 2 months. About 6 months earlier, he was advised antituberculosis treatment (ATT) for sputum-positive pulmonary tuberculosis, that he discontinued prematurely after 1 month. Examination on presentation revealed subcutaneous emphysema involving the face, neck, and chest with reduced breath sound intensity bilaterally. A part of the left anterior chest wall showed paradoxical movement, i.e., bulging on expiration and drawing in during inspiration (supplemental video). Computed tomography (CT) of the chest revealed multiple cavities with fibrosis in the entire right lung and left-sided hydropneumothorax [Figure 1a]. The left thoracic cavity was communicating with the subcutaneous space resulting in surgical emphysema [Figure 1b]. An intercostal drainage tube (ICD) was placed in the left pleural cavity. Examination of the sputum and pus (from the chest drain) revealed the presence of acid-fast bacilli. Subsequently, both the specimens showed growth of *Mycobacterium tuberculosis*, sensitive to all first-line antituberculosis drugs. The cultures sent for bacteria were



**Figure 1:** (a) Computed tomography of the thorax showing subcutaneous emphysema (asterisk) and hydropneumothorax on the left side; the right hemithorax shows pulmonary cavities and fibrosis (b) Computed tomography of the thorax shows a defect in the left anterior chest wall (white arrow) demonstrating a communication between the thoracic cavity and subcutaneous space

sterile. Enzyme-linked immunosorbent assay performed for the human immunodeficiency virus was negative in the serum. The patient was advised to undergo surgical repair of the defect that he refused. He was started on four-drug ATT (rifampicin, isoniazid, pyrazinamide, and ethambutol). The patient's fever abated in 2 weeks and the pus was completely drained. After 4 weeks, the ICD was removed once the daily drainage decreased to less than 30 mL of clear fluid.

Tuberculous empyema signifies a chronic, active infection of the pleural space that contains numerous tubercle bacilli.<sup>[2]</sup> It is encountered much less frequently than tuberculous pleural effusions that are paucibacillary and occur due to a type IV hypersensitivity reaction to the proteins of *M. tuberculosis*. Uncommonly, tuberculous empyema can cause contiguous involvement of the thoracic cage resulting in destruction of the bones and soft tissue of the chest wall. This leads to its evolution into empyema necessitans that is defined as a collection of inflammatory tissue that ruptures spontaneously through a weakness in the chest wall into surrounding soft tissues.<sup>[3]</sup> Our patient had a tuberculous empyema that ruptured through the chest wall and also led to air dissecting through the subcutaneous space.

Spontaneous subcutaneous emphysema has previously been described in association with pulmonary tuberculosis.<sup>[4,5]</sup> The index patient not only had chest wall destruction and spontaneous subcutaneous emphysema due to pulmonary and pleural tuberculosis but also a chest segment with paradoxical motion akin to a flail chest. In the current era of improved diagnostic and therapeutic modalities for tuberculosis, such manifestations of the disease are still encountered due to delayed diagnosis and poor compliance with ATT.

### Financial support and sponsorship

Nil.

### Conflicts of interest

There are no conflicts of interest.

**Valliappan Muthu, Sahajal Dhooria,  
Ritesh Agarwal, Digambar Behera**

Department of Pulmonary Medicine, Postgraduate Institute of  
Medical Education and Research, Chandigarh,  
Punjab and Haryana, India  
E-mail: sahajal@gmail.com

**REFERENCES**

1. Macklin CC. Transport of air along sheaths of pulmonic blood vessels from alveoli to mediastinum: Clinical implications. *Arch Intern Med* 1939;64:913-26.
2. Sahn SA, Iseman MD. Tuberculous empyema. *Semin Respir Infect* 1999;14:82-7.
3. Ahmed SI, Gripaldo RE, Alao OA. Empyema necessitans in the setting of pneumonia and parapneumonic effusion. *Am J Med Sci* 2007;333:106-8.
4. Dixit R, George J. Subcutaneous emphysema in cavitary pulmonary tuberculosis without pneumothorax or pneumomediastinum. *Lung India* 2012;29:70-2.
5. Ete T, Mondal S, Sinha D, Nag A, Chakraborty A, Pal J, *et al.* Recurrent subcutaneous emphysema in a treated pulmonary tuberculosis patient: Is there any association? *Lung India* 2014;31:197-8.

Videos available on [www.lungindia.com](http://www.lungindia.com)

This is an open access article distributed under the terms of the Creative Commons Attribution-NonCommercial-ShareAlike 3.0 License, which allows others to remix, tweak, and build upon the work non-commercially, as long as the author is credited and the new creations are licensed under the identical terms.

**Access this article online****Quick Response Code:****Website:**[www.lungindia.com](http://www.lungindia.com)**DOI:**

10.4103/0970-2113.192858

**How to cite this article:** Muthu V, Dhooria S, Agarwal R, Behera D. Rare cause of spontaneous subcutaneous emphysema. *Lung India* 2016;33:688-9.