



## NOTE

Surgery

# The therapeutic efficacy of allyl isothiocyanate in cows with bovine digital dermatitis

Kanao CHIBA<sup>1) #</sup>, Tamako MIYAZAKI<sup>1) #</sup>, Yasushi SEKIYAMA<sup>2)</sup>, Masao MIYAZAKI<sup>3)</sup> and Keiji OKADA<sup>1) \*</sup>

<sup>1)</sup>Cooperative Department of Veterinary Medicine, Faculty of Agriculture, Iwate University, 3-18-8 Ueda, Morioka, Iwate 020-8550, Japan

<sup>2)</sup>Mitsubishi Kagaku Foods Corporation, 1-1-1 Marunouchi, Chiyoda, Tokyo 100-8251, Japan

<sup>3)</sup>Department of Biological Chemistry and Food Sciences, Faculty of Agriculture, Iwate University, 3-18-8 Ueda, Morioka, Iwate 020-8550, Japan

**ABSTRACT.** Bovine digital dermatitis (BDD) is the most prevalent infectious cause of lameness in cattle. Because *Treponema* infection is a major etiology of BDD, the most common treatment of BDD is an antibiotic. Nonetheless, dairy cows require a withdrawal period after antibiotic treatment before their milk can be marketed. To address the problem, in this study, we tested whether 3 nonantibiotic agents (used separately)—allyl isothiocyanate (AITC), sodium alginate, and calcium hydroxide—alleviate BDD lesions in dairy cows. The AITC treatment improved the BDD lesions, whereas the sodium alginate and calcium hydroxide treatments did not. Therapeutic efficacy of AITC was similar to that of lincomycin, a topical antibiotic prescribed for BDD. These results suggest that AITC is a promising nonantibiotic agent for BDD treatment in dairy cows.

**KEY WORDS:** allyl isothiocyanate, bovine digital dermatitis, non-antibiotic treatment, treponema

*J. Vet. Med. Sci.*

79(7): 1191–1195, 2017

doi: 10.1292/jvms.16-0270

Received: 25 May 2016

Accepted: 29 April 2017

Published online in J-STAGE:  
26 May 2017

Bovine digital dermatitis (BDD) is an important infectious foot disease of cattle; this illness affects the skin above the coronary band between the heel bulbs of the feet, resulting in lameness [5, 8, 10]. Because the prevalence and recurrence rates of BDD are high among cows [4], BDD not only decreases animal welfare but also causes serious economic losses for the dairy industry due to a reduced milk yield and low reproductive efficiency [1, 9]. A major cause of BDD is *Treponema* infection. Consequently, the most common treatment of BDD is an antibiotic, such as penicillin, erythromycin, oxytetracycline, or lincomycin [3, 4, 13, 18, 20, 23]. Nevertheless, after antibiotic treatment of BDD, cows must undergo a withdrawal period before their milk and meat products can be marketed; this situation causes further economic losses. Therefore, it is important to reduce the use of antibiotics in cows with BDD [12, 19, 31].

To overcome the above problems, some studies have examined nonantibiotic treatments in cows with BDD. One study revealed that treatment with salicylic acid improves BDD lesions [24]. Another study showed that a topical water-based gel containing activated copper and zinc is effective against the ulcerative stage of BDD [11]. A nonantibiotic paste containing metallic salts and organic acids, and a cream containing soluble copper, peroxide, and a cationic agent are also useful for the treatment of BDD lesions [12, 19]. These studies show that nonantibiotic agents are effective in the treatment of BDD.

In addition to these clinical trials, in the present study, we tested 3 nonantibiotics—allyl isothiocyanate (AITC), sodium alginate, and calcium hydroxide—for the treatment of cows with BDD. These chemicals have never been tested in cows with BDD. AITC is a natural extract from plants of family *Brassicaceae*, which includes wasabi (*Wasabia japonica*) and mustard (*Brassica juncea*). One study suggests that AITC affects bacterial cell membranes, inducing leakage of bacterial cellular metabolites [14]. The antibacterial activity of AITC has been demonstrated against *Salmonella* Montevideo [14], *Escherichia coli* O157:H7 [14, 17], *Helicobacter pylori* [25], *Campylobacter jejuni* [7, 22], and *Staphylococcus aureus* [6, 16] but not against *Treponema* species. Sodium alginate is soluble dietary fiber from seaweed. Solutions of sodium alginate form a gel that can adhere to the mucous membranes of animals; accordingly, it has been used as a mucosa-protective agent for the treatment of gastrointestinal ulcers and reflux esophagitis [28, 32]. Calcium hydroxide is applied widely to inactivate pathogenic microorganisms in manure and sewage biosolids. It increases pH to 12 in these materials, which effectively inhibits the activities of pathogens such as coliforms and

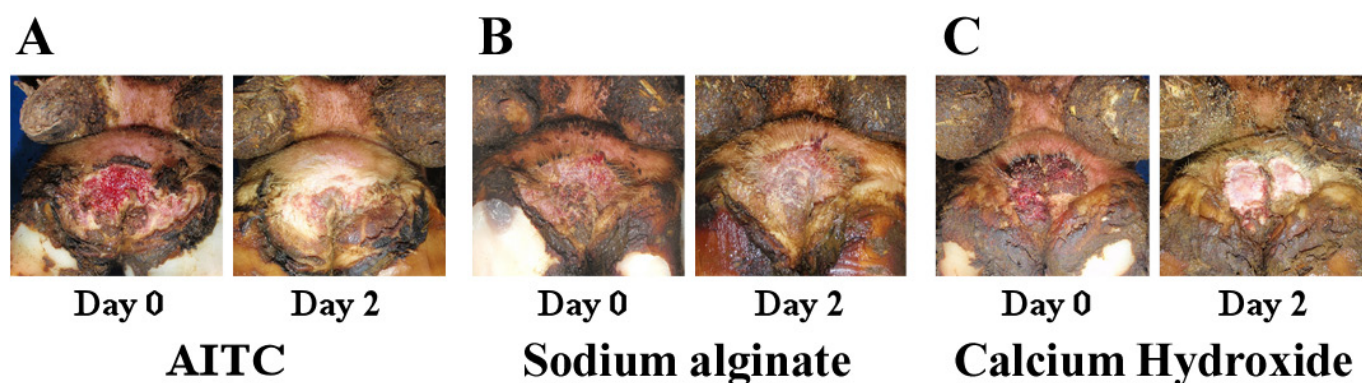
\*Correspondence to: Okada, K., Cooperative Department of Veterinary Medicine, Faculty of Agriculture, Iwate University, 3-18-8 Ueda, Morioka, Iwate 020-8550, Japan. e-mail: keiji@iwate-u.ac.jp

#These authors contributed equally to this work.

©2017 The Japanese Society of Veterinary Science



This is an open-access article distributed under the terms of the Creative Commons Attribution Non-Commercial No Derivatives (by-nc-nd) License. (CC-BY-NC-ND 4.0: <https://creativecommons.org/licenses/by-nc-nd/4.0/>)



**Fig. 1.** Representative images of BDD lesions before and 2 days after each treatment: AITC (A), sodium alginate (B), or calcium hydroxide (C). Severity of this BDD lesion changed from M2 (Day 0) to M4 (Day 2) after the AITC treatment, whereas severity of the lesions did not change from M2 (Days 0 and 2) after the sodium alginate or calcium hydroxide treatments.

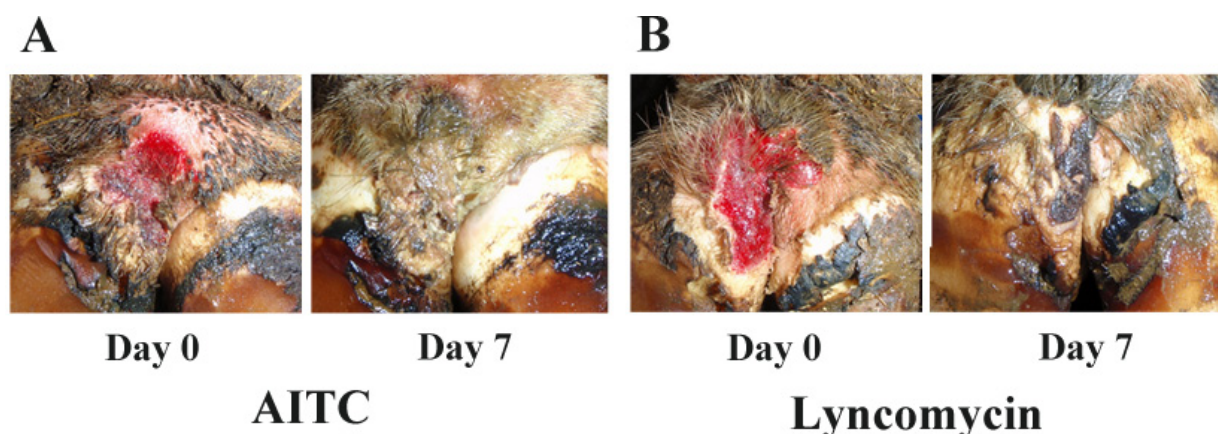
*Salmonella* in poultry manure [2] and *Salmonella typhimurium* in horse manure [21]. The aim of the present study was to identify potential antibacterial agents among AITC, sodium alginate, and calcium hydroxide for the treatment of BDD in dairy cows. Because we found that only AITC effectively improved ulcerative BDD lesions, we then compared the therapeutic efficacy between AITC and lincomycin, one of the antibiotics commonly used to treat cows with BDD.

This study was approved by the Animal Research Committee, and we followed the Animal Experiment guidelines of Iwate University. Thirteen Holstein Friesian lactating dairy cows with BDD were used in the first experiment. The 13 cows were housed in a free-stall system with 127 other cows on a private dairy farm in Hokkaido, Japan. The barn had mattress-padded stalls, and the cows were fed a total mixed ration. BDD was diagnosed by inspection of ulcerative lesions of the skin above the coronary band between the heel bulbs of the rear feet by the same veterinarian (K.O.). The cows were topically treated with 1 of the 3 nonantibiotic agents: AITC (Wasaouro Powder; 15.0% of AITC, 84.9% of starch, and 0.1% of tocopherol, Mitsubishi-Kagaku Foods, Tokyo, Japan), sodium alginate (Kanto Chemical, Tokyo, Japan), or calcium hydroxide (Wako Pure Chemical Industries, Osaka, Japan). AITC, sodium alginate, and calcium hydroxide were tested in 4, 4 and 5 cows with BDD, respectively. After feces were removed by washing with tap water, each agent (a 3-g aliquot) was placed directly on the skin affected by ulcerative lesions, covered with a 10 × 10 cm gauze pad, and wrapped with an elastic bandage (VetRap elastic bandage; 3M Products, St. Paul, MN, U.S.A.), which stayed on for 2 days. The ulcerative lesions of each cow were photographed, and severity was recorded by the categorizing method [10] immediately before and 2 days after treatment as follows: M0, normal skin; M1, a small ulcerative lesion (0–2 cm in diameter); M2, a large ulcerative lesion (>2 cm in diameter); M3, a healing stage with a scab-covered lesion; and M4, dyskeratosis or surface proliferation.

Twenty-six Holstein Friesian dairy cows (22 lactating and 4 nonlactating) with BDD were used in the next experiment. They were housed in a free-stall barn on a private dairy farm in Hokkaido, Japan that milks approximately 285 cows, and were fed a total mixed ration. BDD was diagnosed by inspection of ulcerative skin lesions above the coronary band of the rear feet by the same veterinarian (K.O.). The cows had no motor disorders, such as arthritis or peri-arthritis. The cows were randomly subdivided into 2 groups to receive topical 3 g of 15% AITC or 10 g of 40% lincomycin hydrochloride (Lincomycin Water Dispersion; Zoetis Japan, Tokyo, Japan). We tested AITC and lincomycin in 15 and 11 cows, respectively. The dose and duration were retrieved from another report [19]. After removal of feces via a wash of the lesions with tap water, the agents were placed directly on the lesion, covered with a 10 × 10 cm gauze pad, and wrapped with an elastic bandage, which stayed on for 7 days. The ulcerative lesions of each cow were photographed, and severity was recorded by the categorizing method [10] immediately before and 7 days after the treatment. BDD lesions were also examined in cows in which AITC or lincomycin was not effective 21 days after treatment. The therapeutic efficacy of AITC and lincomycin was compared on day 7 by Fisher's exact test. Differences with *P* values <0.05 were considered significant.

The cows' lameness was scored in 9 of the 15 cows treated with AITC and 8 of the 11 cows treated with lincomycin as described below. The cows were encouraged to walk 15 m on a relatively dry slatted floor in an alley (3 m wide) between 2 rows of free stalls and were examined by a person walking 3 m behind them. The same veterinarian (K.O.) evaluated the lameness, which was scored according to Sprecher's locomotion score [27] as follows: Score 1, the cow walked normally with her back flat and without any sign of lameness, uneven gait, or head bobbing; Score 2, the cow exhibited mild lameness with a slightly arched back while only walking; Score 3, the cow showed moderate lameness with the back arched during standing and during walking; Score 4, the cow was obviously lame, with the back arched at all times during both standing and walking, and the head bobbed during walking; and Score 5, the cow was severely lame and unable to bear its weight on the affected leg.

In the first experiment, we determined the possibility of healing BDD by administration of 1 of 3 nonantibiotics within a few days. Given that the cows tested were actual clinical cases on a private dairy farm, we compared the therapeutic efficacy among AITC, sodium alginate, and calcium hydroxide in treated cows only. Figure 1 shows representative images of BDD lesions immediately before and 2 days after each treatment. BDD lesion severity was categorized into M2 in all 13 cows before the



**Fig. 2.** Comparison of the BDD lesion improvement between AITC and lincomycin treatments. Representative images of BDD lesions before and 7 days after treatment with AITC (A) or lincomycin (B). Severity of the BDD lesions changed from M2 (Day 0) to M3 (Day 7) after the AITC and lincomycin treatments.

treatments. M2, where the large ulcerative lesion over 2 cm in diameter was observed, was the highest severity of BDD in this study. AITC alleviated the BDD lesions and reduced the severity from M2 to M4 (dyskeratosis or surface proliferation) in 2 cows and to M1 (small ulcerative lesion with diameter less than 2 cm) in 2 cows. The severity of BDD lesions was not alleviated from initial M2 in 4 cows treated with sodium alginate and in 5 cows treated with calcium hydroxide. Although we tested therapeutic efficacy only 2 days after administration as preliminary experiments, we hypothesized that AITC is an effective nonantibiotic agent for the treatment of BDD in cows.

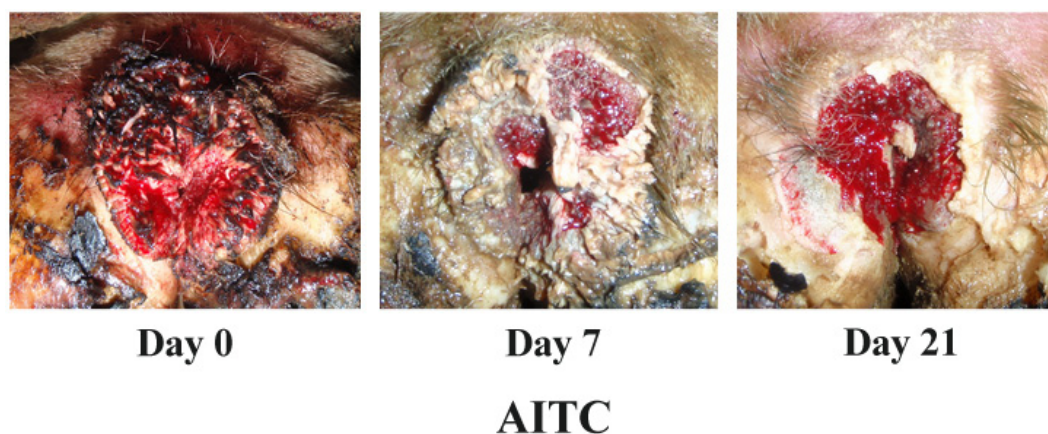
Because only AITC seemed to be effective against BDD lesions, the effects of the topical treatment with either AITC or lincomycin, which is an antibiotic frequently prescribed for BDD, were compared in cows with BDD of M2 severity (a large ulcerative lesion). Figure 2A shows representative images of the BDD lesions before and 7 days after the AITC treatment. In 14 of the 15 cows, AITC improved the BDD lesions until 7 days after the treatment by reducing the severity from M2 to M4 in 2 cows, to M3 in 11 cows, and to M1 in 1 cow. In contrast, the ulcerative lesion in 1 remaining cow showed no improvement. In 6 of 15 cows, BDD lesions were also evaluated 2 and 4 days after treatment. Severity of BDD lesions was decreased from M2 to M3 in all 6 cows 2 days after treatment. At 4 days after treatment, M3 severity was reduced to M4 in 2 of the 6 cows and to M1 in 1 of the 6 cows. BDD lesion severity did not change from 4 days to 7 days after treatment. Thus, we assumed that AITC treatment alleviated BDD in the 14 cows whose lesion improved after the treatment. On the other hand, BDD lesions were improved in 9 of the 11 cows until 7 days after lincomycin application (Fig. 2B). The BDD lesions had severity of M3 in 8 of the 9 cows and M1 in the other 1 cow 7 days after the lincomycin application. The remaining 2 of the 11 cows showed no improvement for 21 days after the lincomycin treatment. There was no significant difference ( $P=0.5558$ ) in the ratios of cows exhibiting improvement to cows showing no improvement between the AITC and lincomycin treatments.

The lameness score decreased from 3 to 2 in 7 of the 9 cows 7 days after the AITC treatment, whereas the score of 3 did not change in the remaining 2 cows. One of the 2 cows with a lameness score of 3 was the cow whose lesion was not improved after treatment. In comparison, 7 days after the lincomycin treatment, the lameness score decreased from 3 to 2 in 3 of the 8 cows, was still 3 in 1 cow, and remained unchanged at 2 in the other 4 cows. The 2 cows whose lesion was not improved after treatment showed no improvement in the lameness score from 3 or 2. There was no significant difference ( $P=0.1534$ ) in the ratios of cows showing an improvement of lameness scores to cows exhibiting no improvement of the score between the AITC and lincomycin treatments.

A major finding of this study is that AITC improved BDD lesions, and there was no significant difference in the therapeutic efficacy between AITC and lincomycin toward the BDD lesions or lameness. The result indicates that AITC can be used for BDD treatment, just as lincomycin can. Therefore, we propose that AITC is a promising nonantibiotic agent for treatment of BDD in dairy cows. We are currently conducting a large-scale observational study of cows with BDD to determine the therapeutic ratio of AITC toward BDD in dairy cows. Such a study will be necessary to validate AITC as a drug for clinical cases of BDD in veterinary medicine.

On the other hand, 1 and 2 cows did not respond to the treatment with AITC and lincomycin, respectively. We found that BDD lesions of these cows were not improved 21 days after each treatment (Fig. 3). This finding suggests that AITC and lincomycin were not effective in these cows. Although further research is needed to address the question why there are cows in which AITC and lincomycin do not work, it may be necessary to give such cows many different drugs including both antibiotics and nonantibiotics such as AITC at the same time and to do proper foot trimming with the treatment.

We are now elucidating how AITC improves BDD lesions in cows. One possibility is that AITC may affect the *Treponema* infection in BDD lesions directly. There are reports that AITC inhibits the biosynthesis of bacterial macromolecules in the exponential growth phase [14], and its amphiphilic chemical structure is involved in antibacterial activities toward gram-negative



**Fig. 3.** Representative images of BDD lesions until 21 days after the AITC treatment. Severity of the BDD lesion did not change from M2.

bacteria, such as *Salmonella* Montevideo and *E. coli* O157:H7 [14, 17]. Therefore, AITC may reduce the viability of *Treponema* species in BDD lesions, and then sterilize them. Further assays such as analyses of therapeutic efficacy of AITC, recurrence rates of BDD after more than 7 days, and identification, isolation, and quantification of representative bacteria from BDD lesions would be necessary to test the above possibility.

In veterinary medicine, we anticipate that the use of AITC will involve fewer restrictions than the use of antibiotics. A recent study indicates that automatic washing of hooves with water and soap for 2 months effectively decreased the prevalence of BDD in a commercial dairy herd [30]. We believe that water and soap in combination with AITC may be more effective for the treatment and prevention of BDD in cows. Another possibility is to use AITC as a disinfectant on dairy farms. Recurrence of BDD is a major problem in cows with BDD. It is thought that continuous *Treponema* infection in chronic BDD lesions and interdigital dermatitis cause BDD recurrence [4]. Contaminated bedding and floors of a free-stall barn are also etiological factors of recurrent BDD [3, 4, 23]. Disinfectants such as calcium hydroxide and chlorine, which are popular disinfectants among dairy farms, may be insufficient for removing *Treponema* species from heavily contaminated solutions, such as slurry. Formaldehyde and copper sulfate are used in foot baths and successfully control BDD [8, 26]. Nonetheless, there are concerns regarding these chemicals in terms of environmental contamination and their adverse effects on human health [15, 29]. Considering also that AITC is used as a food preservative and has strong antibacterial activity in the vapor phase [14], we propose that sterilization of dairy farms using AITC may prevent *Treponema* infection in cows.

**ACKNOWLEDGMENTS.** We thank Mr. Hiroyuki Manabe for sample preparation and Dr. Shigeru Sato from Iwate University for an invaluable discussion.

## REFERENCES

1. Argáez-Rodríguez, F. J., Hird, D. W., Hernández de Anda, J., Read, D. H. and Rodríguez-Lainz, A. 1997. Papillomatous digital dermatitis on a commercial dairy farm in Mexicali, Mexico: incidence and effect on reproduction and milk production. *Prev. Vet. Med.* **32**: 275–286. [Medline] [CrossRef]
2. Bean, C. L., Hansen, J. J., Margolin, A. B., Balkin, H., Batzer, G. and Widmer, G. 2007. Class B alkaline stabilization to achieve pathogen inactivation. *Int. J. Environ. Res. Public Health* **4**: 53–60. [Medline] [CrossRef]
3. Berry, S. L., Read, D. H., Walker, R. L. and Famula, T. R. 2010. Clinical, histologic, and bacteriologic findings in dairy cows with digital dermatitis (footwarts) one month after topical treatment with lincomycin hydrochloride or oxytetracycline hydrochloride. *J. Am. Vet. Med. Assoc.* **237**: 555–560. [Medline] [CrossRef]
4. Berry, S. L., Read, D. H., Famula, T. R., Mongini, A. and Döpfer, D. 2012. Long-term observations on the dynamics of bovine digital dermatitis lesions on a California dairy after topical treatment with lincomycin HCl. *Vet. J.* **193**: 654–658. [Medline] [CrossRef]
5. Cheli, R. and Mortellaro, C. 1974. La dermatite digitale del bovino, ed.
6. Dias, C., Aires, A. and Saavedra, M. J. 2014. Antimicrobial activity of isothiocyanates from cruciferous plants against methicillin-resistant *Staphylococcus aureus* (MRSA). *Int. J. Mol. Sci.* **15**: 19552–19561. [Medline] [CrossRef]
7. Dufour, V., Alazzam, B., Ermel, G., Thepaut, M., Rossero, A., Tresse, O. and Baysse, C. 2012. Antimicrobial activities of isothiocyanates against *Campylobacter jejuni* isolates. *Front. Cell. Infect. Microbiol.* **2**: 53. [Medline] [CrossRef]
8. Evans, N. J., Murray, R. D. and Carter, S. D. 2016. Bovine digital dermatitis: Current concepts from laboratory to farm. *Vet. J.* **211**: 3–13. [Medline] [CrossRef]
9. Gomez, A., Cook, N. B., Socha, M. T. and Döpfer, D. 2015. First-lactation performance in cows affected by digital dermatitis during the rearing period. *J. Dairy Sci.* **98**: 4487–4498. [Medline] [CrossRef]
10. Holzhauer, M., Bartels, C. J., Döpfer, D. and van Schaik, G. 2008. Clinical course of digital dermatitis lesions in an endemically infected herd without preventive herd strategies. *Vet. J.* **177**: 222–230. [Medline] [CrossRef]

11. Holzhauer, M., Bartels, C. J., van Barneveld, M., Vulders, C. and Lam, T. 2011. Curative effect of topical treatment of digital dermatitis with a gel containing activated copper and zinc chelate. *Vet. Rec.* **169**: 555. [[Medline](#)] [[CrossRef](#)]
12. Kofler, J., Pospichal, M. and Hofmann-Parisot, M. 2004. Efficacy of the non-antibiotic paste Protexin Hoof-Care for topical treatment of digital dermatitis in dairy cows. *J. Vet. Med. A Physiol. Pathol. Clin. Med.* **51**: 447–452. [[Medline](#)] [[CrossRef](#)]
13. Laven, R. A. and Logue, D. N. 2006. Treatment strategies for digital dermatitis for the UK. *Vet. J.* **171**: 79–88. [[Medline](#)] [[CrossRef](#)]
14. Lin, C. M., Preston, J. F. 3rd. and Wei, C. I. 2000. Antibacterial mechanism of allyl isothiocyanate. *J. Food Prot.* **63**: 727–734. [[Medline](#)] [[CrossRef](#)]
15. Logue, D. N., Gibert, T., Parkin, T., Thomson, S. and Taylor, D. J. 2012. A field evaluation of a footbathing solution for the control of digital dermatitis in cattle. *Vet. J.* **193**: 664–668. [[Medline](#)] [[CrossRef](#)]
16. Lu, Z., Dockery, C. R., Crosby, M., Chavarria, K., Patterson, B. and Giedd, M. 2016. Antibacterial Activities of Wasabi against Escherichia coli O157:H7 and Staphylococcus aureus. *Front. Microbiol.* **7**: 1403. [[Medline](#)] [[CrossRef](#)]
17. Luciano, F. B. and Holley, R. A. 2009. Enzymatic inhibition by allyl isothiocyanate and factors affecting its antimicrobial action against Escherichia coli O157:H7. *Int. J. Food Microbiol.* **131**: 240–245. [[Medline](#)] [[CrossRef](#)]
18. Manske, T., Hultgren, J. and Bergsten, C. 2002. Topical treatment of digital dermatitis associated with severe heel-horn erosion in a Swedish dairy herd. *Prev. Vet. Med.* **53**: 215–231. [[Medline](#)] [[CrossRef](#)]
19. Moore, D. A., Berry, S. L., Truscott, M. L. and Koziy, V. 2001. Efficacy of a nonantimicrobial cream administered topically for treatment of digital dermatitis in dairy cattle. *J. Am. Vet. Med. Assoc.* **219**: 1435–1438. [[Medline](#)] [[CrossRef](#)]
20. Nishikawa, A. and Taguchi, K. 2008. Healing of digital dermatitis after a single treatment with topical oxytetracycline in 89 dairy cows. *Vet. Rec.* **163**: 574–576. [[Medline](#)] [[CrossRef](#)]
21. Nyberg, K. A., Vinnerås, B., Lewerin, S. S., Kjellberg, E. and Albin, A. 2011. Treatment with Ca(OH)<sub>2</sub> for inactivation of Salmonella Typhimurium and Enterococcus faecalis in soil contaminated with infected horse manure. *J. Appl. Microbiol.* **110**: 1515–1523. [[Medline](#)] [[CrossRef](#)]
22. Olaimat, A. N., Fang, Y. and Holley, R. A. 2014. Inhibition of Campylobacter jejuni on fresh chicken breasts by κ-carrageenan/chitosan-based coatings containing allyl isothiocyanate or deodorized oriental mustard extract. *Int. J. Food Microbiol.* **187**: 77–82. [[Medline](#)] [[CrossRef](#)]
23. Read, D. H. and Walker, R. L. 1998. Papillomatous digital dermatitis (footwarts) in California dairy cattle: clinical and gross pathologic findings. *J. Vet. Diagn. Invest.* **10**: 67–76. [[Medline](#)] [[CrossRef](#)]
24. Schultz, N. and Capion, N. 2013. Efficacy of salicylic acid in the treatment of digital dermatitis in dairy cattle. *Vet. J.* **198**: 518–523. [[Medline](#)] [[CrossRef](#)]
25. Shin, I. S., Masuda, H. and Naohide, K. 2004. Bactericidal activity of wasabi (Wasabia japonica) against Helicobacter pylori. *Int. J. Food Microbiol.* **94**: 255–261. [[Medline](#)] [[CrossRef](#)]
26. Solano, L., Barkema, H. W., Pickel, C. and Orsel, K. 2017. Effectiveness of a standardized footbath protocol for prevention of digital dermatitis. *J. Dairy Sci.* **100**: 1295–1307. [[Medline](#)] [[CrossRef](#)]
27. Sprecher, D. J., Hostetler, D. E. and Kaneene, J. B. 1997. A lameness scoring system that uses posture and gait to predict dairy cattle reproductive performance. *Theriogenology* **47**: 1179–1187. [[Medline](#)] [[CrossRef](#)]
28. Tang, M., Dettmar, P. and Batchelor, H. 2005. Bioadhesive oesophageal bandages: protection against acid and pepsin injury. *Int. J. Pharm.* **292**: 169–177. [[Medline](#)] [[CrossRef](#)]
29. Teixeira, A. G., Machado, V. S., Caixeta, L. S., Pereira, R. V. and Bicalho, R. C. 2010. Efficacy of formalin, copper sulfate, and a commercial footbath product in the control of digital dermatitis. *J. Dairy Sci.* **93**: 3628–3634. [[Medline](#)] [[CrossRef](#)]
30. Thomsen, P. T., Ersbøll, A. K. and Sørensen, J. T. 2012. Short communication: Automatic washing of hooves can help control digital dermatitis in dairy cows. *J. Dairy Sci.* **95**: 7195–7199. [[Medline](#)] [[CrossRef](#)]
31. Wallmann, J., Schröter, K., Wieler, L. H. and Kroker, R. 2003. National antibiotic resistance monitoring in veterinary pathogens from sick food-producing animals: the German programme and results from the 2001 pilot study. *Int. J. Antimicrob. Agents* **22**: 420–428. [[Medline](#)] [[CrossRef](#)]
32. Yamamoto, A., Itoh, T., Nasu, R., Kajiwara, E. and Nishida, R. 2013. Sodium alginate inhibits methotrexate-induced gastrointestinal mucositis in rats. *Biol. Pharm. Bull.* **36**: 1528–1534. [[Medline](#)] [[CrossRef](#)]