

Near-complete Humerus Reconstruction in the Pediatric Patient with Vascularized Free Fibula Transfer

John Shuck, MD*
Benjamin C. Wood, MD*
Christopher Zarella, MD*
Albert K. Oh, MD*
Robert M. Henshaw, MD†
Gary F. Rogers, MD, JD, MBA,
MPH*

Summary: Vascularized free fibula transfer remains the gold standard for reconstruction of large segmental diaphyseal defects of the upper extremity. In the pediatric patient, before skeletal maturity, free fibula transfer with the fibular head provides an active physis for growth and an articular interface for glenohumeral joint reconstruction. Clinical and cadaveric studies have demonstrated that the vascular supply to the fibular head originates, in most cases, from the anterior tibial system. However, anatomical variation exists, and we report a case in which a vascularized fibula autograft including the physis was transferred on the peroneal artery in a 5-year-old patient with Ewing's sarcoma. At 15-month follow-up, the patient has functional range of motion of the shoulder. (*Plast Reconstr Surg Glob Open* 2016;4:e1143; doi: 10.1097/GOX.0000000000001143; Published online 27 December 2016.)

Vascularized free fibula transfer remains the gold standard for reconstruction of large segmental diaphyseal defects of the upper extremity. Previous series have demonstrated excellent rates of bony union and satisfactory functional outcomes.^{1,2} Although defects involving the humeral head may be reconstructed with implant-based total shoulder arthroplasty in adults, the pediatric patient presents a unique challenge. Before skeletal maturity, a free fibula graft including the fibular head provides an active physis for growth and an articular interface for glenohumeral joint reconstruction. We report a case in which a vascularized fibula autograft including the physis was transferred for reconstruction of the humerus in a pediatric patient after resection of a Ewing's sarcoma.

A 5-year-old, right-hand-dominant boy presented with biopsy-confirmed Ewing's sarcoma extending from the proximal to distal metadiaphysis of the left humerus (Fig. 1). Induction neoadjuvant chemotherapy resulted in near-complete resolution of the soft-tissue extension of the intrahumeral mass and limb salvage was pursued.

Resection resulted in a near-complete humeral defect, with only the distal 6 cm including the distal metaphysis and humeroulnar joint remaining (Fig. 2). During the

resection, the insertions of the deltoid, subscapularis, supraspinatus, infraspinatus, teres minor, pectoralis major, biceps brachii, and brachialis muscles were preserved. Immediate reconstruction was performed with a free fibula graft including the fibular head. Intraoperatively, the fibular head was found to be perfused via a branch from the proximal peroneal artery with an absence of any branching vessels from the anterior tibial system to the proximal physis encountered under 4.5× loupe magnification. A small cuff of capsule was harvested with the fibular head including a segment of the lateral collateral ligament for repair to the rotator cuff. The graft was then transferred to the brachium and inserted intracapsularly after the remaining portion of the long head of the biceps tendon was released from the supraglenoid tubercle, with preservation of the surrounding labrum. The fibular head articular surface was then aligned with the glenoid and the rotator cuff was placed over the top of the fibular head, and in sequential order, the subscapularis, supraspinatus, infraspinatus, and teres minor were tenomyodesed to the remaining capsule and portions of the lateral collateral ligament and capsule on the fibular head. This was then purse-string sutured

From the *Division of Plastic and Reconstructive Surgery, Children's National Medical Center, Washington, D.C.; and †Department of Orthopedic Surgery, Medstar Cancer Institute, Washington, D.C.

Received for publication March 27, 2016; accepted October 5, 2016.

Copyright © 2016 The Authors. Published by Wolters Kluwer Health, Inc. on behalf of The American Society of Plastic Surgeons. All rights reserved. This is an open-access article distributed under the terms of the Creative Commons Attribution-Non Commercial-No Derivatives License 4.0 (CCBY-NC-ND), where it is permissible to download and share the work provided it is properly cited. The work cannot be changed in any way or used commercially without permission from the journal.

DOI: 10.1097/GOX.0000000000001143

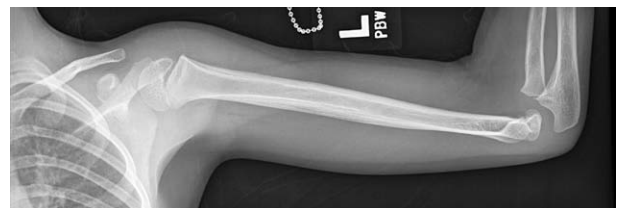

Fig. 1. Ewing's sarcoma extending from the proximal to distal metadiaphysis of the left humerus in a 5-year-old male patient.

Disclosure: The authors have no financial interest to declare in relation to the content of this article. The Article Processing Charge was paid for by the authors.

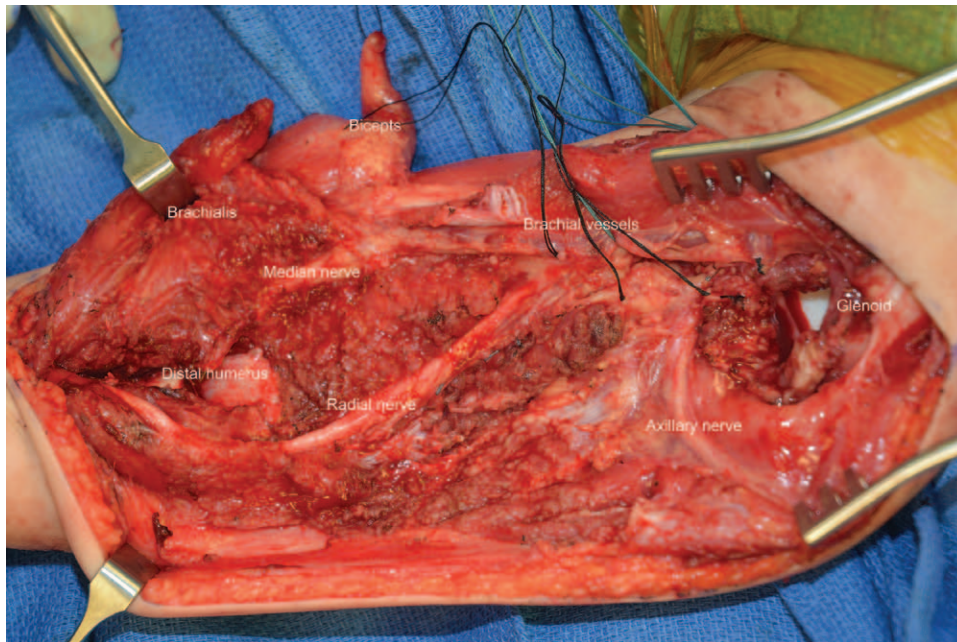


Fig. 2. Defect after resection with only the distal 6 cm including the distal metaphysis and humeroulnar joint remaining.

around the neck of the fibula, providing excellent stability of the reconstructed shoulder joint (Fig. 3).

Bony fixation was achieved with a mini frag 2.0-mm 4-hole locking plate (Synthes; West Chester, Pa.). Three 2.0 mm locking screws and one 2.0-mm compression screw were used for osteosynthesis. The peroneal artery and vein were then anastomosed in an end-to-end fashion to the radial collateral artery and accompanying vein. Finally, advancement of the deltoid to the brachialis and tenomyodesis to the graft was performed. The long head of the biceps was then tenomyodesed to the remaining deltoid and short head of the biceps. The latissimus dorsi and pectoralis insertions were then advanced and tenomyodesed to the deltoid. Closed suction drains were placed, and the proximal and distal extents of the incision were closed in layers. To avoid undue pressure given the significant muscle swelling, the central aspect was left open for staged closure with the placement of a negative pressure dressing. Overnight, a decrease in the implantable Doppler venous signal prompted re-exploration. The pectoralis-to-deltoid tenomyodesis was found to be compressing the pedicle and was released. This resulted in return of excellent perfusion to the flap. All incisions were healed by 4 weeks with early radiographic bony union. At 9 months, the patient presented with a proximal diaphyseal fracture. Conservative treatment with immobilization achieved rapid fracture healing and callus formation (Fig. 4). Currently, at 15-month follow-up, the patient has functional range of motion of the shoulder including 35-degree active abduction and 50-degree forward flexion and can bring his hand to his mouth and behind his head. By orthopedic evaluation, he has no knee instability, common/deep peroneal nerve sequelae, or walking impairment.

Innocenti et al initially reported a series of 9 patients under the age of 10 years who underwent free vascularized

growth-plate transfer after bony tumor resection of the proximal humeral metaphysis. In that series, the follow-up ranged from 3 months to 4 years with an average of over 1 cm of growth per year.^{3,4} In the majority of patients, the physis and up to the proximal two thirds of the diaphysis are supplied by branches from the anterior tibial artery. Innocenti et al therefore prefer harvest on the anterior tibial artery in most cases; however, they reported significant donor-site morbidity. Isolation of the anterior tibial vessels off the deep peroneal nerve is challenging given the presence of motor branches to the anterior compartment. In their series, they reported temporary deep peroneal nerve palsy in two thirds of cases with permanent deficits in 3 patients. Early reports by Pho et al demonstrated longitudinal growth and graft hypertrophy with vascularized fibula epiphyses when transferred on the peroneal artery.⁵ Subsequent anatomical and vascular studies demonstrate primary perfusion of the physis from the descending genicular artery or recurrent anterior tibial branches.^{6,7,8} However, controversy remains, and indeed Innocenti et al reported successful transfer on the peroneal artery in 16% of their patients in their initial

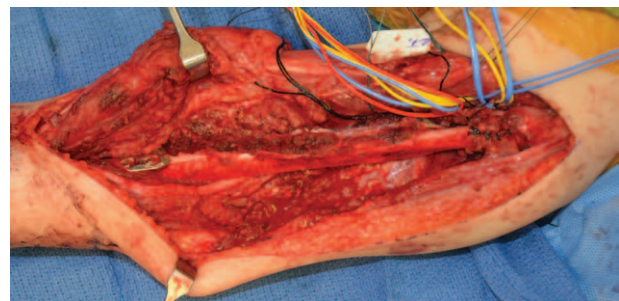


Fig. 3. Graft after inset with tenomyodesis of neoglenohumeral joint.

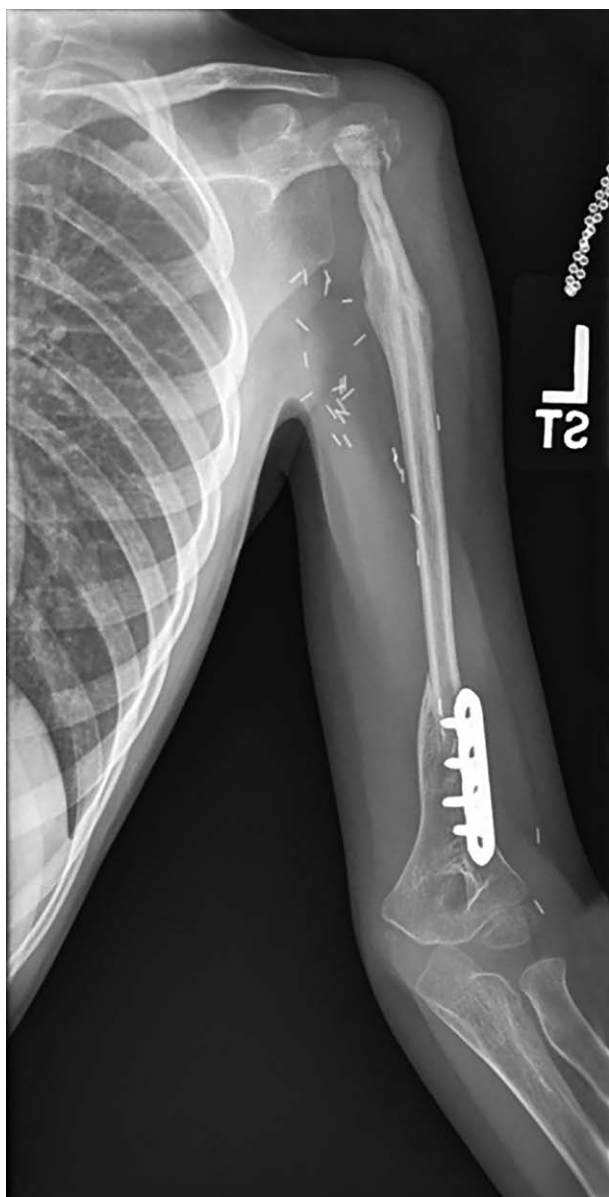


Fig. 4. Radiograph at 9 months demonstrating rapid bony healing and callus formation after fracture.

series. We feel confident that the proximal third and physis are perfused on the peroneal in this case given the lack of any anterior tibial branches intraoperatively and rapid healing of proximal diaphyseal fracture postoperatively. Despite high fracture rate and donor-site morbidity, the literature demonstrates encouraging early results in pediatric patients requiring humeral reconstruction with an average growth rate of 0.92 cm per year.^{4,9,10} Long-term functional outcomes of the neoglenofibular joint remain unknown and further long-term follow-up is warranted.

Benjamin C. Wood, MD

Plastic and Reconstructive Surgery
Children's National Medical Center
111 Michigan Avenue, NW
Washington, DC 20010
E-mail: bwood@childrensnational.org

REFERENCES

1. Gebert C, Hillmann A, Schwappach A, et al. Free vascularized fibular grafting for reconstruction after tumor resection in the upper extremity. *J Surg Oncol.* 2006;94:114–127.
2. Heitmann C, Erdmann D, Levin LS. Treatment of segmental defects of the humerus with an osteoseptocutaneous fibular transplant. *J Bone Joint Surg Am.* 2002;84-A:2216–2223.
3. Innocenti M, Ceruso M, Manfrini M, et al. Free vascularized growth-plate transfer after bone tumor resection in children. *J Reconstr Microsurg.* 1998;14:137–143.
4. Innocenti M, Delcroix L, Romano GF. Epiphyseal transplant: harvesting technique of the proximal fibula based on the anterior tibial artery. *Microsurgery* 2005;25:284–292.
5. Pho RW, Patterson MH, Kour AK, et al. Free vascularised epiphyseal transplantation in upper extremity reconstruction. *J Hand Surg Br.* 1988;13:440–447.
6. Innocenti M, Delcroix L, Romano GF, et al. Vascularized epiphyseal transplant. *Orthop Clin North Am.* 2007;38:95–101, vii.
7. Trueta J. The role of the vessels in osteogenesis. *J Bone Joint Surg [Br]* 1963;45:402–404.
8. Bonnel F, Lesire M, Gomis R, et al. Arterial vascularization of the fibula microsurgical transplant techniques. *Anat Clin.* 1981;3:13–23.
9. Onoda S, Sakuraba M, Asano T, et al. Use of vascularized free fibular head grafts for upper limb oncologic reconstruction. *Plast Reconstr Surg.* 2011;127:1244–1253.
10. Erdmann D, Garcia RM, Blueschke G, et al. Vascularized fibula-based physis transfer for pediatric proximal humerus reconstruction. *Plast Reconstr Surg.* 2013;132:281e–287e.